



Case Report:

Breast metastasis from small cell lung carcinoma

Shi-ping LUH^{†1}, Chih KUO², Thomas Chang-yao TSAO³

¹Department of Surgery, Chia-Yi Christian Hospital and Chung-Shan Medical University and Hospital, Taichung 402, Taiwan, China)

²Department of Pathology, Chung-Shan Medical University and Hospital, Taichung 402, Taiwan, China)

³Department of Medicine, Chung-Shan Medical University and Hospital, Taichung 402, Taiwan, China)

[†]E-mail: luh572001@yahoo.com.tw

Received Nov. 18, 2007; revision accepted Dec. 3, 2007

Abstract: Breast metastases from extramammary neoplasms are very rare. We presented a 66 year-old female with metastasis of small cell lung carcinoma to the breast. She presented with consolidation over the left upper lobe of her lung undetermined after endobronchial or video-assisted thoracoscopic surgery (VATS) biopsy, and this was treated effectively after antibiotic therapy at initial stage. The left breast lumps were noted 4 months later, and she underwent a modified radical mastectomy under the impression of primary breast carcinoma. However, the subsequent chest imaging revealed re-growing mass over the left mediastinum and hilum, and cells with the same morphological and staining features were found from specimens of transbronchial brushing and biopsy. An accurate diagnosis to distinguish a primary breast carcinoma from metastatic one is very important because the therapeutic planning and the outcome between them are different.

Key words: Small cell carcinoma, Breast metastasis, Lung
 doi:10.1631/jzus.B072258

Document code: A

CLC number: R73

INTRODUCTION

Breast metastases from extramammary primary neoplasms are very rare (Ribeiro-Silva *et al.*, 2006; Chaignaud *et al.*, 1994; Oksüzöglü *et al.*, 2003; Nielsen *et al.*, 1981; Cangiarella *et al.*, 1998), accounting for about 2% of all breast malignancies (Sadikot *et al.*, 1997; Silverman *et al.*, 1987; Hajdu and Urban, 1972). Reported primary tumors metastasizing to the breast include melanoma (Cangiarella *et al.*, 1998), hematopoietic malignancies (Shukla *et al.*, 2005), and carcinomas from the lung, genitourinary or gastrointestinal tract (Shukla *et al.*, 2005; Ramar *et al.*, 2003; Masmoudi *et al.*, 2003; Santeufemia *et al.*, 2006; Yeh *et al.*, 2004; Mihai *et al.*, 2005). However, metastasized breast malignancies from small cell carcinomas of the lung were very rarely reported before (Shukla *et al.*, 2005; Inoue *et al.*, 2006; Jakovljević *et al.*, 2003). Here we report a female patient with breast metastasis from small cell lung carcinoma, of which the diagnosis was estab-

lished from the metastatic breast lesions. Her pulmonary lesion could not be diagnosed initially after series of diagnostic procedures but was subsequently confirmed by repeated endobronchial brushing cytology and biopsy.

CASE REPORT

This 66 year-old female had complained of cough with intermittent fever (up to 38.5 °C) for 20 d. Chest roentgenogram revealed opacified shadow over the left upper lung field (Fig.1a). Chest computed tomography showed that this lesion was composed of pulmonary parenchymal consolidation and a suspected mass lesion over the central hilar area (Fig.1b). Bronchoscopic examination showed narrowing in the bronchial orifice of the left upper lobe. However, repeated sputum cytological examinations, and transbronchial and trans-thoracoscopic biopsies revealed no evidence of malignancy. On admission, she un-

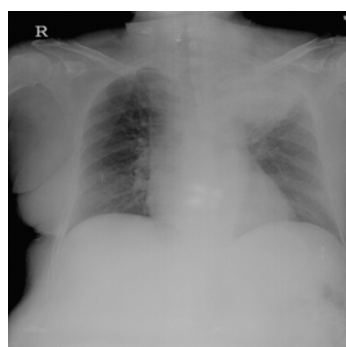
derwent intravenous piperacillin-tazobactam treatment because *Pseudomonas aeruginosa* was isolated from her sputum specimens. These symptoms and signs improved after the above treatment; chest X-ray revealed much smaller shadow over the left upper lung field (Fig.2a). Unfortunately, this lung lesion re-grew 4 months later (Fig.2b) and two lumps over her left breast appeared 3 months later.

She came to our clinic 4 months after the first treatment, and the two breast masses were 3 cm and 0.8 cm in diameter over the 4 o'clock direction, 4.5 cm from the nipple and 12 o'clock direction, 4 cm from the nipple sites of the left breast, respectively (Fig.3). These two masses were elastically firm on palpation. Breast ultrasound revealed a well margined but heterogeneous mass in the internal density. Under the suspicion of breast carcinoma, which was proved pathologically by specimen from the excised mass, she underwent left mastectomy and axillary lymph node dissection at the second admission.

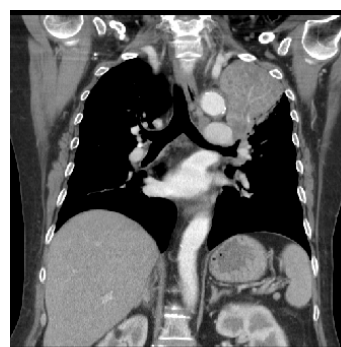The specimen contained two elastically firm, well margined masses, 3.1 cm×2.5 cm×2.2 cm and

0.8 cm×0.7 cm×0.5 cm in size, over the 4 o'clock direction, 4.5 cm from the nipple and 12 o'clock direction, 4 cm from the nipple sites of the left breast, respectively. Microscopically, the sections of tumor lesions revealed small hyperchromatic cells with high nucleus-to-cytoplasm (N/C) ratios. Tumor necrosis, emboli and vascular invasion were noted frequently. Non-neoplastic breast tissue showed unremarkable change. The nipple and skin are free of tumor involvement. Three out of 13 lymph nodes isolated from axillary levels 1 and 2 lymph nodes were infiltrated by tumor cells. Perinodal extension was noted. The tumor cells were negatively stained for mucin, c-erbB-2 oncoprotein, estrogen and progesterone receptor; but positively stained for synaptophysin, chromogranin and CD56 (Figs.4 and 5).

The patient underwent bronchoscopy for the second time. The endobronchial biopsy and brushing revealed similar cells and staining patterns as seen in the breast tumors (Fig.6). Small cell carcinomas over the lung and extrapulmonary site (breast) were diagnosed, but their relationship (double primary or

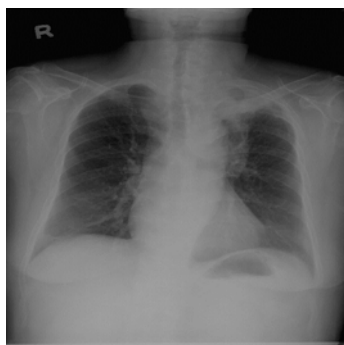


(a)

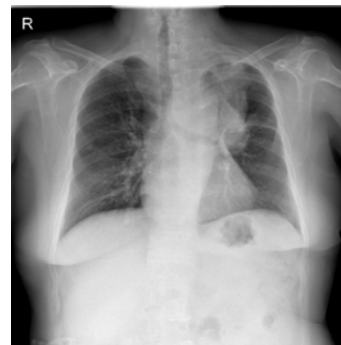


(b)

Fig.1 (a) Chest roentgenogram revealed opacified shadow over the left upper lung field; (b) Chest computed tomography showed that this lesion was composed of pulmonary parenchymal consolidation and a suspected mass lesion over the central hilar area

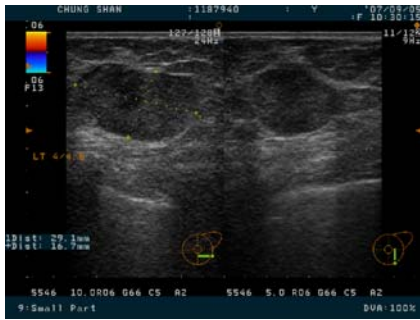

(a)

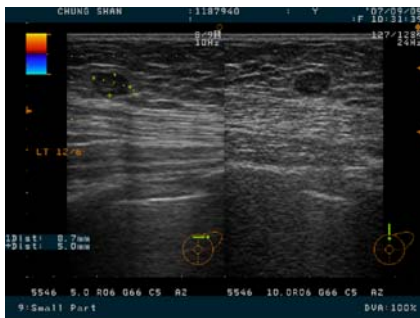

(b)

Fig.2 (a) Compared with Fig.1a, the shadow regressed 1 month after treatment with antibiotics; (b) The mass shadow re-grew 4 months after treatment



(a)



(b)

Fig.3 Two breast masses, with 3 cm (a) and 0.8 cm (b) in diameter over the 4 o'clock direction, 4.5 cm from the nipple and 12 o'clock direction, 4 cm from the nipple sites of the left breast being noted on breast ultrasound imaging

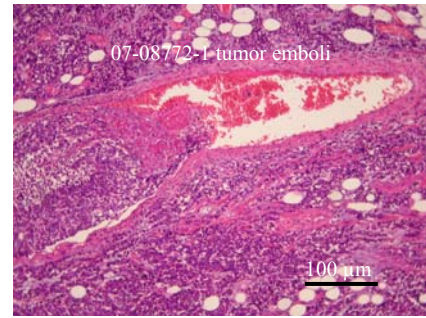
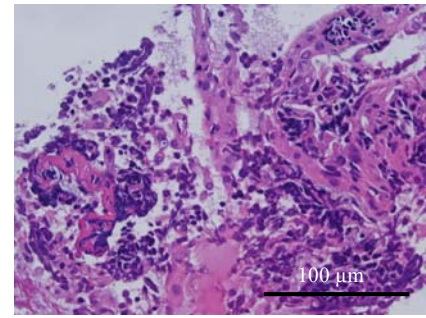
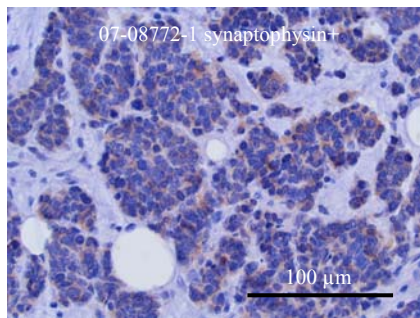


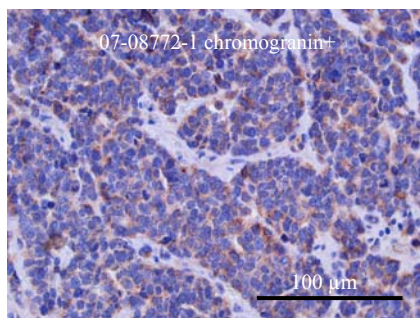
Fig.4 Microscopically, the sections of breast tumor lesions reveal small hyperchromatic cells with high nucleus-to-cytoplasm (N/C) ratio. Tumor necrosis, emboli and vascular invasion are noted frequently (H & E stain)



(a)

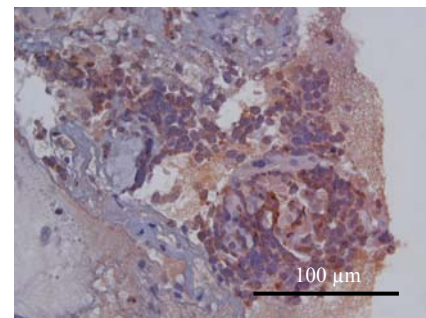


(a)



(b)

Fig.5 The breast tumor cells are positively stained for synaptophysin and chromogranin



(b)

Fig.6 Microscopically, the lung mass is proved as small cell carcinoma with similar morphological and staining patterns as those of the breast mass. (a) H & E stain; (b) Focal positive for synaptophysin staining

metastatic, or the primary tumor) cannot be confirmed pathologically. However, after reviewing clinical data of this patient, primary small cell lung carcinoma with breast metastases should be the most likely diagnosis. Thus she underwent subsequent cisplatin-based chemotherapy. One episode of severe hyponatremia (serum sodium ion level <120 mol/L) was noted during the postoperative period. Syndrome of inap-

appropriate anti-diuretic hormone (SIADH) was suspected after urine electrolyte and specific gravity were measured. This condition was improved after chemotherapy, sodium supplement and restriction of water intake.

DISCUSSION

Small cell carcinoma most commonly occurs in the lung, but can also in the extrapulmonary sites such as gastrointestinal or genitourinary tract, gynecological systems, the head and neck, and the breast (Haider *et al.*, 2006; Galanis *et al.*, 1997; Kim *et al.*, 2004; Adegbola *et al.*, 2005; Shin *et al.*, 2000). Primary extrapulmonary small cell carcinomas are rare, and their behaviors are somewhat comparable to the small cells of the lung. The survivals of extrapulmonary small cell carcinomas are related to the extent and the primary site of diseases, and usually aggressive with poor prognosis (Haider *et al.*, 2006; Galanis *et al.*, 1997). Smoking is regarded as an important risk factor not only for pulmonary but also for over 50% of extrapulmonary small cell carcinomas. Primary breast small cell carcinoma is extremely rare, and absence of other non-mammary primary sites as well as the presence of in situ component will be required before establishing this diagnosis (Sridhar *et al.*, 2004). Breast small cell carcinoma, being classified as tumors with endocrine differentiation, is the rarest, but the highest, grade of malignancy with prominent vascular invasion and nodal metastasis (Ajisaka *et al.*, 2003).

Metastatic lesions of the breast only account for 0.4% to 6.6% of all breast malignant tumors, and this difference is due to the inclusion or exclusion of hematopoietic malignancies. Besides leukemia or lymphoma, breast metastasis has been reported to be most commonly from melanoma, rhabdomyosarcoma, and the lung (Shukla *et al.*, 2005; Ramar *et al.*, 2003; Masmoudi *et al.*, 2003; Santeufemia *et al.*, 2006; Yeh *et al.*, 2004; Mihai *et al.*, 2005; Inoue *et al.*, 2006; Jakovljević *et al.*, 2003). Differentiation between the primary and metastatic breast carcinoma is important in determining treatment plans. Metastatic mammary carcinoma is usually well-defined, and in the absence of characters of primary breast carcinoma such as distortion of adjacent architecture or microcalcifica-

tion (Kelly *et al.*, 1988; Vizcaino *et al.*, 2001). Multiplicity of the masses and absence of hormone receptors favor the diagnosis of metastatic lesions.

In our presented case, since common features, such as cytopathological pictures and staining patterns, were shared by the tumors in these two organs, and characters of metastatic tumors as described above were noted at the breast, thus small cell lung carcinoma with left breast metastasis was the most reasonable diagnosis. Furthermore, episode of SIADH, which might be a type of paraneoplastic syndrome in small cell carcinoma, occurred after the removal of breast mass. This syndrome was alleviated and the size of the left hilar mass was reduced after chemotherapy, proving the existence of pulmonary malignancy, although the pathology only revealed "suspicious" lesion after repeated biopsy or brushing cytology. However, the route of metastases from the lung was still unclear because axillary lymph nodes metastases were noted, which rarely occurred in hematogenous metastasis. Fine-needle aspiration, core needle biopsy, as well as surgical biopsy can make pre-mastectomy diagnosis for patients with breast lumps. In our presented case, since the pathological diagnosis from frozen section is carcinoma without more specific histological subtype, and the possible primary site (lung) was suspected after confirming the diagnosis of the breast lumps, modified radical mastectomy would be a reasonable choice of procedure under this condition. If the diagnosis of lung lesion is definite before detecting the breast lump, avoiding or limited operation could be considered as the choice of management.

Small cell carcinomas, either from pulmonary or extrapulmonary site, are aggressive in their behaviors and require combined modalities of treatments including chemotherapy. Neoadjuvant chemotherapy followed by resection has been considered for selective cases without distant metastasis (Jakovljević *et al.*, 2003; Haider *et al.*, 2006). In our presented case, chemotherapy protocol follows the guideline of pulmonary small cell carcinoma. It is still unknown why the pulmonary lesion reduced in size after antibiotic treatment 3 months before its re-appearance. While the improvement of obstructive pneumonia could partially explain this phenomenon, we still think this was an unusual case according to our previous experiences.

In summary, a patient of small cell carcinoma manifested as pulmonary and breast mass lesions could not be confirmed by endobronchial or transthoracic biopsies but was diagnosed subsequently from breast lesions. The initial response of the lung lesion to antibiotic treatment confused us in making the decision of treatment strategies. It is important to differentiate between primary and metastatic breast malignancies according to their clinical and image features, and to consider the possibility of metastasis or other rare primary malignancies if a breast lump was noted.

References

- Adegbola, T., Connolly, C.E., Mortimer, G., 2005. Small cell neuroendocrine carcinoma of the breast: a report of three cases and review of the literature. *J. Clin. Pathol.*, **58**(7): 775-778. [doi:10.1136/jcp.2004.020792]
- Ajisaka, H., Maeda, K., Miwa, A., Yamamoto, K., 2003. Breast cancer with endocrine differentiation: report of two cases showing different histologic patterns. *Surg. Today*, **33**(12):909-912. [doi:10.1007/s00595-003-2612-5]
- Cangiarella, J., Symmans, W.F., Cohen, J.M., Goldenberg, A., Shapiro, R.L., Waisman, J., 1998. Malignant melanoma metastatic to the breast: a report of seven cases diagnosed by fine-needle aspiration cytology. *Cancer*, **84**(3): 160-162. [doi:10.1002/(SICI)1097-0142(19980625)84:3<160::AID-CNCR7>3.0.CO;2-S]
- Chaignaud, B., Hall, T.J., Powers, C., Subramony, C., Scott-Conner, C.E., 1994. Diagnosis and natural history of extramammary tumors metastatic to the breast. *J. Am. Coll. Surg.*, **179**(1):49-53.
- Galanis, E., Frytak, S., Lloyd, R.V., 1997. Extrapulmonary small cell carcinoma. *Cancer*, **79**(9):1729-1736. [doi:10.1002/(SICI)1097-0142(19970501)79:9<1729::AID-CNCR14>3.0.CO;2-#]
- Haider, K., Shahid, R.K., Finch, D., Sami, A., Ahmad, I., Yadav, S., Alvi, R., Popkin, D., Ahmed, S., 2006. Extrapulmonary small cell cancer: a Canadian province's experience. *Cancer*, **107**(9):2262-2269. [doi:10.1002/cncr.22235]
- Hajdu, S.I., Urban, J.A., 1972. Cancers metastatic to the breast. *Cancer*, **29**(6):1691-1696. [doi:10.1002/1097-0142(197206)29:6<1691::AID-CNCR2820290637>3.0.CO;2-4]
- Inoue, T., Tanaka, E., Sakuramoto, M., Minakuchi, M., Maeda, Y., Maniwa, K., Terada, K., Goto, S., Takeda, T., Okamoto, M., et al., 2006. A case of small cell lung cancer with an initial symptom of breast metastasis. *Nihon Kokyoku Gakkai Zasshi*, **44**(1):39-42.
- Jakovljević, B., Stevanović, O., Bacić, G., 2003. Metastases to the breast from small-cell lung cancer: MR findings. A case report. *Acta Radiol.*, **44**(5):485-488. [doi:10.1034/j.1600-0455.2003.00114.x]
- Kelly, C., Henderson, D., Corris, P., 1988. Breast lumps. Rare presentation of oat cell carcinoma of lung. *J. Clin. Pathol.*, **41**(2):171-172. [doi:10.1136/jcp.41.2.171]
- Kim, J.H., Lee, S.H., Park, J., Kim, H.Y., Lee, S.I., Nam, E.M., Park, J.O., Kim, K., Jung, C.W., Im, Y.H., et al., 2004. Extrapulmonary small-cell carcinoma: a single-institution experience. *Jpn. J. Clin. Oncol.*, **34**(5):250-254. [doi:10.1093/jjco/hyh052]
- Masmoudi, A., Mathieu, M.C., Soria, J.C., 2003. Breast metastasis from lung adenocarcinoma: a case report. *Anti-cancer Res.*, **23**(2C):1825-1826.
- Mihai, R., Christie-Brown, J., Bristol, J., 2005. Breast metastases from colorectal carcinoma. *Breast*, **14**(1):80-81. [doi:10.1016/j.breast.2004.08.009]
- Nielsen, M., Andersen, J.A., Henriksen, F.W., Kristensen, P.B., Lorentzen, M., Ravn, V., Schiødt, T., Thorborg, J.V., Ornvold, K., 1981. Metastases to the breast from extramammary carcinomas. *Acta Pathol. Microbiol. Scand. A*, **89**(4):251-256.
- Oksüzöglü, B., Abali, H., Güler, N., Baltali, E., Ozişik, Y., 2003. Metastasis to the breast from nonmammary solid neoplasms: a report of five cases. *Med. Oncol.*, **20**(3): 295-300. [doi:10.1385/MO:20:3:295]
- Ramar, K., Pervez, H., Potti, A., Mehdi, S., 2003. Breast metastasis from non-small-cell lung carcinoma. *Med. Oncol.*, **20**(2):181-184. [doi:10.1385/MO:20:2:181]
- Ribeiro-Silva, A., Mendes, C.F., Costa, I.S., de Moura, H.B., Tiezzi, D.G., Andrade, J.M., 2006. Metastases to the breast from extramammary malignancies: a clinicopathologic study of 12 cases. *Pol. J. Pathol.*, **57**(3):161-165.
- Sadikot, R.T., Renwick, D.S., DaCosta, P., Chalmers, A.G., Pearson, S.B., 1997. Breast metastasis from non-small cell lung cancer. *South. Med. J.*, **90**(10):1063-1064. [doi:10.1097/00007611-199710000-00021]
- Santeufemia, D.A., Piredda, G., Fadda, G.M., Cossu Rocca, P., Costantino, S., Sanna, G., Sarobba, M.G., Pinna, M.A., Putzu, C., Farris, A., 2006. Successful outcome after combined chemotherapeutic and surgical management in a case of esophageal cancer with breast and brain relapse. *World J. Gastroenterol.*, **12**(34):5565-5568.
- Shin, S.J., DeLellis, R.A., Ying, L., Rosen, P.P., 2000. Small cell carcinoma of the breast: a clinicopathologic and immunohistochemical study of nine patients. *Am. J. Surg. Pathol.*, **24**(9):1231-1238. [doi:10.1097/00000478-200009000-00006]
- Shukla, R., Pooja, B., Radhika, S., Nijhawan, R., Rajwanshi, A., 2005. Fine-needle aspiration cytology of extramammary neoplasms metastatic to the breast. *Diagn. Cytopathol.*, **32**(4):193-197. [doi:10.1002/dc.20198]
- Silverman, J.F., Feldman, P.S., Covell, J.L., Frable, W.J., 1987. Fine needle aspiration cytology of neoplasms metastatic to the breast. *Acta Cytol.*, **31**(3):291-300.
- Sridhar, P., Matey, P., Aluwihare, N., 2004. Primary carcinoma of breast with small-cell differentiation. *Breast*, **13**(2):149-151. [doi:10.1016/j.breast.2003.07.001]
- Vizcaíno, I., Torregrosa, A., Higuera, V., Morote, V., Cremades, A., Torres, V., Olmos, S., Molins, C., 2001. Metastasis to the breast from extramammary malignancies. A report of four cases and a review of literature. *Eur. Radiol.*, **11**(9):1659-1665. [doi:10.1007/s003300000807]
- Yeh, C.N., Lin, C.H., Chen, M.F., 2004. Clinical and ultrasonographic characteristics of breast metastases from extramammary malignancies. *Am. Surg.*, **70**(4):287-290.