



Epidemiological and clinical characteristics of 266 cases of intracerebral hemorrhage in Hangzhou, China

Yun-zhen HU¹, Jian-wen WANG², Ben-yan LUO^{†‡2}

(¹Department of Pharmacy, the First Affiliated Hospital, School of Medicine, Zhejiang University, Hangzhou 310003, China)

(²Department of Neurology, the First Affiliated Hospital, School of Medicine, Zhejiang University, Hangzhou 310003, China)

[†]E-mail: benyanluo@163.com

Received Nov. 28, 2012; Revision accepted Apr. 2, 2013; Crosschecked May 22, 2013

Abstract: Ethnicity and socioeconomic factors can influence disease susceptibility, clinical presentation, and outcome. We investigated the clinical characteristics (age, sex, seasonal variation, lesion site, symptoms, complications, prognosis, and sequelae) and risk factors for intracerebral hemorrhage (ICH) in 266 cases treated at our hospital in Hangzhou City, China, from January 2011 to December 2011. Risk of ICH increased dramatically with age; only 4.3% of cases were <30 years old, while 44.4% were >60 years of age. Men outnumbered women by 2:1 (67.3% vs. 32.7%). Single hemorrhage was most often located in the cerebral lobes (37.2% of cases), basal ganglia (34.2%), thalamus (8.3%), cerebellum (6.8%), ventricle (1.5%), and brainstem (1.1%), while 10.9% of cases exhibited hemorrhages at multiple sites. Hypertension was also a major risk factor for ICH, as 47% of all patients were hypertensive and the percentage increased with age. In hypertensive patients, the most common hemorrhage site was the basal ganglia and ICH was often associated with thrombopenia. In patients with leukemia (all forms), most hemorrhages were lobar. Warfarin- and encephalic operation-associated ICHs were all lobar. Headache was the major symptom of occipital, temporal, and frontal lobe hemorrhage. Dizziness, nausea, and vomiting were the major symptoms of cerebellum hemorrhage. Limb dysfunction was the major symptom of thalamic and basal ganglia hemorrhage. Disturbed level of consciousness was the major symptom in multisite, ventricular, parietal lobe, and brainstem hemorrhage. Hyper-spasmia occurred most often in lobar hemorrhage and blurred vision in occipital lobe hemorrhage. Hospital mortality was 24.4% ($n=65$) with a mean delay from presentation to death of (10.5 ± 18.5) d. The majority of fatalities were cerebral hernia cases (58.5%) and these patients also had the shortest time to death [(2.9 ± 3.5) d]. Mortality was 100% in brainstem ICH and hemorrhagic conversion of cerebral infarct. Thrombopenia-associated ICH also had a high mortality rate (81.0%), while patients with cerebrovascular malformations and cerebral aneurysms demonstrated a much better prognosis (46.2% recovery).

Key words: Intracerebral hemorrhage (ICH), Epidemiology, Clinical characteristics, Risk factor, Outcome

doi:10.1631/jzus.B1200332

Document code: A

CLC number: R743.34

1 Introduction

Intracerebral hemorrhage (ICH) is a devastating disease with high rates of mortality and morbidity (Crandall *et al.*, 2011). Approximately 10% to 23% of strokes are caused by the rupture of cerebral blood

vessels (Dennis *et al.*, 1993; Lavados *et al.*, 2005) and the overall ICH incidence worldwide is 24.6 per 100000 person-years (van Asch *et al.*, 2010). A recent review of ischemic stroke and ICH reported a higher stroke incidence in low-income countries compared to higher-income countries (Feigin *et al.*, 2009). Aside from socioeconomic factors, ethnicity has also been reported to contribute to ICH risk (Broderick *et al.*, 2007). van Asch *et al.* (2010) reported a two-fold

[‡] Corresponding author

higher rate of ICH in Asians compared to other ethnic groups. Numerous population-based studies have assessed the epidemiology of ICH in wealthy counties, but there are comparatively little data on ICH risk factors, symptoms, and clinical outcomes among different ethnic groups in lower-income nations. This study was designed to investigate the epidemiological and clinical characteristics of ICH in Hangzhou City, China. We recorded the distribution of ICH across age groups, differences between men and women, seasonal distribution, and hemorrhage location. In addition, we examined the relationships among likely causes, age, hemorrhage location, risk factors, symptoms, complications, prognosis, mortality, and time to death after the event.

2 Materials and methods

2.1 Study population and design

This study includes all cases with ICH treated by the First Affiliated Hospital, School of Medicine, Zhejiang University, China from January 2011 to December 2011. Identification of ICH cases was performed by a specialized research staff using the electronic medical record (EMR) system and involved a continuous broad search of all patients admitted to the emergency, neurological, neurosurgery, and other relevant hospital wards for neurological symptoms that could indicate ICH. Patients initially hospitalized for other reasons were also included in the case-finding procedure if additional symptoms suggested ICH. Patients admitted for other diseases, but exhibiting ICH sequelae, suggesting previous hemorrhage events, were excluded. Supported by a senior neurologist, all possible stroke cases were confirmed by review of each patient's records. In all cases included in this sample, ICH was defined as a sudden, focal, neurological deficit with intraparenchymal hemorrhage seen on cranial computed tomography (CT) or magnetic resonance imaging (MRI) scans. Angiography was performed in select cases where hemorrhage location, age, or clinical presentation was suggestive of a vascular malformation.

2.2 Data analysis

The SPSS 12.0 statistical package was used for all calculations. Categorical data were analyzed by

the Pearson's chi-squared test (χ^2), while numerical means were compared by Student's *t*-test (two-tailed). A *P* value <0.05 was considered statistically significant.

3 Results

3.1 Distribution of ICH cases by sex and age groups

A total of 266 cases of ICH were identified (0.35% of all in-patients). Their mean age was (57.9±15.2) years (range, 14 to 97 years) of which 5.3% were <30 years old, 13.5% were 30 to 45 years old, 36.8% were 46 to 60 years old, and 44.4% were >60 years of age. Only 32.7% were women, but mean age was not significantly different between male and female patients ((59.2±15.0) years vs. (57.0±15.4) years, *P*=0.312, *t*-test).

3.2 Seasonal distribution

Of all ICH attacks included, 24.1% occurred in spring, 22.2% in summer, 24.4% in autumn, and 29.3% in winter. There was a tendency for a higher incidence in winter compared to summer (*P*=0.06, χ^2 test).

3.3 Hemorrhage location

The majority of single hemorrhages were found in deep (subcortical) sites, including the basal ganglia (34.2%), thalamus (8.3%), cerebellum (6.8%), ventricles (1.5%), and brainstem (1.1%). A significant minority (10.9%) exhibited hemorrhages in multiple subcortical sites, or at one subcortical site and one cortical site. Single hemorrhages were also observed in temporal (9.8% of all ICH cases), occipital (5.6%), frontal (7.1%), and parietal (3.0%) lobes, and 11.7% of all ICH patients exhibited hemorrhages in multiple lobes. In total, 39.5% of cases were unilateral left, 47.4% were unilateral right, and 13.1% were bilateral.

3.4 Age-related differences in ICH location

The most common ICH sites were the cerebral lobes (50.0%) and cerebellum (28.6%) in the youngest patient group (<30 years), the cerebral lobes (61.1%) and basal ganglia (22.2%) in the 30–45 years age group, cerebral lobes (28.6%) and basal ganglia (42.8%) in the 46–60 years age group, and cerebral

lobes (36.4%) and basal ganglia (33.9%) in the group >60 years of age (Fig. 1). There was a significant difference in ICH location distribution across age groups ($P=0.012$, χ^2 test).

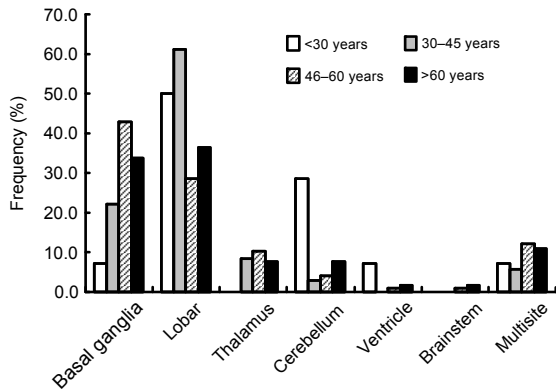


Fig. 1 Distribution of ICH locations in different age groups
Different age groups showed different frequencies of ICH locations, including basal ganglia, lobar, thalamus, and so on

3.5 Likely causes of ICH

A significant fraction of ICH patients had hypertension (47.0%). Other possible or very likely causes included leukemia, head trauma in traffic accidents, cerebrovascular malformations, and cerebral aneurysms (Fig. 2).

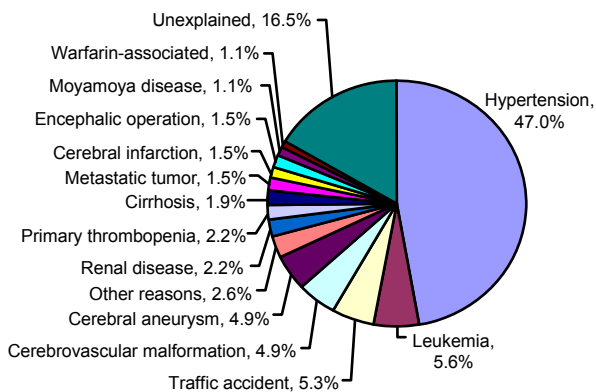


Fig. 2 Distribution of likely causes of ICH in the Hangzhou patient sample (n=266 cases)

3.6 Age-related differences in the likely causes of ICH

The most probably causes of ICH in patients of <30 years of age were thrombopenia (including cases

associated with leukemia) (35.7%) and cerebrovascular malformations (21.4%). In all older groups, a history of hypertension but no other identifiable proximal event was found in many cases. Thus, hypertension appeared to be the most likely cause in these groups, accounting for as much as 30.6% of all ICH cases in the 30–45 years age group, 53.1% of patients of 46–60 years old, and 52.5% of the patients of >60 years of age (Fig. 3). In these older groups, however, “unexplained” was the second most populous group, accounting for 22.2% of patients of 30–45 years old, 11.2% of patients of 46–60 years old, and 18.6% of those >60 years of age. There was a statistically significant difference in the distribution of most likely causes between the different age groups ($P<0.001$, χ^2 test).

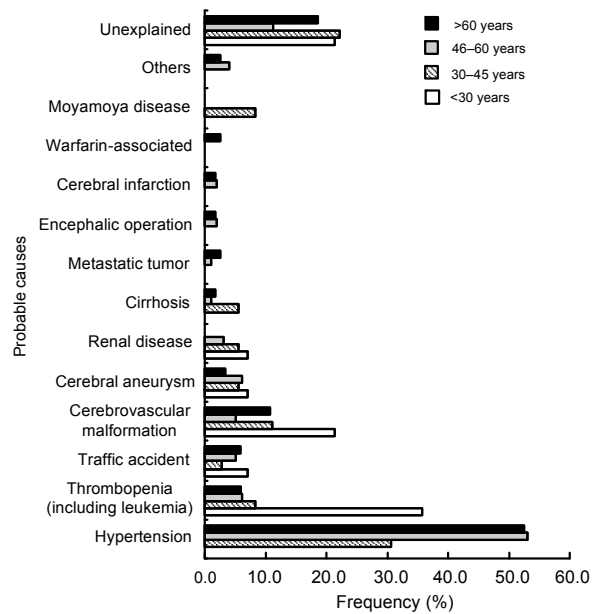


Fig. 3 Distribution of most likely causes of ICH in different age groups

Different age groups displayed different frequencies of probable causes, including hypertension, thrombopenia, cerebrovascular malformation, and so on

3.7 Relationship between ICH location and likely cause

Hypertension is a ubiquitous risk factor for ICH across study populations. In this patient sample, different brain structures appeared differentially sensitive to the effects of hypertension, as high blood

pressure was seen in 79.1% of basal ganglia, 68.2% of thalamic, and 41.7% of multisite ICH cases, but in only a minority of cerebellar (22.2%) and lobar (20.2%) ICH cases. Cerebrovascular malformation was the major cause of ventricle hemorrhage (50.0%). Hypertension (33.3%), renal disease (33.3%), and cerebral infarction (33.3%) were the three most common possible factors leading to brainstem hemorrhage (Fig. 4).

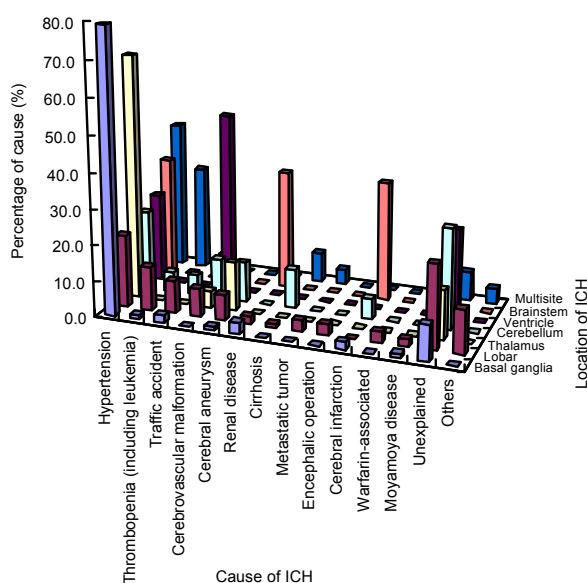


Fig. 4 Distribution of probable causes of ICH at each site. Different ICH sites (divided into basal ganglia, lobar, thalamus, and so on) showed different percentages of probable causes (including hypertension, thrombopenia, cerebrovascular malformation, and so on)

Warfarin-associated ICH cases and those during intracranial operations all occurred in the cerebral lobes (100%). The cerebral lobes were also the most common sites for ICHs associated with metastatic tumor (75.0% of tumor cases had hemorrhage located in one or more lobes), traffic accidents (69.2%), moyamoya disease (66.7%), cerebrovascular malformation (61.5%), thrombopenia (including leukemia, 57.1%), and cerebral aneurysms (53.8%). In contrast, the majority of ICHs in patients with hypertension, renal disease, or cerebral infarction were located in the basal ganglia (59.2%, 50.0%, or 50.0%, respectively), while ICHs associated with cirrhosis were mainly located in the cerebellum (40.0%) or at multiple sites (40.0%) (Fig. 5).

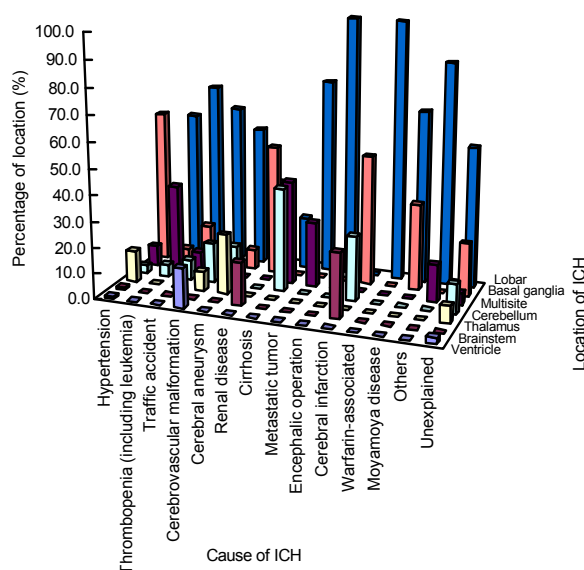


Fig. 5 Distribution of ICH sites for each probable cause. Different probable causes of ICH (including hypertension, thrombopenia, cerebrovascular malformation, and so on) displayed different percentages of ICH sites (divided into basal ganglia, lobar, cerebellum, and so on)

3.8 Symptom of ICH

The most common symptoms of ICH in this study group were disturbed level of consciousness (44.0% of all cases), limb dysfunction (43.2%), headache (39.1%), nausea (37.6%), vomiting (36.5%), dizziness (28.2%), dysarthria (15.8%), blurred vision (4.5%), hyperspasmia (3.4%), and deflection of the angle of the mouth (3.0%). All 266 cases had one or multiple symptoms.

3.9 Relationship between ICH location and major symptoms

Headache was the major symptom of occipital (66.7%), temporal (61.5%), and frontal lobe hemorrhage (47.4%). Dizziness, nausea, and vomiting were the major symptoms in most cases of cerebellum hemorrhage (55.6%). Limb dysfunction was observed in most cases of thalamic (72.7%) and basal ganglia hemorrhage (68.1%). Disturbed level of consciousness was observed most often in multisite hemorrhage (79.2%), ventricular hemorrhage (75.0%), parietal lobe hemorrhage (75.0%), brainstem hemorrhage (66.7%), and multiple lobe hemorrhage (51.6%). Blurred vision mainly appeared in occipital lobe hemorrhage and hyperspasmia appeared in lobar hemorrhage (Fig. 6).

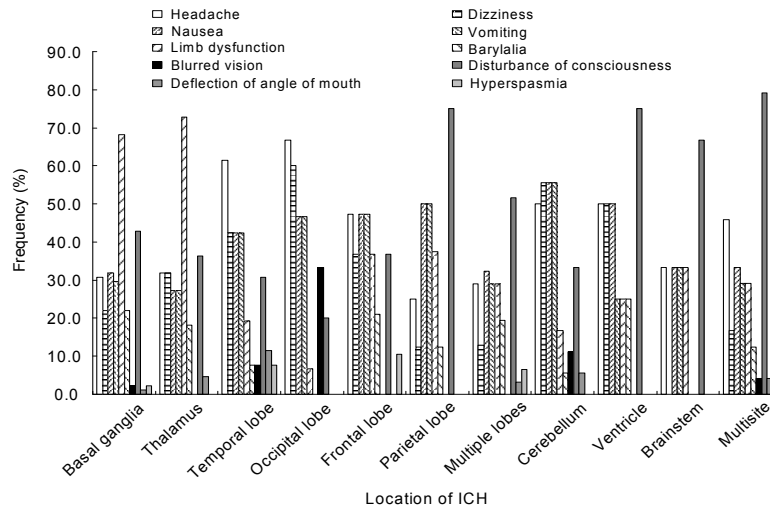


Fig. 6 Symptom variability with ICH location

Different locations of ICH (including basal ganglia, temporal lobe, occipital lobe, and so on) showed different frequencies of symptoms (divided into headache, dizziness, nausea, and so on). All cases had one or multiple symptoms

3.10 Prognosis of ICH

The overall hospital mortality was 24.4% ($n=65$) and mean time from admission to death was (10.5 ± 18.5) d. Twenty of the 65 deaths took place in the first 24 h, and 16 patients died in the first 48 to 72 h due to neurological complications. Of the total sample, 21.8% recovered fully (with no lasting sequelae), while 50.4% improved after therapy but with lasting sequelae. Only 3.4% of surviving patients showed no significant improvement after rehabilitation. The prognosis was related to the likely cause of ICH. The whole hospital mortality of ICH associated with cerebral infarction and thrombopenia (including leukemia) was 100.0% and 81.0%, respectively, while ICH caused by cerebrovascular malformations or cerebral aneurysms showed much better prognosis than all other causal subgroups, with 46.2% of patients achieving full recovery (Fig. 7).

In addition, the prognosis was also related to the location of ICH. The highest hospital mortality was observed in patients with ICH of the brainstem (100.0%), followed by patients with ICHs in multiple sites (50.0%). Most cases of ICH in the basal ganglia and parietal lobe improved after therapy (62.6% and 62.5%, respectively). Patients with ICHs in the ventricles or temporal lobe exhibited the highest rates of full recovery (50.0% or 46.2%) (Fig. 8).

3.11 Complications and mortality

There were 101 cases with severe complications, including pulmonary infection (21.8%), cerebral hernia (4.9%), epilepsy (4.5%), respiratory failure (3.0%), multiple organ failure (1.9%), intracranial infection (1.9%), and rebleeding (1.1%). As previously mentioned, 65 cases died due to the complications. In addition, different complications have different time of death (Table 1). Cerebral hernia was the most deadly complication as indicated by death rate and time from presentation to death.

Table 1 Relationship between ICH complications and time to death

Complication	Case number	Time to death (d)
Cerebral hernia	38 (58.5%)	2.9±3.5
Pulmonary infection	11 (16.9%)	29.2±30.9
Respiratory failure	9 (13.8%)	21.6±25.2
Multiple organ failure	3 (4.6%)	23.7±12.6
Rebleeding	2 (3.1%)	7.5±3.5
Intracranial infection	2 (3.1%)	39.0±45.2

Total case number is 65. Case number is expressed as number (percentage), and time to death as mean±SD

3.12 Sequelae of ICH

There were 129 cases with persistent sequelae following therapy, including unilateral weakness (21.8% of cases with sequelae), hemiplegia (16.2%), dizziness (2.6%), headache (2.2%), blurred vision (2.2%), coma (2.2%), and epilepsy (1.1%).

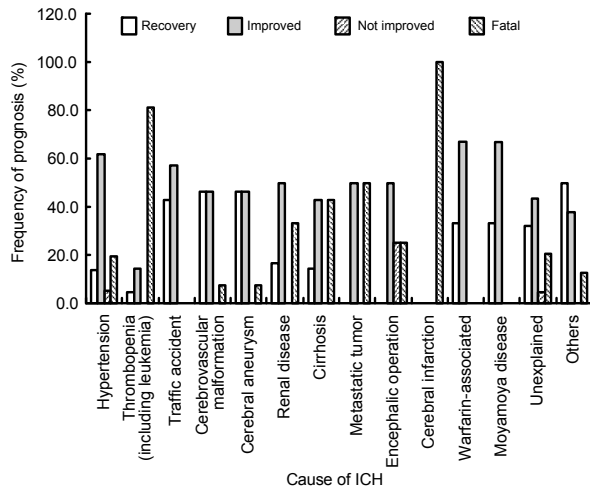


Fig. 7 Relationship between probable cause of ICH and prognosis

Different probable causes of ICH (including hypertension, thrombopenia, cerebrovascular malformation, and so on) have different frequencies of prognosis (divided into recovery, improved, not improved, and fatal)

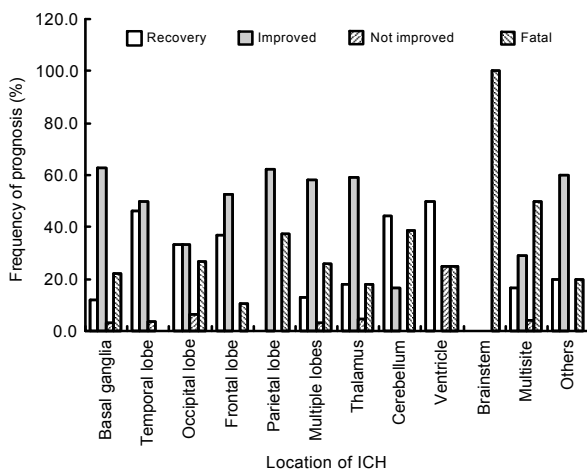


Fig. 8 Relationship between prognosis and ICH location

Different locations of ICH (including basal ganglia, temporal lobe, occipital lobe, and so on) have different frequencies of prognosis (divided into recovery, improved, not improved, and fatal)

4 Discussion

Globally, stroke is one of the top three causes of death and disability. Only 10% to 15% of first-ever strokes are ICHs (Broderick *et al.*, 2007), but compared to other types of stroke, disability and death rates are significantly higher (Feigin *et al.*, 2003). Jiang *et al.* (2006) found a higher prevalence of

hemorrhagic stroke in Chinese than in European populations. More than 85% of ICHs occur as a primary event related to rupture of small penetrating arteries and arterioles that have been damaged by chronic arterial hypertension (Thrift *et al.*, 1998). Hypertension is the single most important modifiable risk factor for ICH (Juvela, 1996). Regardless of race, age, or gender, about 75% of ICH patients have pre-existing hypertension (Broderick *et al.*, 1993). Retrospective studies have shown that high blood pressure confers a two- to six-fold increase in the risk of ICH (Thrift *et al.*, 1996). Cerebral amyloid angiopathy (CAA), a condition that increases with age, is the second most common risk factor for ICH, particularly lobar ICH (Aguilar and Brott, 2011). However, CAA cannot be accurately diagnosed with noninvasive methods, so we present no statistics on the incidence of CCA in this study. Secondary ICH may be caused by coagulopathy, trauma, arteriovenous malformation, intracranial aneurysm, hemorrhagic conversion of cerebral infarct, and dural arteriovenous fistula among others (Qureshi *et al.*, 2001).

Of the roughly 75000 in-patients treated in our hospital during the study intake period, 266 had ICH (0.35%). Age was the greatest risk factor for ICH in this population, as there was a dramatic increase in prevalence with age (only 4.3% of ICH patients were <30 years old, while 44.4% were >60 years old). Men were twice as likely as women to suffer from ICH (67.3% vs. 32.7%), which may be explained by the higher rates of several risk factors in men, such as drinking and smoking. However, the average ages of men and women with ICH were not significantly different. In our study, 47% of all ICH patients were hypertensive, suggesting that hypertension was the leading cause of ICH in this sample group. Other major causes of ICH were thrombopenia, leukemia, and cerebrovascular malformations, especially in patients <30 years of age. Li *et al.* (2011) reported that the incidence of ICH throughout the year was closely related to meteorological factors such as season, daily air temperature, humidity, and atmospheric pressure. We found that the incidence of ICH was highest in winter and lowest in summer, consistent with their results, although the differences did not reach statistical significance in our study.

It has been reported that ICH is defined according to the location within the brain parenchyma, with

“deep” ICHs located within the basal ganglia and internal capsule (accounting for 35%–70% of deep ICH cases from study to study), brain stem (5%–10%), and cerebellum (5%–10%) (Carhuapoma *et al.*, 2009; Aguilar and Brott, 2011). In contrast, lobar ICH (15%–30%) refers to hemorrhages located in cortical-subcortical areas. All cortical lobes exhibited ICH, although it was more frequent in the temporal than in the parietal lobe. In a minority of cases, patients exhibited multiple lobar ICHs. In previous studies, deep ICHs accounted for about two thirds of spontaneous ICH cases, and lobar ICH for the remaining one third (Flaherty *et al.*, 2005). Our results were similar (37.2% of cases were lobar). There was also a relationship between ICH location and probably cause. For example, ICHs likely caused by hypertension, renal disease, or cerebral infarction were mainly located in the basal ganglia, while ICHs caused by warfarin (an anticoagulant), moyamoya disease, thrombopenia, leukemia, metastatic tumor, traffic accident, cerebrovascular malformation, or cerebral aneurysm were mostly located in the lobes in our patient samples.

A patient suffering from an ICH may present with a sudden onset of neurological dysfunction. In rank order, disturbed level of consciousness, limb dysfunction, headache, nausea, vomiting, dizziness, dysarthria, blurred vision, hyperspasmia, and deflection of the angle of the mouth were the most common symptoms of ICH in our study. Always (2009) reported headache in 40% of patients, which was higher than that reported in our study. A higher frequency of headache at onset of lobar and cerebellar hemorrhage compared to deep varieties (putaminal, thalamic, caudate) has been reported (Melo *et al.*, 1996), consistent with our results. Nausea and vomiting due to increased intracranial pressure may also occur.

The rate of neurological deterioration is typically faster in ICH than in ischemic strokes. For example, if the hemorrhage is large enough, pressure on the whole brain and brainstem may lead to a markedly diminished level of consciousness. In addition, a vascular leakage that begins small (2 cm in diameter) may enlarge over the first few hours, leading to rapid exacerbation of symptoms, including a rapid reduction in the patient’s level of consciousness (Always, 2009). Hyperspasmia at onset of ICH is rare, with a frequency below 10% in a previous series of ICH

cases that included all locations (Tatu *et al.*, 2000). Location determines risk of seizures (Lipton *et al.*, 1987; Bladin *et al.*, 2000), and the frontal lobe is especially common location of ICH (de Reuck *et al.*, 2007). Our results are in accord with these previous reports. We also found an association between symptoms and ICH location. Headache was the major symptom in lobar ICH, while the main symptoms of cerebellum hemorrhage were dizziness, nausea, and vomiting. Limb dysfunction was the main symptom of basal ganglia and thalamic hemorrhage. Disturbed level of consciousness was most commonly seen in ventricular, brainstem, multiple lobar, and multisite subcortical hemorrhage.

The mortality of ICH is about 40% within the first 30 d, making ICH one of the most deadly acute medical events (Broderick *et al.*, 1992). Within one year, the mortality can be as high as 50% (Vermeer *et al.*, 2002). In our study, 20 of the 65 deaths took place in the first 24 h, and 36 patients died in the first 72 h due to neurological complications, chiefly increased intracranial pressure and/or cerebral hernia. Death in the first month, but beyond the first few days following the event, is usually the result of medical complications such as pulmonary infection, intracranial infection, respiratory failure, and multiple organ failure. In our study, the highest mortality was observed for brainstem ICH (100.0%).

ICH is also a catastrophic complication in patients on anticoagulants (Fan *et al.*, 2012) and with hematological malignancy (Rogers, 2004), especially in patients with acute promyelocytic leukemia (Chen *et al.*, 2009). Moreover, ICH in patients with hematological malignancy may have several risk factors, including hypertension, vessel wall abnormalities, low platelet count, platelet dysfunction, coagulation factor deficiency, disseminated intravascular coagulation (DIC), sepsis, and/or hyperleukocytosis (Foss and Bruserud, 2008). In our study, mortality in cases associated with leukemia was also very high, with death occurring in 14 of 15 patients within 3 d from hematomas mainly located in the cerebral lobes. Early detection of coagulopathy and prompt correction can help reduce hemorrhagic complications in these patients.

In summary, we investigated the epidemiological and clinical characteristics of ICH in Hangzhou City, China. A total of 266 patients were confirmed to

have ICH at one or multiple sites. We then investigated the distribution of cases according to sex, age, season of onset, hemorrhage location, symptomology, most likely cause, complications, prognosis, and sequelae remaining after treatment and rehabilitation. The results showed that men were more vulnerable to ICH than women. Age was the greatest risk factor for ICH. The site distribution differed among age groups, possibly reflecting age-dependent changes in the primary cause. Hypertension was likely the most common cause of ICH, as almost half of patients were hypertensive. The ICH location was also associated with distinct symptom patterns. Prognosis and survival time in the hospital were also related to the location and cause of ICH.

Compliance with ethics guidelines

Yun-zhen HU, Jian-wen WANG, and Ben-yan LUO declare that they have no conflict of interest.

This article does not contain any studies with human or animal subjects performed by any of the authors.

References

- Aguilar, M.I., Brott, T.G., 2011. Update in intracerebral hemorrhage. *The Neurohospitalist*, **1**(3):148-159. [doi:10.1177/1941875211409050]
- Always, D., 2009. Identifying Stroke and Stroke Type. In: Always, D., Cole, J.W. (Eds.), *Stroke Essentials for Primary Care. Current Clinical Practice*. Humana Press, p.1-8. [doi:10.1007/978-1-59745-433-9_1]
- Bladin, C.F., Alexandrov, A.V., Bellevance, A., Bornstein, N., Chambers, B., Coté, R., Lebrun, L., Pirisi, A., Norris, J.W., 2000. Seizures after stroke: a prospective multicenter study. *Arch. Neurol.*, **57**(11):1617-1622. [doi:10.1001/archneur.57.11.1617]
- Broderick, J.P., Brott, T., Tomsick, T., Huster, G., Miller, R., 1992. The risk of subarachnoid and intracerebral hemorrhages in blacks as compared with whites. *N. Engl. J. Med.*, **326**(11):733-736.
- Broderick, J.P., Brott, T., Tomsick, T., Leach, A., 1993. Lobar hemorrhage in the elderly. The undiminishing importance of hypertension. *Stroke*, **24**:49-51. [doi:10.1161/01.STR.24.1.49]
- Broderick, J., Connolly, S., Feldmann, E., Hanley, D., Kase, C., Krieger, D., Mayberg, M., Morgenstern, L., Ogilvy, C.S., Vespa, P., et al., 2007. Guidelines for the management of spontaneous intracerebral hemorrhage in adults: 2007 update: a guideline from the American Heart Association/American Stroke Association Stroke Council, High Blood Pressure Research Council, and the Quality of Care and Outcomes in Research Interdisciplinary Working Group. *Stroke*, **38**:2001-2023. [doi:10.1161/STROKEAHA.107.183689]
- Carhuapoma, J.R., Mayer, S.A., Hanley, D.F., 2009. *Intracerebral Hemorrhage*. Cambridge University Press, New York, USA, p.1-16.
- Chen, C.Y., Tai, C.H., Tsay, W., Chen, P.Y., Tien, H.F., 2009. Prediction of fatal intracranial hemorrhage in patients with acute myeloid leukemia. *Ann. Oncol.*, **20**(6):1100-1104. [doi:10.1093/annonc/mdn755]
- Crandall, K.M., Rost, N.S., Sheth, K.N., 2011. Prognosis in intracerebral hemorrhage. *Rev. Neurol. Dis.*, **8**(1-2):23-29.
- Dennis, M.S., Burn, J.P., Sandercock, P.A., Barnford, J.M., Wade, D.T., Warlow, C.P., 1993. Long-term survival after first-ever stroke: the Oxfordshire Community Stroke Project. *Stroke*, **24**:796-800. [doi:10.1161/01.STR.24.6.796]
- de Reuck, J., Hemelsoet, D., van Maele, G., 2007. Seizures and epilepsy in patients with a spontaneous intracerebral haematoma. *Clin. Neurol. Neurosurg.*, **109**(6):501-504. [doi:10.1016/j.clineuro.2007.04.001]
- Fan, W.X., Deng, Z.X., Liu, F., Liu, R.B., He, L., Amrit, B., Zang, L., Li, J.W., Liu, X.R., Huang, S.M., et al., 2012. Spontaneous retroperitoneal hemorrhage after hemodialysis involving anticoagulant agents. *J. Zhejiang Univ.-Sci. B (Biomed. & Biotechnol.)*, **13**(5):408-412. [doi:10.1631/jzus.B1100357]
- Feigin, V.L., Lawes, C.M., Bennett, D.A., Anderson, C.S., 2003. Stroke epidemiology: a review of population-based studies of incidence, prevalence, and case-fatality in the late 20th century. *Lancet Neurol.*, **2**(1):43-53. [doi:10.1016/S1474-4422(03)00266-7]
- Feigin, V.L., Lawes, C.M., Bennett, D.A., Barker-Collo, S.L., Parag, V., 2009. Worldwide stroke incidence and early case fatality reported in 56 population-based studies: a systematic review. *Lancet Neurol.*, **8**(4):355-369. [doi:10.1016/S1474-4422(09)70025-0]
- Flaherty, M.L., Woo, D., Haverbusch, M., Sekar, P., Khoury, J., Sauerbeck, L., Moomaw, C.J., Schneider, A., Kissela, B., Kleindorfer, D., et al., 2005. Racial variations in location and risk of intracerebral hemorrhage. *Stroke*, **36**(5):934-937. [doi:10.1161/01.STR.0000160756.72109.95]
- Foss, B., Bruserud, O., 2008. Platelet functions and clinical effects in acute myelogenous leukemia. *Thromb. Haemost.*, **99**(1):27-37. [doi:10.1160/TH07-04-0240]
- Jiang, B., Wang, W.Z., Chen, H.L., Hong, Z., Yang, Q.D., Wu, S.P., Du, X.L., Bao, Q.J., 2006. Incidence and trends of stroke and its subtypes in China results from three large cities. *Stroke*, **37**:63-68. [doi:10.1161/01.STR.0000194955.34820.78]
- Juvela, S., 1996. Prevalence of risk factors in spontaneous intracerebral hemorrhage and aneurysmal subarachnoid hemorrhage. *Arch. Neurol.*, **53**(8):734-740. [doi:10.1001/archneur.1996.00550080048012]
- Lavados, P.M., Sacks, C., Prina, L., Escobar, A., Tossi, C.,

- Araya, F., Feuerhake, W., Galvez, M., Salinas, R., Alvarez, G., 2005. Incidence, 30-day case-fatality rate, and prognosis of stroke in Iquique, Chile: a 2-year community-based prospective study (PISCIS project). *Lancet*, **365**(9478): 2206-2215. [doi:10.1016/S0140-6736(05)66779-7]
- Li, X., Zhang, J.H., Qin, X.Y., 2011. Intracerebral hemorrhage and meteorological factors in Chongqing, in the southwest of China. *Acta Neurochir. Suppl.*, **111**:321-325. [doi:10.1007/978-3-7091-0693-8_53]
- Lipton, R.B., Berger, A.R., Lesser, M.L., Lantos, G., Portenoy, R.K., 1987. Lobar vs. thalamic and basal ganglion hemorrhage: clinical and radiographic features. *J. Neurol.*, **234**(2):86-90. [doi:10.1007/BF00314107]
- Melo, T.P., Pinto, A.N., Ferro, J.M., 1996. Headache in intracerebral hematomas. *Neurology*, **47**(2):494-500. [doi:10.1212/WNL.47.2.494]
- Qureshi, A.I., Tuhrim, S., Broderick, J.P., Batjer, H.H., Hondo, H., Hanley, D.F., 2001. Spontaneous intracerebral hemorrhage. *N. Engl. J. Med.*, **344**:1450-1460. [doi:10.1056/NEJM200105103441907]
- Rogers, L.R., 2004. Cerebrovascular complications in patients with cancer. *Semin. Neurol.*, **24**(4):453-460. [doi:10.1055/s-2004-861539]
- Tatu, L., Moulin, T., El Mohamad, R., Vuillier, F., Rumbach, L., Czorny, A., 2000. Primary intracerebral hemorrhages in the Besancon stroke registry: initial clinical and CT findings, early course and 30-day outcome in 350 patients. *Eur. Neurol.*, **43**(4):209-214. [doi:10.1159/000008177]
- Thrift, A.G., McNeil, J.J., Forbes, A., Donnan, G.A., 1996. Risk factors for cerebral hemorrhage in the era of well-controlled hypertension. *Stroke*, **27**:2020-2025. [doi:10.1161/01.STR.27.11.2020]
- Thrift, A.G., McNeil, J.J., Forbes, A., Donnan, G.A., 1998. Three important subgroups of hypertensive persons at greater risk of intracerebral hemorrhage. *Hypertension*, **31**:1223-1229. [doi:10.1161/01.HYP.31.6.1223]
- van Asch, C.J., Luitse, M.J., Rinkel, G.J., van der Tweel, I., Algra, A., Klijn, C.J., 2010. Incidence, case fatality, and functional outcome of intracerebral haemorrhage over time, according to age, sex, and ethnic origin: a systematic review and meta-analysis. *Lancet Neurol.*, **9**(2): 167-176. [doi:10.1016/S1474-4422(09)70340-0]
- Vermeer, S.E., Algra, A., Franke, C.L., Koudstaal, P.J., Rinkel, G.J., 2002. Long-term prognosis after recovery from primary intracerebral hemorrhage. *Neurology*, **59**(2): 205-209. [doi:10.1212/WNL.59.2.205]

Recommended paper related to this topic

Spontaneous retroperitoneal hemorrhage after hemodialysis involving anticoagulant agents

Authors: Wen-xing FAN, Zheng-xu DENG, Fang LIU, Rong-bo LIU, Ling HE, Bogati AMRIT, Li ZANG, Jing-wen LI, Xian-rong LIU, Song-min HUANG, Ping FU

doi:10.1631/jzus.B1100357

J. Zhejiang Univ.-Sci. B (Biomed. & Biotechnol.), 2012 Vol.13 No.5 P.408-412

Abstract: In this paper, we described the symptoms and treatment of a patient with diabetic nephropathy accompanied by spontaneous retroperitoneal hemorrhage after hemodialysis. An elderly female patient with diabetic nephropathy presented with severe pain, numbness, and an increasing swelling in the left hip and left thigh after six sessions of hemodialysis involving the use of an antiplatelet drug and an anticoagulant agent. Her hemoglobin decreased to 46 g/L. An abdominal ultrasound showed a hematoma in the left retroperitoneal space, and computed tomography (CT) findings revealed a 6 cm×8 cm×10 cm hematoma in the left psoas muscle. After aggressive supportive therapy [the administration of packed red blood cell transfusion, carbazochrome sodium sulfonate injection, and continuous venovenous hemofiltration (CVVH)], the patient's vital signs stabilized and her hemoglobin increased to 86 g/L. Repeat CT showed that the hematoma had been partially absorbed after two weeks. Eventually, the patient was discharged with stable vital signs. Physicians should be aware of the possibility of spontaneous retroperitoneal hemorrhage, particularly in patients with diabetic nephropathy undergoing hemodialysis involving the use of anticoagulant agents.