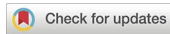



## Correspondence

<https://doi.org/10.1631/jzus.B2200369>



# Diagnostic strategies for diseases with fever in dental clinics

Jian YUAN<sup>1</sup>, Chuanxia LIU<sup>1</sup>, Zaiye LI<sup>2</sup>, Qianming CHEN<sup>1</sup>✉

<sup>1</sup>Stomatology Hospital, School of Stomatology, Zhejiang University School of Medicine, Clinical Research Center for Oral Diseases of Zhejiang Province, Key Laboratory of Oral Biomedical Research of Zhejiang Province, Cancer Center of Zhejiang University, Hangzhou 310006, China

<sup>2</sup>Department of Oral Medicine, West China Hospital of Stomatology, Sichuan University, State Key Laboratory of Oral Diseases, National Clinical Research Center for Oral Diseases, Chengdu 610041, China

Fever is an increase in body temperature beyond the normal range, acting as a protective inflammatory mechanism. This article summarizes diseases with fever encountered in dental clinics, including what is known about pyrexia in coronavirus infection, and further proposes a “six steps in one” identification and analysis strategy to guide the clinical work of stomatology.

According to the mechanism of occurrence, fever is divided into pyrogenic and nonpyrogenic types. Pyrogenic fever includes fevers induced by exogenous pyrogenic sources, such as microbial pathogens and their metabolic products, and endogenous pyrogenic sources, such as interleukins and tumor necrosis factor. Nonpyrogenic fever either results from direct damage to the thermoregulatory center, or is caused by excessive heat production or reduced heat dissipation. Based on the degree of fever, it can be divided into low-grade (37.3–38.0 °C), medium-grade (38.1–39.0 °C), high-grade (39.1–41.0 °C), and ultra-high-grade (>41.0 °C); fevers can also be classed according to their temporal occurrence pattern, such as continued fever, remittent fever, intermittent fever, undulant fever, relapsing fever, and irregular fever. According to the etiology, fever can be divided into infectious fever that is caused by a variety of pathogens, including bacteria, viruses, *Mycoplasma pneumoniae*, *Rickettsia*, spirochetes, fungi, and parasites, and non-infectious fever caused by allergies, tumors, and other factors (Wan and Lu, 2018).

Because of the complex anatomical structure of oral and maxillofacial regions, the occurrence, development, and prognosis of infections in these areas have their own peculiarities. According to the infection route, oral and maxillofacial infections are classified into odontogenic, adenogenic, glandgenic, hematogenous, traumatic, and iatrogenic infections (Zhang et al., 2020). In addition, mucosa-associated infection was added as a supplementary category to oral and maxillofacial infection routes. Oral febrile diseases are divided into infectious fever and non-infectious fever, and most clinical cases fall into the former group (Dinarello and Bunn, 1997). The common routes of infection are as follows (Zhang et al., 2020): (1) Odontogenic infection. This is a unique and common method of infection in the oral and maxillofacial regions. If not treated in time, it can lead to serious local or systemic infection, such as endocarditis, cerebral abscess, and mediastinitis, and can even be life-threatening (Arslan et al., 2016; Ogle, 2017). Its pathogenesis can involve a variety of microbial infections caused by multiple facultative and strict anaerobes, which are usually confined to the teeth and alveoli (Zhang et al., 2020). Fever caused by such infections is classified as odontogenic fever. (2) Mucosa-associated infection. Most oral mucosal diseases are secondary bacterial or viral infection via direct contact or droplet transmission. However, this infection type currently lacks an independent nomenclature; therefore, we have added a new nomenclature—mucosa-associated infection. Fever caused by such infections is classified as mucosa-associated fever. (3) Adenogenic infection. Oral and maxillofacial lymph node infections can spread and cause glandular infection. Children’s lymph nodes are not yet fully developed; hence they are prone to

✉ Qianming CHEN, [qmchen@zju.edu.cn](mailto:qmchen@zju.edu.cn)

Qianming CHEN, <https://orcid.org/0000-0002-5371-4432>

Received July 18, 2022; Revision accepted Jan. 8, 2023;  
Crosschecked Feb. 22, 2023

© Zhejiang University Press 2023

infection. Lymphadenitis of the face and neck in children is mostly adenogenic infection of the upper respiratory tract, which can easily spread to the surrounding area and cause space infection. Fever caused by such infections is classified as adenogenic fever. (4) Traumatic infection. This occurs secondary to trauma, and is classified as traumatic fever, such as fever caused by bacterial infection after tooth extraction. (5) Hematogenous infection. The purulent infection caused by bacterial emboli of purulent lesions in other parts of the body disseminated to the oral and maxillofacial regions through blood is often secondary to systemic sepsis, and the condition is often more serious. Fever caused by such infections is classified as hematogenous fever. (6) Iatrogenic infection. This accompanies secondary infection caused by medical staff during a diagnostic or treatment process (such as physical examination, local anesthesia, surgery, and puncture), resulting from the lack of strict adherence to the principle of sterility. This type of nosocomial infection is called iatrogenic infection, and oral and maxillofacial space infections can cause the so-called iatrogenic fever.

A clear diagnosis of febrile diseases is not only conducive to the diagnosis and treatment of oral diseases but can also enable the investigation of systemic diseases. Dentists need to establish holistic thinking. In addition to developing a deep understanding of the clinical characteristics of each febrile disease, dentists also need a clear decision-making strategy. This is provided through our “six steps in one” diagnostic approach, which can be used in the entire process of febrile disease diagnosis and treatment. The diagnostic strategies consist of the following six parts: (1) Identify age and sex of the patient at onset. Different febrile diseases may have typical onset ages. Children’s immune systems are not yet fully developed, and they are the most common age group for infectious diseases. The febrile diseases of elderly patients are mostly considered chronic diseases caused by infectious diseases or malignant tumors. Meanwhile, fever caused by allergic disease is more common in young people. (2) Distinguish the characteristics of fever onset and course. It should be determined whether the fever is acute, chronic, or periodic. Acute fever mostly occurs in cases of infectious fever or allergic fever, while non-infectious fever is generally chronic. (3) Clarify oral clinical manifestations. Oral manifestations may be the first and most important sign of certain diseases.

Most oral febrile diseases have locatable signs and symptoms. Specialists strive to perform comprehensive oral examinations, including those of caries, residual roots, the periodontal region, the sinus tract, mucosal color, gum shape and texture, and maxillofacial swelling, and finally carry out clinical decision-making for patients based on the corresponding disease. (4) Identify predisposing factors. The predisposing factors mainly include surgical history, trauma history, history of cold, medication history, exposure history, presence of malignant tumor, and radiotherapy and chemotherapy history. These conditions can induce corresponding diseases, resulting in fever. (5) Complete systemic examination. A detailed systemic examination should be performed, especially of the maxillofacial and cervical lymph nodes, skin, eyes, external genitalia, etc. (6) Importance of auxiliary examination. Various laboratory and imaging examination methods should be promoted, and puncture examination and therapeutic diagnosis should be used when necessary to provide correct diagnosis and treatment.

We divided the common diseases with fever in dental clinics into infectious and non-infectious febrile diseases. The characteristics of infectious febrile diseases are as follows (Lee et al., 2012; DeWitt et al., 2017; Wan and Lu, 2018): (1) the onset is acute and often is accompanied by chills; (2) systemic symptoms of infection are present; (3) routine blood examination reveals white blood cell counts higher than  $1.2 \times 10^9 \text{ L}^{-1}$  or lower than  $0.5 \times 10^9 \text{ L}^{-1}$ ; (4) positive C-reactive protein (CRP) indicates that the fever is most likely caused by bacterial infection, and a negative result indicates that it is most likely caused by viral infection; (5) increased neutrophil alkaline phosphatase score. The diagnostic indicators for non-infectious fever in dental clinics are as follows (Wan and Lu, 2018): (1) the thermal course is generally long, up to several months; (2) the general condition is good without obvious symptoms of poisoning; (3) the anti-infection treatment is ineffective.

The common infectious diseases with fever encountered in dental clinics include odontogenic fever (I), mucosa-associated fever (II), adenogenic fever (III), hematogenous fever (IV), traumatic fever (V), iatrogenic fever, and other fevers. The representative diseases of odontogenic fever (I) are as follows: (1) Acute periapical periodontitis. The fever caused by this condition is mostly low-grade, which often occurs in the subperiosteal abscess period. This is accompanied by

severe tooth pain, percussion pain, gingival swelling, and tenderness (Fan and Zhou, 2003). (2) *Opsigenes pericoronitis*. The fever is characterized by high temperature with chills and appears in the acute phase, accompanied by increased white blood cell count and general malaise (Zhang et al., 2020). (3) Pyogenic osteomyelitis of the jaws. The acute phase is characterized by high-grade fever with chills, elevated white blood cell counts, and symptoms of systemic toxicity. At the same time, this phase is accompanied by severe throbbing pain and swelling in the oral area and tooth percussion pain in the ward with a sense of elongation. In the chronic phase, fever is mostly low-grade, with local swelling and congestion with sinus tract formation, pus discharge, and loose teeth (Zhang et al., 2020). (4) Oral and maxillofacial space infection (adults). Fever in this condition often occurs in the acute phase and is characterized by high temperature

with chills, as well as systemic infection symptoms such as dehydration, increased white blood cell count, and general malaise. In addition, it is accompanied by redness, swelling, heat, pain, and dysfunction in the infected area, and it easily spreads to adjacent spaces (Zhang et al., 2020). The diagnostic features of common oral mucosa-associated febrile diseases (II) are shown in Table 1 (Chen and Zhou, 2008; Chen and Zeng, 2019) and as follows: (1) Primary herpetic stomatitis. It can manifest as high-grade fever in the prodromal period. The fever lasts for approximately 4 d, and then small blisters appear in clusters on the skin and mucous membranes. Then, the heat subsides, and a crust is formed after the herpes ruptures. (2) Varicella. Fever occurs at the beginning of the course of the disease, mostly during acute fever, usually lasting for approximately 3 d, and a rash develops when the fever is the highest. Moreover, there are pain and ulceration

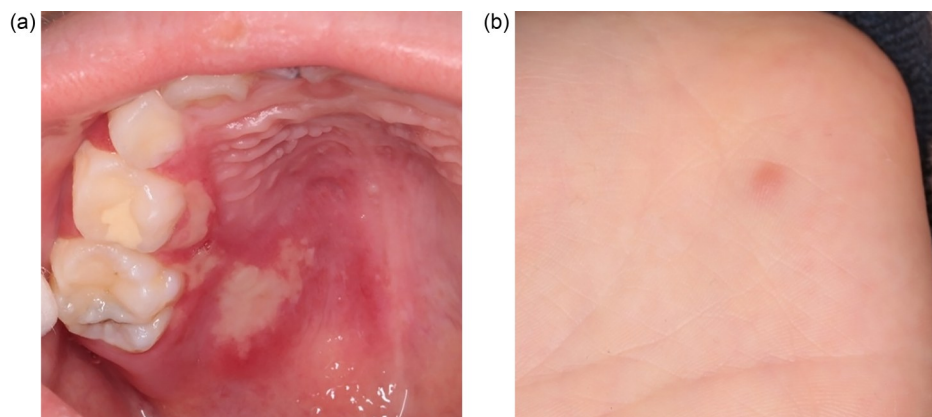
**Table 1 Diagnostic features of common oral mucosa-associated febrile diseases**

Name	Pathogeny	Fever characteristics	Systemic symptom	Susceptible group	Oral lesion	Prognosis
Primary herpetic stomatitis	<i>Herpes simplex virus</i>	High-grade fever lasts for approximately 4 d (>38 °C)	Regional lymphadenopathy, upper respiratory tract infection symptoms	Children	Small blisters distributed singly or in clusters	Good
Varicella	<i>Herpes varicella-zoster virus</i>	Onset fever	Skin pruritus and erythema; fatigue, and anorexia	Children	Blisters distributed in oral mucosa or skin	Poor prognosis in severe cases
Herpes zoster	<i>Herpes varicella-zoster virus</i>	Low-grade, sometimes moderate fever	Fatigue	The elderly	Unilateral skin mucosal herpes along nerve rami with severe pain	Poor prognosis in severe cases
Hand-foot-mouth disease	<i>Coxsackie virus</i> , <i>Enterovirus 71</i> , etc.	Low-grade fever lasts for 1–3 d	Symptoms of upper respiratory tract infection	Children	Scattered herpes or small erosion in oral mucosa	Good
Herpangina	<i>Coxsackie virus A</i>	Sudden high-grade fever	Mild	Children	Pharyngeal herpes, sore throat	Good
Epidemic parotitis	Virus	High-grade fever	Headache, general malaise	Children from 5 to 15 years of age	Parotid gland swelling, distending pain, buccal mucosa hyperemia	Good
Oral tuberculosis	<i>Mycobacterium tuberculosis</i>	Low-grade fever and night sweats when with systemic damage	Signs of tuberculosis	All	Tuberculosis ulcer, lupus vulgaris	Poor prognosis in severe cases
Deep mycosis	<i>Candida albicans</i>	High-grade fever	No characteristic symptom	Immunocompromised people	Oral mucosal ulcer, pseudomembrane, bone destruction, black hairy tongue	Few have poor prognosis

in the mucosal area. (3) Herpes zoster. Low-grade transient fever appears before the rash. At the same time, there are unilateral clusters distributed along the nerve segment, accompanied by pain. (4) Hand-foot-mouth disease (HFMD). Fever usually manifests as low-grade fever in the prodromal period lasting for 1–3 d, accompanied by fatigue and anorexia. If high-grade fever persists, serious complications should be considered. The mucous membrane is scattered with erythema and blisters, which often rupture into an erosion surface. The common age for this condition is under three years old. The clinical features of HFMD are shown in Fig. 1. (5) Herpangina. This disease is characterized by sudden high-grade fever, high contagiousness, rapid spread, and lesions involving only the posterior mucosa of the oral cavity. (6) Epidemic parotitis. Fever is characterized as acute, and the fever grade is proportional to the condition, with swelling of the parotid gland and blockage of the parotid duct. (7) Oral tuberculosis. Fever is long-term and low-grade, and features night sweats and hot flashes in the afternoon. Tuberculosis ulcers and early tuberculosis sores may occur. (8) Deep mycosis. High-grade fever, continued fever, or irregular fever may occur. Oral mucosal ulcers, pseudomembranes, bone destruction, and even perforation may be present. Adenogenic fever (III) is characterized by high temperature with chills and appears in the acute phase with systemic symptoms of infection. Moreover, redness, swelling, heat, and pain can be observed in the infected area (Zhang et al., 2020). One example is oral and maxillofacial space infection in children. Hematogenous fever (IV)

features the sudden onset of high-grade fever with chills and even vomiting. Local swelling, cellulitis, and fistula are also present. Osteomyelitis of the jaws (neonatus) mostly occurs in the maxilla, and infants within three months of age are susceptible (Zhang et al., 2020). Traumatic fever (V) is caused by bacterial invasion and secondary infection after the integrity of the skin and mucous barrier is destroyed by maxillofacial trauma (Zhang et al., 2020). In addition, fever caused by acquired immunodeficiency syndrome (AIDS) is persistent and long-term but not specific. This is accompanied by weeks of unexplained severe fatigue and persistent widespread lymphadenopathy. Oral manifestations include candidiasis, herpes zoster, glossitis rhomboidea mediana, hairy leukoplakia, oral leukoplakia, and Kaposi's sarcoma. The routes of infection are diverse and can be iatrogenic, hematogenous, or sexually transmitted (Chen and Zhou, 2008).

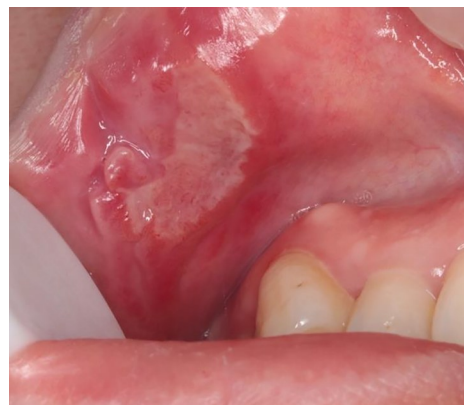Non-infectious fevers in dental clinics include allergic fever, fever from physical and chemical damages, fever associated with blood disease, and neoplastic fever. The common diseases of allergic fever are as follows: (1) Allergic medicamentosis stomatitis. In mild cases, there may be low-grade fever with mild general malaise; in severe cases, high-grade fever may be present, accompanied by mucosal edema, blisters, erosions, and ulcers. Re-exposure to the allergen is prone to inducing recurrence (Chen and Zhou, 2008; Chen and Zeng, 2019). (2) Erythema multiforme. In mild cases, there is sometimes low-grade fever, accompanied by prodromal symptoms such as headache, fatigue, and joint pain. In severe cases, there may be



**Fig. 1** Clinical features of hand-foot-mouth disease (HFMD). An eight-year-old boy complained of fever accompanied by oral and hand herpes for 2 d. The diagnosis was HFMD. (a) Multiple irregular superficial erosions on the oral palate, covered with yellow pseudomembrane, with their periphery manifesting hyperemia and redness. (b) A blister with a diameter of 1 mm on the palm.

high-grade fever, accompanied by oral mucosa edema, erythema or blisters, pseudomembranes, and blood scabs on the lips. Young people are prone to hair loss and relapse (Chen and Zhou, 2008; Chen and Zeng, 2019). (3) Major recurrent aphthous ulcer. There may be low-grade fever, accompanied by general malaise such as fatigue and joint pain. Ulcers are characterized as being “red, yellow, concave, and painful,” with local and regional lymph node swelling and pain (Chen and Zhou, 2008; Chen and Zeng, 2019). The clinical features are shown in Fig. 2. (4) Kawasaki disease. Fever is characterized by sudden high temperature with a long duration (5–30 d), accompanied by the characteristic “arbutus tongue.” This condition is most prevalent in infants and young children (Liu et al., 2021). The fever caused by oral and maxillofacial trauma has acute onset and short-term postoperative duration. It is more common in mechanical, chemical, and physical injuries, such as tissue damage after major surgery, internal bleeding, and extensive burns (Wan and Lu, 2018). Leukemia is a fever associated with blood disease. Acute leukemia has fever at the onset, which may be accompanied by hemorrhage in various parts of the body, lymphadenopathy, and hepatosplenomegaly, whereas chronic leukemia fever is low-grade and is featured by hyperhidrosis, weight loss, anemia, hemorrhage, and splenomegaly. The gums are pale, overgrown, bleeding, and irregular, and superficial ulcers appear in the mouth, which cannot heal easily (Ge et al., 2018; Chen and Zeng, 2019). Neoplastic fever is a long-term fever with a body temperature higher than 37.8 °C at least once a day for a duration of more than two weeks. Conventional antibiotics are ineffective, with no evidence of infection or allergy support, and naproxen treatment can quickly reduce the fever (Chang, 1989). Tumor-associated fever may be caused by the release of pyrogenic substances from the necrosis and liquefaction of tumor tissue in the center of rapidly progressive lesions in patients with malignant tumors (Pasikhova et al., 2017). It occurs in patients with advanced cancer and cancer metastasis (Odagiri et al., 2019).

Furthermore, fever is the first symptom of patients with coronavirus disease 2019 (COVID-19) (Jiang et al., 2020). It is an infectious fever caused by the invasion of severe acute respiratory syndrome-coronavirus 2 (SARS-CoV-2) virus. Low-grade and moderate-grade fevers are the main symptoms, and



**Fig. 2** Major recurrent aphthous ulcer. A 35-year-old female patient complained of oral ulcer recurring for three years, aggravated for one year, and accompanied by low-grade fever and fatigue. Examination revealed an ulcer with a diameter of about 10 mm×5 mm in the mucosa of the left lower lip, characterized as “red, yellow, concave, and painful” and covered by yellow and white pseudomembrane. The diagnosis was major recurrent aphthous ulcer.

high-grade fever occurs in a small number of critically ill patients. Symptoms such as cough (68.6%), myalgia or fatigue (35.8%), expectoration (28.2%), and dyspnea (21.9%) have also been found (Iser et al., 2020; Li et al., 2020). Angiotensin-converting enzyme 2 (ACE2) expression, as a key receptor for SARS-CoV-2 entry into cells, was reported to be highly enriched in human oral mucosal epithelial cells and play a vital role in the final infection. This discovery underscores the biological evidence that the oral cavity is an important gateway for the spread of SARS-CoV-2 and provides a basis for future oral diagnostic, treatment, and preventive strategies in daily life (Xu et al., 2020). The oral symptoms are mainly allotriogeusia and xerostomia. In addition, transient U-shaped lingual papillitis, papillitis glossitis with patchy depapillation, burning mouth syndrome, mucositis, macroglossia, aphthous ulcers, and scattered blister-like ulcers with surrounding erythema, as well as other symptoms, may appear (Brandão et al., 2021; González et al., 2021). Any of these findings may be key clues to the diagnosis of COVID-19.

In conclusion, fever is a common accompanying symptom of many diseases, and its etiology is complex and changeable, often involving systemic diseases. With the COVID-19 pandemic, clarifying the diagnosis and differential diagnosis of patients with fever in dental clinics can not only prevent the transmission of the virus, but also take precautions which

serve as a guide for managing other respiratory diseases (Ge et al., 2020). The flowchart of fever diagnosis is shown in Fig. 3.

**Acknowledgments**

This work is supported by the National Natural Science Foundation of China (No. 81902755). We thank Dr. Zhao HONG (The First Affiliated Hospital, School of Medicine, Zhejiang University, Hangzhou, China) for the guidance on classification of fever.

**Author contributions**

Jian YUAN designed the study, performed the research, and wrote the paper. Chuanxia LIU and Zaiye LI collected cases and polished the paper. Qianming CHEN contributed the central idea, directed the revision of the article, and wrote the initial draft of the paper. All authors have read and approved the final manuscript, and therefore, have full access to all the data in the study and take responsibility for the integrity and security of the data.

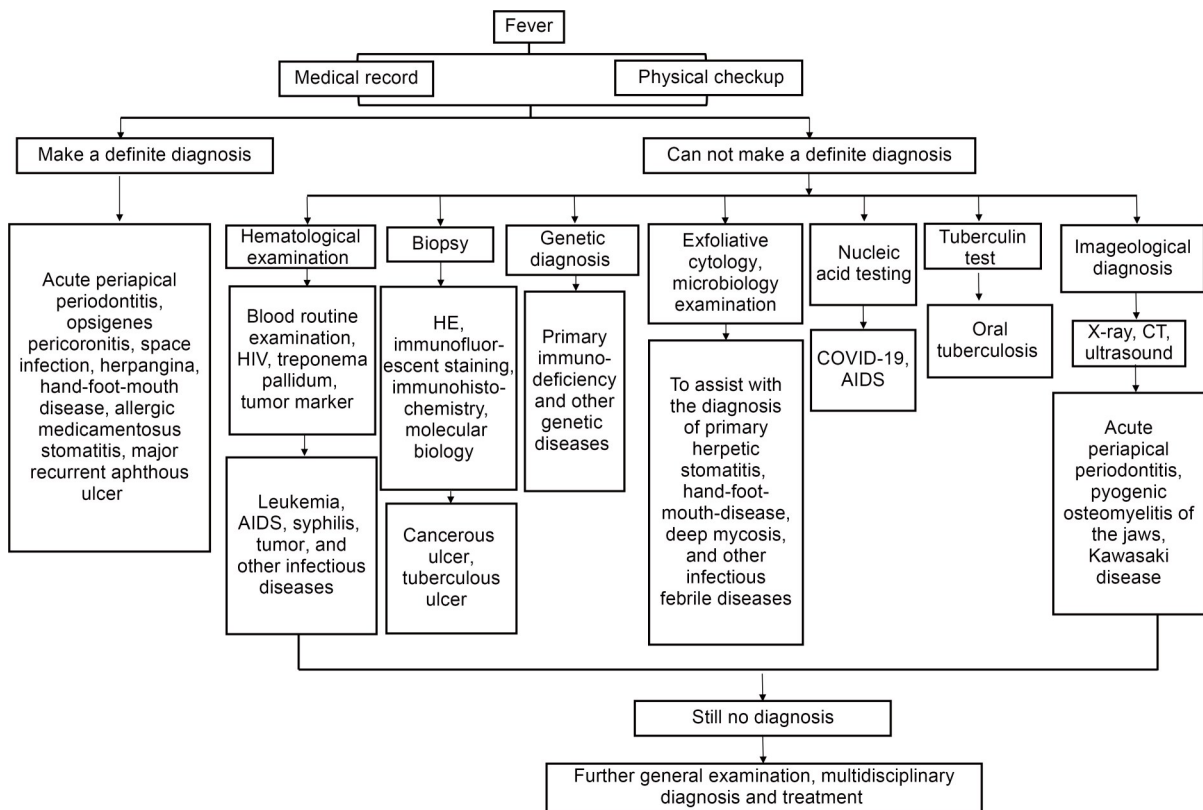
**Compliance with ethics guidelines**

Jian YUAN, Chuanxia LIU, Zaiye LI, and Qianming CHEN declare that they have no conflict of interest.

This work was approved by the Ethics Committee of Stomatology Hospital, Zhejiang University School of Medicine, Hangzhou, China (No. 2021-56(R)). All procedures followed were in accordance with the ethical standards of the responsible committee on human experimentation (institutional and national) and with the Helsinki Declaration of 1975, as revised in 2008 (5). Informed consent was obtained from all patients for being included in the study. Additional informed consent was obtained from all patients for which identifying information is included in this article.

**References**

Arslan F, Karagöz E, Arslan BY, et al., 2016. An unnoticed origin of fever: periapical tooth abscess. Three case reports and literature review. *Infez Med*, 24(1):67-70.  
 Brandão TB, Gueiros LA, Melo TS, et al., 2021. Oral lesions in patients with SARS-CoV-2 infection: could the oral cavity be a target organ? *Oral Surg Oral Med Oral Pathol Oral Radiol*, 131(2):e45-e51.  
<https://doi.org/10.1016/j.oooo.2020.07.014>  
 Chang JC, 1989. Neoplastic fever. A proposal for diagnosis. *Arch Intern Med*, 149(8):1728-1730.  
<https://doi.org/10.1001/archinte.1989.00390080014004>  
 Chen QM, Zhou ZT, 2008. Oral Medicine. People’s Medical Publishing House, Beijing, China (in Chinese).  
 Chen QM, Zeng X, 2019. Case-Based Oral Medicine. People’s



**Fig. 3** Flowchart of fever diagnosis. HIV: human immunodeficiency virus; AIDS: acquired immune deficiency syndrome; HE: hematoxylin-eosin; COVID-19: coronavirus disease 2019; CT: computed tomography.

- Medical Publishing House, Beijing, China, p.8-468 (in Chinese).
- DeWitt S, Chavez SA, Perkins J, et al., 2017. Evaluation of fever in the emergency department. *Am J Emerg Med*, 35(11):1755-1758.  
<https://doi.org/10.1016/j.ajem.2017.08.030>
- Dinareello CA, Bunn PA, 1997. Fever. *Semin Oncol*, 24(3):288-298.
- Fan MW, Zhou XD, 2003. Endodontics. People's Medical Publishing House, Beijing, China, p.180-186 (in Chinese).
- Ge JB, Xu YJ, Wang C, 2018. Internal Medicine. People's Medical Publishing House, Beijing, China (in Chinese).
- Ge ZY, Yang LM, Xia JJ, et al., 2020. Possible aerosol transmission of COVID-19 and special precautions in dentistry. *J Zhejiang Univ-Sci B (Biomed & Biotechnol)*, 21(5):361-368.  
<https://doi.org/10.1631/jzus.B2010010>
- González AN, Magaletskyy K, Carrillo PM, et al., 2021. Are oral mucosal changes a sign of COVID-19? A cross-sectional study at a field hospital. *Actas Dermosifiliogr (Engl Ed)*, 112(7):640-644.  
<https://doi.org/10.1016/j.adengl.2021.05.010>
- Iser BPM, Sliva I, Raymundo VT, et al., 2020. Suspected COVID-19 case definition: a narrative review of the most frequent signs and symptoms among confirmed cases. *Epidemiol Serv Saude*, 29(3):e2020233.  
<https://doi.org/10.5123/S1679-49742020000300018>
- Jiang F, Deng LH, Zhang LQ, et al., 2020. Review of the clinical characteristics of coronavirus disease 2019 (COVID-19). *J Gen Intern Med*, 35(5):1545-1549.  
<https://doi.org/10.1007/s11606-020-05762-w>
- Lee CC, Hong MY, Lee NY, et al., 2012. Pitfalls in using serum C-reactive protein to predict bacteremia in febrile adults in the ED. *Am J Emerg Med*, 30(4):562-569.  
<https://doi.org/10.1016/j.ajem.2011.02.012>
- Li LQ, Huang T, Wang YQ, et al., 2020. COVID-19 patients' clinical characteristics, discharge rate, and fatality rate of meta-analysis. *J Med Virol*, 92(6):577-583.  
<https://doi.org/10.1002/jmv.25757>
- Liu XL, Wang F, Zhou KY, et al., 2021. Clinical characteristics of Kawasaki disease in adolescents. *J Int Med Res*, 49(11):3000605211056839.  
<https://doi.org/10.1177/03000605211056839>
- Odagiri T, Morita T, Sakurai H, et al., 2019. A multicenter cohort study to explore differentiating factors between tumor fever and infection among advanced cancer patients. *J Palliat Med*, 22(11):1331-1336.  
<https://doi.org/10.1089/jpm.2018.0594>
- Ogle OE, 2017. Odontogenic infections. *Dent Clin North Am*, 61(2):235-252.  
<https://doi.org/10.1016/j.cden.2016.11.004>
- Pasikhova Y, Ludlow S, Baluch A, 2017. Fever in patients with cancer. *Cancer Control*, 24(2):193-197.  
<https://doi.org/10.1177/107327481702400212>
- Wan XH, Lu XF, 2018. Diagnostics. People's Medical Publishing House, Beijing, China, p.8-13, 230-468 (in Chinese).
- Xu H, Zhong L, Deng JX, et al., 2020. High expression of ACE2 receptor of 2019-nCoV on the epithelial cells of oral mucosa. *Int J Oral Sci*, 12:8.  
<https://doi.org/10.1038/s41368-020-0074-x>
- Zhang ZZ, Shi B, Zhang CP, 2020. Oral and Maxillofacial Surgery. People's Medical Publishing House, Beijing, China (in Chinese).