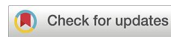



Research Article

<https://doi.org/10.1631/jzus.B2300586>



Clinical relevance of distolingual roots and periodontal status in mandibular first molars: a cross-sectional study employing CBCT analysis

Feifei MAO*, Meng WANG*, Shuai ZHOU, Yan ZHAO, Jiaping HUANG, Fengying YIN, Haiping YANG, Pei-hui DING✉

Stomatology Hospital, School of Stomatology, Zhejiang University School of Medicine, Zhejiang Provincial Clinical Research Center for Oral Diseases, Key Laboratory of Oral Biomedical Research of Zhejiang Province, Cancer Center of Zhejiang University, Hangzhou 310016, China

Abstract: Objectives: Distolingual root of the permanent mandibular first molar (PMFM-DLR) has been frequently reported, which may complicate the treatment of periodontitis. This study aimed to assess the morphological features of PMFM-DLR and investigate the correlation between the morphological features of PMFM-DLR and periodontal status in patients with Eastern Chinese ethnic background. Materials and methods: A total of 836 cone beam computed tomography (CBCT) images with 1497 mandibular first molars were analyzed to observe the prevalence of PMFM-DLR at the patients and tooth levels in Eastern China. Among them, complete periodontal charts were available for 69 Chinese patients with 103 teeth. Correlation and regression analyses were used to evaluate the correlation between the morphological features of DLR, bone loss, and periodontal clinical parameters, including clinical attachment loss (CAL), probing pocket depth (PPD), gingival recession (GR), and furcation involvement (FI). Results: The patient-level prevalence and tooth-level prevalence of DLR in mandibular first molars were 29.4% and 26.3%, respectively. Multiple linear regression analysis suggested that bone loss at the lingual site and CAL were negatively affected by the angle of separation between distolingual and mesial roots in the transverse section, while they were significantly influenced by age and the angle of separation between distobuccal and mesial roots in the coronal section. Conclusions: The prevalence of PMFM-DLR in Eastern China was relatively high in our cohort. The morphological features of DLR were correlated with the periodontal status of mandibular first molars. This study provides critical information on the morphological features of DLR for improved diagnosis and treatment options of mandibular molars with DLR.

Key words: Distolingual root; Mandibular first molar; Periodontal clinical parameter; Clinical attachment loss; Cone beam computed tomography (CBCT)

1 Introduction

Periodontitis is a chronic inflammatory and destructive disease of the periodontal tissues surrounding teeth. Morphological abnormalities and developmental variations, such as palatogingival grooves, enamel pearls, and cervical enamel projections, contribute to localized periodontal destruction (Goldstein, 1979; Hou and Tsai, 1993; Blanchard et al., 2012). As the first permanent teeth appearing in the human

mouth, the maxillary and mandibular first molars are considered to be “the key to occlusion.” Permanent mandibular first molar (PMFM) usually has two roots: one mesial and one distal. The major variant of this tooth is the presence of a supernumerary distolingual root (DLR), which was first mentioned by Carabelli in 1844 and was later called *radix entomolaris* (RE) (Chandra et al., 2011). DLR has also been called “three-rooted permanent mandibular first molar” (Jang et al., 2013).

The presence of a DLR in the PMFM (PMFM-DLR) has been associated with specific ethnic groups. For instance, the prevalence of PMFM-DLR in the African population was reported to be up to 3.12% (Sperber and Moreau, 1998), whilst this frequency in the Eurasian population was less than 5% (Curzon,

✉ Pei-hui DING, phding@zju.edu.cn

* The two authors contributed equally to this work

Pei-hui DING, <https://orcid.org/0000-0001-6147-1787>

Received Sept. 21, 2023; Revision accepted Dec. 11, 2023;
Crosschecked Feb. 19, 2024

© Zhejiang University Press 2024

1973). The prevalence of DLR in populations with Mongoloid traits varied from 5% to >40%, including Eskimo, Chinese, and American Indian populations (Turner, 1971; Huang et al., 2010). A recent study (Aung and Myint, 2022) pointed out that the global tooth-level prevalence of PMFM-DLR was 8.85% by means of a random effect model, ranging from 0% to 29% all over the world, and the global patient-level prevalence of PMFM-DLR was 10.3%, ranging from 0% to 35%.

At present, limited information exists on the morphological features and clinical relevance of PMFM-DLR. However, PMFM-DLR was found to be frequently present in people with Chinese ethnic background (Abella et al., 2012; Hsu et al., 2021), which makes root canal therapy and periodontal treatment more challenging. Although research interest in root canal morphology and DLR therapy seems to be persistent (de Moor et al., 2004; Gu et al., 2010), the relationship between DLR and periodontal condition has been seldom reported or clearly described.

Cone beam computed tomography (CBCT) contributes to the early and accurate diagnosis of PMFM-DLR. In a comparison of the blurring and overlay of anatomical structures in two-dimensional (2D) images such as extraoral panoramic radiographs and intraoral images (Woelber et al., 2018), CBCT demonstrated high accuracy in the detection of periodontal structures (Mol and Balasundaram, 2008). Unlike conventional radiography, CBCT could also provide detailed information on morphologic feature analysis using three-dimensional (3D) images and cross-sectional views (Lin et al., 2014). Although many authors have studied DLR using CBCT (Lee et al., 2016), few reported on its prevalence in Eastern China.

The aims of this study were to evaluate the prevalence of PMFM-DLR in Eastern China through CBCT analysis and to determine whether the morphological features of DLR correlate with the periodontal status of involved teeth.

2 Materials and methods

2.1 Subjects and study design

CBCT data, previously obtained from the Department of Periodontics, Stomatology Hospital, School of Stomatology, Zhejiang University School of Medicine

(Hangzhou, China) from March 2022 to September 2022, were retrospectively screened and examined by qualified periodontists. Patients were screened for the presence of DLR by moving from the coronal to the apical direction along the long axis of PMFM (Fig. 1).

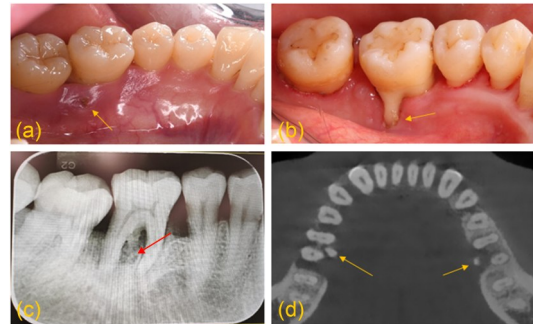


Fig. 1 Clinical and radiographic images of mandibular first molars with distolingual roots. (a) Swelling and infection (arrow) of the gingiva at the lingual site; (b) Recession (arrow) of the gingiva at the lingual site; (c) Radiograph of mandibular first molar with distolingual root (arrow); (d) Cone beam computed tomography (CBCT) of mandibular first molars with distolingual root (arrows).

The samples were selected according to the following criteria: (1) the presence of unilateral or bilateral PMFMs with DLR; (2) complete root formation of the PMFMs in CBCT; (3) patients with previous periodontal chart. The exclusion criteria were: (1) mandibular first molars with bridges, prosthetic crowns, or posts; (2) the low quality of the CBCT images, not allowing for accurate morphology measurements.

2.2 Periodontal examination

Periodontal charts from 69 Chinese patients (40 males and 29 females) with 103 teeth were collected from the outpatient records, which included the following parameters: probing pocket depth (PPD), gingival recession (GR), bleeding on probing (BOP), clinical attachment loss (CAL), furcation involvement (FI), and tooth mobility. Data for all teeth were collected on the periodontal condition using a UNC-15 periodontal probe. The PPD and recession of each tooth were measured and recorded at six sites—the mesial, mid, and distal aspects of buccal and lingual surfaces (Sharma et al., 2017). CAL was recorded as the sum of PPD and recession. For each site probed, BOP was recorded dichotomously for presence or absence. For each tooth, the degree of tooth mobility was assessed and recorded. FI was evaluated using a Nabers probe

based on Hamp's classification (Hamp et al., 1975). According to this system, Grade I demonstrates horizontal loss of periodontal tissue support of ≤ 3 mm, while Grade II demonstrates horizontal loss of periodontal tissue support of >3 mm but not encompassing the total width of the furcation area, and Grade III demonstrates the horizontal through-and-through destruction of periodontal tissues in the furcation.

2.3 Morphology evaluation

The clinical relevant morphologic features of DLR were analyzed by CBCT. The CBCT scans were obtained using a NewTom 3G scanner (NewTom VGI, Italy) at 110 kV and 12 mA with an exposure time of 3.6 s and saving data in NNT Viewer. The voxel sizes of the images were 12 cm \times 8 cm field of view with 0.3 mm slice thickness.

Images in the sagittal, transverse, and coronal views were analyzed using the NewTom NNT viewer (Version 12.1). To assess the agreement between examiners and the reliability of CBCT image measurement, all data were measured twice by two calibrated investigators (Feifei MAO and Meng WANG) who were trained by an experienced radiologist (Jun WANG, Stomatology Hospital, School of Stomatology, Zhejiang University School of Medicine). The intra-class correlation coefficients (ICCs) were above 0.850 for all measurements.

A total of 69 CBCT images with 103 PMFM-DLRs were measured for the following parameters: (1) length of the DLR and position of the furcation entrance (Fig. 2a); (2) parameters relevant for the separation angle of DLR, including separation angle of roots in the transverse section (Fig. 2b), angle of separation between distobuccal and mesial roots (Fig. 2c), and angle of separation between distolingual and distobuccal roots (Fig. 2d); (3) measurement of bone loss at the buccal site and the lingual site (Fig. 2a) (Misch et al., 2006).

2.4 Sample size calculation

The tooth-level prevalence of PMFM-DLR was reported to be 24.1% in the East Asian population (Aung and Myint, 2022). The estimated sample size of 812 was determined using the PASS 15 software, assuming a proportion of 24.1% and a confidence interval (CI) of 0.95 with a CI width of 0.06 (two-sided). Taking into account a dropout rate of 20%, a total of 1015

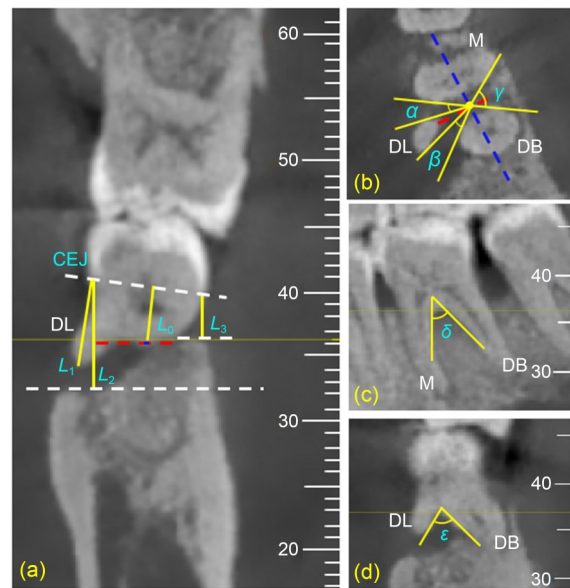


Fig. 2 Morphologic features of the distolingual root (DLR) in cone beam computed tomography (CBCT). (a) Length of root trunk (opening of furcation from CEJ) (L_0), length of DLR (measured from CEJ to bottom of apex) (L_1), and depths of lingual and buccal bone defects (measured from CEJ to bottom of defect at the lingual and buccal sites) (L_2 and L_3). (b) Angle of separation between DL and M roots in the transverse section (α), angle of separation between DL and DB roots in the transverse section (β), and angle of separation between DB and M roots in the transverse section (γ). (c) Angle of separation between DB and M roots in the coronal section (δ). (d) Angle of separation between DL and DB roots in the sagittal section (ϵ). The scale sizes shown in figures are in mm. DL: distolingual; DB: distobuccal; M: mesial; CEJ: enamel-cemental junction.

teeth should be included in the first study. To adhere to the principle of having at least 10 events per variable in multiple linear regression analysis, a subgroup sample size of more than 80 was deemed necessary.

2.5 Data analysis

All data were presented as mean \pm standard deviation (SD) or number (percentage). Data were proofed for errors and analyzed by IBM SPSS Statistics software (Version 19.0). The total prevalence, bilateral and unilateral occurrences, and the correlation between right-side and left-side appearances of PMFM-DLRs were evaluated by Chi-squared test.

Spearman's correlation was used to examine the correlation between morphologic characteristics of DLRs and periodontal parameters such as CAL, PPD, GR, and FI at the distobuccal and distolingual sites of

PMFMs. The effects of DLRs on bone loss and periodontal parameters were analyzed by a multiple linear regression model. $P < 0.05$ was considered statistically significant.

3 Results

3.1 Prevalence of DLR

A total of 862 CBCT images were incorporated and 26 images were excluded due to duplication and unintelligibility. A total of 1497 PMFMs in 836 CBCT images were included in the analysis of DLR prevalence.

Among the 836 CBCT images, the patient-level prevalence of PMFM-DLRs was 29.4% ($n=246$, 136 males and 110 females). The prevalence of DLR in males and females was 30.7% (136/442) and 27.9% (110/394), respectively, with no significant difference ($P > 0.05$) (Table 1). In addition, the tooth-level prevalence of PMFM-DLRs was 26.3% (394/1497). A total of 747 teeth with 219 DLRs (29.3%) were from the right side and 750 teeth with 175 DLRs (23.3%) were from the left side.

Table 1 Patient-level and tooth-level prevalence of PMFM-DLRs

PMFM-DLR	Total number	Number with DLR	Prevalence (%)	<i>P</i> value
Patient-level				
Total CBCT images	836	246	29.4	0.367
Male	442	136	30.7	
Female	394	110	27.9	
Tooth-level				
Any lower first molar	1497	394	26.3	0.009
Left first molar	750	175	23.3	
Right first molar	747	219	29.3	

PMFM-DLR: distolingual root of the permanent mandibular first molar; CBCT: cone beam computed tomography.

Among 697 subjects with CBCT imaging bilateral PMFMs, 139 (19.94%) had bilateral DLRs and 78 (11.19%) had unilateral DLRs. A total of 62 subjects (8.89%) had a unilateral DLR on the right side, while 16 subjects (2.29%) were on the left side. The DLR was more frequent on the right side than on the left side in PMFM ($P < 0.001$) (Table 2).

3.2 Demographic data and clinical characteristics

The demographic data and clinical characteristics of 69 subjects with 103 DLRs were listed in Table 3.

Table 2 Bilateral and unilateral prevalence of PMFM-DLRs

PMFM-DLR	Number with DLR	Prevalence (%)	<i>P</i> value
Bilateral	139	19.94	<0.001
Unilateral	78	11.19	
Left+	16	2.29	
Right+	62	8.89	

A total of 697 subjects with CBCT imaging bilateral PMFMs were involved. PMFM-DLR: distolingual root of the permanent mandibular first molar; CBCT: cone beam computed tomography; Left+: presence of DLR in left mandibular molars; Right+: presence of DLR in right mandibular molars.

Table 3 Baseline clinical and periodontal parameters by variables (patient characteristics, tooth, and site)

Variable	Value
Patients ($n=69$)	
Age (years)	38.86±12.52
Female	29 (42.03%)
Diagnosis, chronic periodontitis	61 (88.41%)
Smoking	7 (10.14%)
Systemic diseases	
Hypertension	1 (1.45%)
Chronic hepatitis B	5 (7.25%)
Tooth: mandibular first molar ($n=103$)	
Location of molar side	
Left side	50 (48.54%)
Right side	53 (51.46%)
Tooth mobility	
0	72 (69.90%)
1	23 (22.33%)
2	5 (4.85%)
3	3 (2.91%)
Furcation involvement	32 (31.07%)
Site ($n=206$)	
Probing pocket depth (mm)	
Distobuccal site	2.86±1.44
Distolingual site	4.54±1.71
Gingival recession (mm)	
Distobuccal site	0.57±0.82
Distolingual site	0.71±0.99
Clinical attachment loss (mm)	
Distobuccal site	5.25±0.23
Distolingual site	3.44±0.55
Bleeding on probing	
Distobuccal site	54 (26.21%)
Distolingual site	78 (37.86%)
Buccal furcation	
I	34 (16.50%)
II	7 (3.40%)
III	6 (2.91%)
Lingual furcation	
I	32 (15.53%)
II	14 (6.80%)
III	6 (2.91%)

All data were presented as mean±standard deviation (SD) or number (percentage).

Among the 69 subjects, the average age was (38.86±12.52) years. Patients diagnosed with periodontitis counted 61 (88.41%). The proportion of smokers was 10.14%. Six subjects had systemic disease (one hypertension and five chronic hepatitis B). The periodontal clinical parameters, including CAL, PPD, GR, BOP, mobility, and FI, were also listed.

3.3 Morphologic analysis by CBCT

Detailed measurements for DLR detection and bone loss were presented in Table 4. The length of DLR was (9.58±1.23) mm (95% CI 6.7–12.8 mm). The length of root trunk was (3.47±0.58) mm (95% CI 2.2–5.4 mm). The angle of separation between distobuccal and mesial roots (δ) was 41.86°±8.13° (95% CI 21.3°–70.0°), while the angle of separation between distolingual and distobuccal roots (ϵ) was 84.18°±17.18° (95% CI 40.0°–121.0°).

Table 4 Detailed measurements for DLR and the bone loss by CBCT analysis

Tooth: mandibular first molar with DLR ($n=103$)	Value
Length of DLR (mm)	9.58±1.23
≤8 mm	10 (9.71%)
8–10 mm	63 (61.17%)
10–12 mm	27 (26.21%)
>12 mm	3 (2.91%)
Length of root trunk length (mm)	3.47±0.58
Angle of separation between DB and M roots (δ)	41.86°±8.13°
≤40°	47 (45.63%)
40°–90°	43 (41.75%)
>90°	13 (12.62%)
Angle of separation between DL and DB roots (ϵ)	84.18°±17.18°
≤75°	36 (34.95%)
75°–90°	26 (25.24%)
90°–105°	28 (27.18%)
>105°	13 (12.62%)
Buccal bone loss (mm)	3.03±2.26
Lingual bone loss (mm)	4.25±2.57

All data were presented as mean±standard deviation (SD) or number (percentage). DLR: distolingual root; CBCT: cone beam computed tomography; DB: distobuccal; M: mesial; DL: distolingual.

The lengths from 2 mm below enamel-cemental junction (CEJ) to the bottom of the defect at the lingual and buccal sites were measured as the depths of the lingual and buccal bone defects. The bone loss at buccal site was (3.03±2.26) mm, and the bone loss at the lingual site was (4.25±2.57) mm.

3.4 Correlation between bone loss and morphological features of PMFM-DLR

The correlations between bone loss and the morphological features of PMFM-DLR were listed in Table 5. The results showed a significant positive correlation between bone loss at the buccal site and the length of DLR ($r=0.260$, $P<0.01$). The angle of separation between distobuccal and mesial roots in the coronal section presented a significant positive correlation with PPD, CAL at the distolingual and buccal sites, and mobility. The angle of separation between distolingual and distobuccal roots in the sagittal section had a significant negative correlation with bone loss and FI at the buccal and lingual sites. Additionally, the results revealed a significant positive correlation between age and bone loss (lingual and buccal sites), CAL (distolingual, lingual, and buccal sites), and FI (lingual and buccal sites). A significant positive correlation was noted between bone loss at both sites and the periodontal clinical parameters, which included PPD, CAL, mobility, and FI (Table S1).

3.5 Multiple linear regression analysis of bone loss and morphological features of DLR

Multiple linear regression analysis was performed to further investigate the association between the bone loss and the morphological features of DLR (Table 6). The age and the angle of separation between distobuccal and mesial roots in the coronal and transverse sections were significantly associated with bone loss at the lingual site ($B=0.074$, $P<0.001$; $B=0.060$, $P=0.047$; $B=0.041$, $P=0.037$). The angle of separation between distolingual and mesial roots in the transverse section was negatively associated with bone loss at the lingual site ($B=-0.085$, $P=0.005$). Furthermore, the age was associated with bone loss at the buccal site ($B=0.054$, $P=0.002$), while the angle of separation between distolingual and distobuccal roots in the sagittal section was negatively associated with bone loss at the buccal site ($B=-0.023$, $P=0.064$).

3.6 Multiple linear regression analysis of CAL and morphological features of DLR

Multiple linear regression analysis was further performed to investigate the association between the CAL and the morphological features of DLR (Table 7). The CAL at the distolingual, lingual, and buccal sites

Table 5 Correlation analysis of bone loss and clinical parameters with the morphology of PMFM-DLR

Morphological feature	Bone loss		PPD			CAL			Mobility	FI	
	Buccal site	Lingual site	DL site	Lingual site	Buccal site	DL site	Lingual site	Buccal site		Buccal side	Lingual side
Basic information											
Smoking	0.051	-0.136	0.022	0.025	0.110	-0.048	-0.058	-0.010	-0.180	0.112	-0.038
Age	0.343**	0.427**	0.165	0.236*	0.069	0.252*	0.399**	0.259**	0.139	0.442**	0.449**
Gender	-0.080	0.108	0.109	0.095	-0.112	0.118	0.073	-0.061	-0.005	-0.054	0.117
Sagittal section											
Length of DLR	0.260**	0.089	-0.006	-0.054	0.034	-0.005	0.004	0.005	-0.189	-0.035	0.063
Length of root trunk	0.166	0.127	0.034	-0.013	0.038	0.042	-0.014	-0.091	-0.178	-0.107	-0.028
Angle of separation between DL and DB roots (ϵ)	-0.203*	-0.240*	-0.112	-0.107	-0.111	-0.139	-0.139	-0.096	-0.121	-0.245*	-0.226*
Coronal section											
Angle of separation between DB and M roots (δ)	-0.062	0.001	0.250*	0.117	0.238*	0.260**	0.105	0.249*	0.203*	0.073	0.091
Transverse section											
Angle of separation between DL and M roots (α)	-0.066	-0.170	-0.029	-0.073	-0.044	-0.098	-0.120	-0.083	-0.029	-0.021	-0.104
Angle of separation between DL and DB roots (β)	0.008	-0.146	-0.090	-0.008	-0.085	-0.067	-0.007	-0.029	-0.180	0.082	-0.082
Angle of separation between DB and M roots (γ)	-0.065	0.099	0.054	0.076	0.160	0.076	0.075	0.178	0.319**	0.001	0.198*

DLR: distolingual root; PMFM: permanent mandibular first molar; DL: distolingual; DB: distobuccal; M: mesial; PPD: probing pocket depth; CAL: clinical attachment loss; FI: furcation involvement. The number means correlation coefficient (*R*) and *P*-values are presented as **P*<0.05 and ***P*<0.01.

Table 6 Multiple linear regression analysis of bone loss and morphological features of DLR

Morphological feature	Bone loss (buccal site)			Bone loss (lingual site)		
	<i>B</i>	Standardized <i>B</i>	Significance (<i>P</i>)	<i>B</i>	Standardized <i>B</i>	Significance (<i>P</i>)
Constant	2.899		0.030	1.814		0.400
Ages	0.054	0.292	0.002	0.074	0.350	<0.001
Angle of separation between DL and DB roots in the sagittal section (ϵ)	-0.023	-0.176	0.064	-0.026	-0.176	0.057
Angle of separation between DB and M roots in the coronal section (δ)				0.060	0.190	0.047
Angle of separation between DL and M roots in the transverse section (α)				-0.085	-0.274	0.005
Angle of separation between DB and M roots in the transverse section (γ)				0.041	0.199	0.037
	$R^2=0.112, F=7.402$ $P=0.001$			$R^2=0.179, F=5.441$ $P<0.001$		

DLR: distolingual root; DL: distolingual; DB: distobuccal; M: mesial.

Table 7 Multiple linear regression analysis of CAL and morphological features of DLR

Morphological feature	CAL (distolingual site)			CAL (lingual site)			CAL (buccal site)		
	<i>B</i>	Standardized <i>B</i>	Significance (<i>P</i>)	<i>B</i>	Standardized <i>B</i>	Significance (<i>P</i>)	<i>B</i>	Standardized <i>B</i>	Significance (<i>P</i>)
Constant	0.945		0.499	0.919		0.496	-2.185		0.026
Age	0.042	0.244	0.011	0.056	0.344	<0.001	0.051	0.377	<0.001
Angle of separation between DL and M roots in the transverse section (α)	-0.049	-0.194	0.042	-0.046	-0.191	0.048			
Angle of separation between DB and M roots in the coronal section (δ)	0.100	0.387	<0.001	0.059	0.240	0.015	0.086	0.421	<0.001
	$R^2=0.146, F=6.817$ $P<0.001$			$R^2=0.126, F=5.902$ $P=0.001$			$R^2=0.240, F=17.084$ $P<0.001$		

CAL: clinical attachment loss; DLR: distolingual root; DL: distolingual; DB: distobuccal; M: mesial.

was significantly associated with the age and the angle of separation between distobuccal and mesial roots in the coronal section. Meanwhile, the angle of separation between distolingual and mesial roots in the transverse section was negatively associated with CAL at the distolingual and lingual sites.

4 Discussion

The present study revealed a relatively high prevalence of PMFM-DLR in the cohort representing the Eastern Chinese population, which was in accordance with previously published studies on Hong-kongese and Korean populations (Song et al., 2010; Ho et al., 2021). Through clinical epidemiology research, we can link clinical treatment and scientific research (Chen et al., 2023).

Correlation analysis and multiple linear regression analysis suggested that bone loss at the lingual site and CAL were negatively affected by the angle of separation between distolingual and mesial roots. The smaller the angle of separation between distolingual and mesial roots in the transverse section, that is, the DLR being closer to the center site, the more bone loss and CAL were found. We suspect that DLR closer to the center site may have a greater buccolingual root width, resulting in comparatively narrower bone housing. Previous research established that the existence of DLR was associated with larger buccolingual dimensions (Kim et al., 2013; Lee et al., 2016).

In addition, the presence of DLR may increase the difficulty of oral hygiene and result in plaque accumulation, leading to poor periodontal parameters. Huang et al. (2007) found a significantly greater magnitude of clinical periodontal parameters (PPD and CAL) at the distolingual site in mandibular molars with DLRs than in molars without DLRs in advanced periodontitis.

Multiple linear regression analysis also showed that bone loss at the lingual site and CAL were significantly influenced by the age and angle of separation between distobuccal and mesial roots in the coronal section. We further revealed that bone loss and CAL increased with age. These two parameters were associated with buccal furcation, which was consistent with previously published studies (Graetz et al., 2015; Dannewitz et al., 2016). The link between vertical attachment loss and FI has been demonstrated previously (Nibali et al., 2016; Tonetti et al., 2017).

In this study, CBCT was used to evaluate the morphological features of DLR and the bone loss in mandibular first molars. It can provide 3D images in the coronal, sagittal, and transverse sections, avoiding anatomical superimposition and geometric distortion in traditional radiographs. Although the presence of DLR can be detected on conventional radiographs with additional angled views (Fig. 1c). As a non-invasive tool, CBCT can aid the earlier detection of abnormal root morphology. The periodontal clinical parameters were also collected to assess the periodontal status of mandibular first molars.

No gender predilection was detected in PMFM-DLR, which is consistent with the findings in the population of Taiwan, China (Tu et al., 2009; Hsu et al., 2021). Nevertheless, Song et al. (2009) reported a significant gender predilection in males over females. Interestingly, in terms of topologic predilection, they indicated that PMFM-DLR was more likely on the right side than on the left side. It was also observed that bilateral symmetrical distribution was more prevalent than unilateral distribution, which was in accordance with the observations of some other scholars (Tu et al., 2007).

Nowadays, the utilization of artificial intelligence (AI) in dentistry is accelerating (Thurzo et al., 2022). AI models have shown a positive impact in assisting dental diagnosis. For example, the diagnosis of periodontal diseases using AI models has been broadly explored in the literature (Chen et al., 2018; Farhadian et al., 2020). CBCT is more suitable for more complex AI implementations to achieve different clinical purposes in dentistry (Woelber et al., 2018) and can also help dentists to achieve correct judgement for dental anomalies and minimize human error in the future.

However, there were some limitations in this study. Though all periodontal examiners were qualified periodontists and completed the routine periodontal assessments, they had not received standardized training in clinical periodontal examination procedures and calibration. Notably, the limited number of patients (i.e., relatively small sample size) may bring about insufficient statistical power to detect the correlation of the length of DLR and clinical outcomes. As a further shortcoming of this study, some mandibular first molars with DLRs were prematurely removed because of advanced periodontitis or imperfect root canal therapy. Thus, these molars could not be detected in CBCT analysis.

The results of this study indicated that the length of PMFM-DLR had no correlation with bone loss at the lingual site or the periodontal parameters. Nevertheless, the length of DLR was important to clinical decision-making. In some cases, we found that the root length was less than half that of the distobuccal root, with curved root shape in DLR (Fig. 3). The presence of DLR can cause pain, swelling, and infection or recession of the gingiva at the lingual site (Figs. 1a and 1b). In this situation, it could be beneficial to obtain a

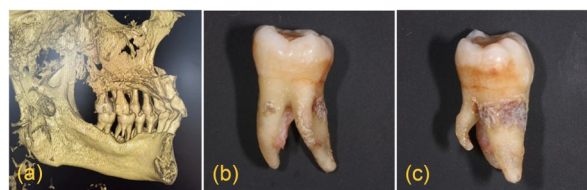

Fig. 3 Mandibular first molar with a small and curved distolingual root (DLR). (a) Three-dimensional (3D) reconstruction of mandibular first molars with DLR. (b, c) Lingual and distal views of an extracted mandibular first molar with a small and curved DLR.

better tooth morphology and bony housing through periodontal operation, including the amputation of DLR. For asymptomatic DLR, dentists need to consider and evaluate the time of periodontal surgery and root canal therapy.

5 Conclusions

In this work, a significant correlation was found between bone loss and the bifurcation angle of DLR. Besides, the periodontal PPD and CAL were related to the bifurcation angle of DLR. Our findings indicated that the presence of DLR may contribute to the loss of alveolar bone in the mandibular first molars, providing critical information for the more accurate clinical diagnosis and proper management of PMFM-DLR.

Data availability statement

The datasets used and analyzed during the study are available from the corresponding author upon reasonable request.

Acknowledgments

This work was supported by the Key R&D Program of Zhejiang Province (No. 2022C03088), the National Natural Science Foundation of China (Nos. 82170953, 82001046, and 82203345), the Science Fund for Distinguished Young Scholars of Zhejiang Province (No. LR23H140001), and the Scientific Research Fund of Zhejiang Provincial Education Department (No. Y202147347), China.

Author contributions

Feifei MAO contributed to the study design, data analysis, and writing the manuscript. Meng WANG contributed to the conception of the study and data acquisition, and assisted in drafting the manuscript. Shuai ZHOU contributed to the conception of the study and data acquisition. Yan ZHAO

involved in the investigation and methodology of the study. Jiaping HUANG critically revised the manuscript. Fengying YIN and Haiping YANG participated in editing the manuscript. Pei-hui DING provided supervision for the study, contributed to the conception and design of the study, acquired funding, and participated in reviewing and editing the manuscript. All authors have read and approved the final manuscript, and therefore, have full access to all the data in the study and take responsibility for the integrity and security of the data.

Compliance with ethics guidelines

Feifei MAO, Meng WANG, Shuai ZHOU, Yan ZHAO, Jiaping HUANG, Fengying YIN, Haiping YANG, and Pei-hui DING declare no conflicts of interest.

The study protocol has been reviewed and approved by the Ethics Committee of the Stomatology Hospital, Zhejiang University School of Medicine (No. 2023-031) and registered in Chinese Clinical Trial Registry (No. ChiCTR2300074445).

References

- Abella F, Patel S, Durán-Sindreu F, et al., 2012. Mandibular first molars with disto-lingual roots: review and clinical management. *Int Endod J*, 45(11):963-978. <https://doi.org/10.1111/j.1365-2591.2012.02075.x>
- Aung NM, Myint KK, 2022. Three-rooted permanent mandibular first molars: a meta-analysis of prevalence. *Int J Dent*, 2022:9411076. <https://doi.org/10.1155/2022/9411076>
- Blanchard SB, Derderian GM, Averitt TR, et al., 2012. Cervical enamel projections and associated pouch-like opening in mandibular furcations. *J Periodontol*, 83(2):198-203. <https://doi.org/10.1902/jop.2011.110088>
- Chandra SS, Chandra S, Shankar P, et al., 2011. Prevalence of radix entomolaris in mandibular permanent first molars: a study in a South Indian population. *Oral Surg Oral Med Oral Pathol Oral Radiol Endod*, 112(3):e77-e82. <https://doi.org/10.1016/j.tripleo.2011.02.016>
- Chen QM, Wang YH, Shuai J, 2023. Current status and future prospects of stomatology research. *J Zhejiang Univ-Sci B (Biomed & Biotechnol)*, 24(10):853-867. <https://doi.org/10.1631/jzus.B2200702>
- Chen WP, Chang SH, Tang CY, et al., 2018. Composition analysis and feature selection of the oral microbiota associated with periodontal disease. *Biomed Res Int*, 2018:3130607. <https://doi.org/10.1155/2018/3130607>
- Curzon MEJ, 1973. Three-rooted mandibular permanent molars in English Caucasians. *J Dent Res*, 52(1):181. <https://doi.org/10.1177/00220345730520011901>
- Dannewitz B, Zeidler A, Hüsing J, et al., 2016. Loss of molars in periodontally treated patients: results 10 years and more after active periodontal therapy. *J Clin Periodontol*, 43(1):53-62. <https://doi.org/10.1111/jcpe.12488>
- de Moor RJG, Deroose CAJG, Calberson FLG, 2004. The radix entomolaris in mandibular first molars: an endodontic challenge. *Int Endod J*, 37(11):789-799. <https://doi.org/10.1111/j.1365-2591.2004.00870.x>
- Farhadian M, Shokouhi P, Torkzaban P, 2020. A decision support system based on support vector machine for diagnosis of periodontal disease. *BMC Res Notes*, 13:337. <https://doi.org/10.1186/s13104-020-05180-5>
- Goldstein AR, 1979. Enamel pearls as a contributing factor in periodontal breakdown. *J Am Dent Assoc*, 99(2):210-211. <https://doi.org/10.14219/jada.archive.1979.0258>
- Graetz C, Schützhold S, Plaumann A, et al., 2015. Prognostic factors for the loss of molars – an 18-years retrospective cohort study. *J Clin Periodontol*, 42(10):943-950. <https://doi.org/10.1111/jcpe.12460>
- Gu YC, Lu Q, Wang HG, et al., 2010. Root canal morphology of permanent three-rooted mandibular first molars—Part I: pulp floor and root canal system. *J Endod*, 36(6):990-994. <https://doi.org/10.1016/j.joen.2010.02.030>
- Hamp SE, Nyman S, Lindhe J, 1975. Periodontal treatment of multi rooted teeth. *J Clin Periodontol*, 2(3):126-135. <https://doi.org/10.1111/j.1600-051X.1975.tb01734.x>
- Ho DKL, Wong JHL, Pelekos G, et al., 2021. Prevalence and morphological characteristics of disto-lingual roots in mandibular first molars: a cone beam CT study with diagnostic and therapeutic implications. *Clin Oral Invest*, 25(6):4023-4030. <https://doi.org/10.1007/s00784-020-03733-3>
- Hou GL, Tsai CC, 1993. Relationship between palatoradicular grooves and localized periodontitis. *J Clin Periodontol*, 20(9):678-682. <https://doi.org/10.1111/j.1600-051x.1993.tb00715.x>
- Hsu CL, Huang JE, Chen HL, et al., 2021. The relationship of the occurrence between three-rooted deciduous mandibular second molars and three-rooted permanent mandibular first molars in children. *J Dent Sci*, 16(2):580-585. <https://doi.org/10.1016/j.jds.2020.11.008>
- Huang RY, Lin CD, Lee MS, et al., 2007. Mandibular disto-lingual root: a consideration in periodontal therapy. *J Periodontol*, 78(8):1485-1490. <https://doi.org/10.1902/jop.2007.060419>
- Huang RY, Cheng WC, Chen CJ, et al., 2010. Three-dimensional analysis of the root morphology of mandibular first molars with distolingual roots. *Int Endod J*, 43(6):478-484. <https://doi.org/10.1111/j.1365-2591.2010.01702.x>
- Jang JK, Peters OA, Lee W, et al., 2013. Incidence of three roots and/or four root canals in the permanent mandibular first molars in a Korean sub-population. *Clin Oral Invest*, 17(1):105-111. <https://doi.org/10.1007/s00784-012-0687-3>
- Kim KR, Song JS, Kim SO, et al., 2013. Morphological changes in the crown of mandibular molars with an additional distolingual root. *Arch Oral Biol*, 58(3):248-253. <https://doi.org/10.1016/j.archoralbio.2012.07.015>
- Lee WC, Ni CW, Lin FG, et al., 2016. Crown morphology of the mandibular first molars with distolingual roots. *J Dent Sci*, 11(2):189-195. <https://doi.org/10.1016/j.jds.2015.07.007>
- Lin ZT, Hu QG, Wang TM, et al., 2014. Use of CBCT to investigate the root canal morphology of mandibular incisors. *Surg Radiol Anat*, 36(9):877-882. <https://doi.org/10.1007/s00276-014-1267-9>

- Misch KA, Yi ES, Sarment DP, 2006. Accuracy of cone beam computed tomography for periodontal defect measurements. *J Periodontol*, 77(7):1261-1266. <https://doi.org/10.1902/jop.2006.050367>
- Mol A, Balasundaram A, 2008. *In vitro* cone beam computed tomography imaging of periodontal bone. *Dentomaxillofac Radiol*, 37(6):319-324. <https://doi.org/10.1259/dmfr/26475758>
- Nibali L, Zavattini A, Nagata K, et al., 2016. Tooth loss in molars with and without furcation involvement – a systematic review and meta-analysis. *J Clin Periodontol*, 43(2):156-166. <https://doi.org/10.1111/jcpe.12497>
- Sharma P, Cockwell P, Dietrich T, et al., 2017. Influence of Successful Periodontal Intervention in RENal Disease (INSPIRED): study protocol for a randomised controlled pilot clinical trial. *Trials*, 18:535. <https://doi.org/10.1186/s13063-017-2236-5>
- Song JS, Kim SO, Choi BJ, et al., 2009. Incidence and relationship of an additional root in the mandibular first permanent molar and primary molars. *Oral Surg Oral Med Oral Pathol Oral Radiol Endod*, 107(1):e56-e60. <https://doi.org/10.1016/j.tripleo.2008.09.004>
- Song JS, Choi HJ, Jung IY, et al., 2010. The prevalence and morphologic classification of distolingual roots in the mandibular molars in a Korean population. *J Endod*, 36(4): 653-657. <https://doi.org/10.1016/j.joen.2009.10.007>
- Sperber GH, Moreau JL, 1998. Study of the number of roots and canals in Senegalese first permanent mandibular molars. *Int Endod J*, 31(2):117-122. <https://doi.org/10.1046/j.1365-2591.1998.00126.x>
- Thurzo A, Urbanová W, Novák B, et al., 2022. Where is the artificial intelligence applied in dentistry? Systematic review and literature analysis. *Healthcare*, 10(7):1269. <https://doi.org/10.3390/healthcare10071269>
- Tu MG, Tsai CC, Jou MJ, et al., 2007. Prevalence of three-rooted mandibular first molars among Taiwanese individuals. *J Endod*, 33(10):1163-1166. <https://doi.org/10.1016/j.joen.2007.07.020>
- Tu MG, Huang HL, Hsue SS, et al., 2009. Detection of permanent three-rooted mandibular first molars by cone-beam computed tomography imaging in Taiwanese individuals. *J Endod*, 35(4):503-507. <https://doi.org/10.1016/j.joen.2008.12.013>
- Tonetti MS, Christiansen AL, Cortellini P, 2017. Vertical subclassification predicts survival of molars with class II furcation involvement during supportive periodontal care. *J Clin Periodontol*, 44(11):1140-1144. <https://doi.org/10.1111/jcpe.12789>
- Turner CG II, 1971. Three-rooted mandibular first permanent molars and the question of American Indian origins. *Am J Phys Anthropol*, 34(2):229-241. <https://doi.org/10.1002/ajpa.1330340207>
- Woelber JP, Fleiner J, Rau J, et al., 2018. Accuracy and usefulness of CBCT in periodontology: a systematic review of the literature. *Int J Periodontics Restorative Dent*, 38(2): 289-297. <https://doi.org/10.11607/prd.2751>

Supplementary information

Table S1