Journal of Zhejiang University-Science B (Biomedicine & Biotechnology)

Cite this as:

Jin-ming CHEN, Jin LV, Kai MA, Jing YAN, 2014. Assessment of internal mammary artery injury after blunt chest trauma: a literature review. J. Zhejiang Univ.-Sci. B (Biomed. & Biotechnol.), 15(10):864-869. [doi:10.1631/jzus.B1400098]

Assessment of internal mammary artery injury after blunt chest trauma

Key words:

Internal mammary artery injury,
Blunt chest trauma,
Bleeding,
Treatment

Research Summary

This paper mainly focused on the occurrence, bleeding, and treatment of internal mammary artery injury after blunt chest trauma. We found as follow:

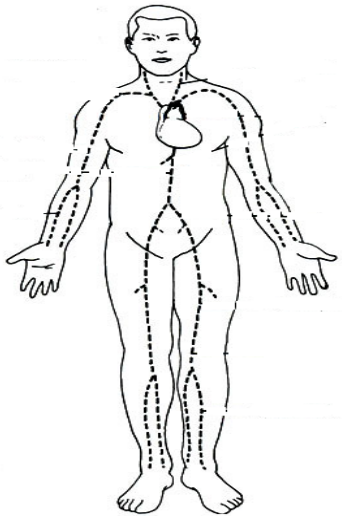

- **There was a predominant incidence in males and on the left side.**

- **Blunt trauma to the internal mammary artery injury can cause anterior mediastinal hematoma, hemothorax, pseudoaneurysm, arteriovenous fistula, and extra-pleural hematoma.**



Research Summary

Of the 49 patients studied, 20 underwent embolization, 22 underwent surgical operation, four were managed by clinical observation, and three had undescribed treatment.

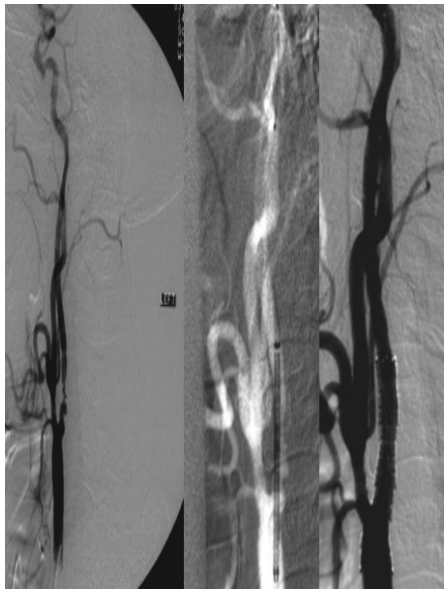





Innovation points

We first summarized internal mammary artery injury after blunt chest trauma :

- Different parts and extents of IMA injury, adjacent vein injury, as well as the integrity of the pleura determined differences in bleeding modality.
- Prompt diagnosis, complete hemostasis, aggressive resuscitation, and multidisciplinary teams are recommended for patients with IMA injury.
- There was a high risk in males and on the left side.