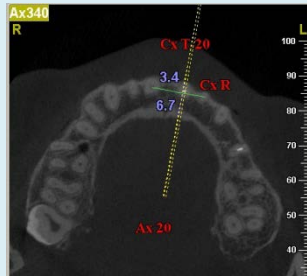


Cite this as: Bei Li, Yao Wang, 2014. Contour changes in human alveolar bone following tooth extraction of the maxillary central incisor. *Journal of Zhejiang University-SCIENCE B (Biomedicine & Biotechnology)*, **15**(12):1064-1071. [doi:10.1631/jzus.B1400119]

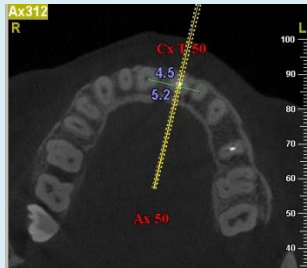
# Contour changes in human alveolar bone following tooth extraction of the maxillary central incisor

**Key words:** Cone-beam computed tomography, Alveolar bone contour, Maxillary central incisor

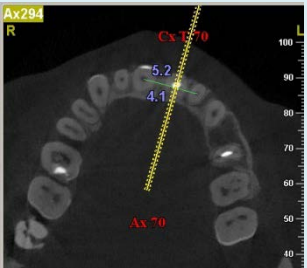
## Measurements before tooth extraction



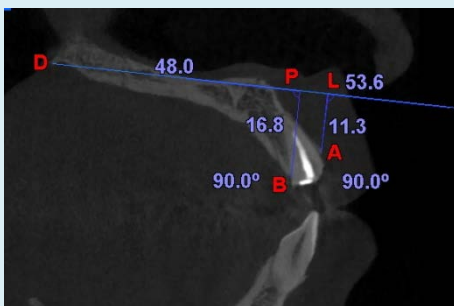
alveolar bone widths of T were measured at Cx T-20 on Ax20



alveolar bone widths of T were measured at Cx T-50 on Ax50

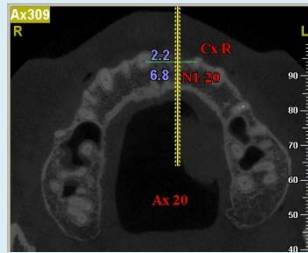


alveolar bone widths of T were measured at Cx T-70 on Ax70

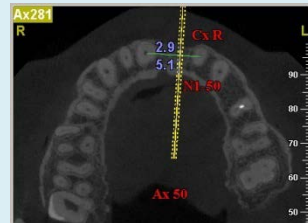

Relevant distances of T were measured on Cx T-50

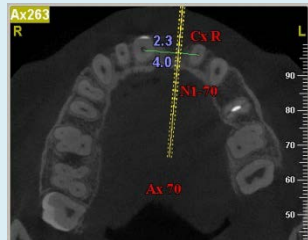
## Measurements after tooth extraction



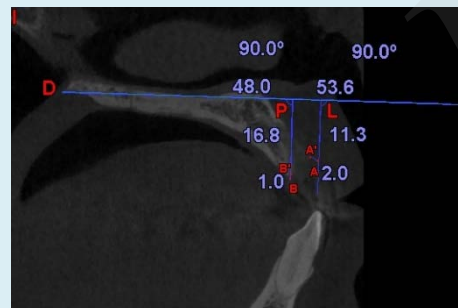
alveolar bone widths of T were measured at N1-20 oriented site on Ax20



alveolar bone widths of T were measured at N1-50 oriented site on Ax50



alveolar bone widths of T were measured at N1-70 oriented site on Ax70



Relevant distances of T were transferred on N1-50 oriented sagittal slice

- The purpose of this study was to apply cone-beam computed tomography (CBCT) to observe contour changes in human alveolar bone after tooth extraction of the maxillary central incisor, and to provide original morphological evidence for aesthetic implant treatment in the maxillary anterior area.
- Patients were recruited who had two CBCT scans, one taken before and one taken 3 months after tooth extraction of maxillary central incisor (test tooth T). A fixed anatomic reference point was used to orient the starting axial slice of the two scans. Alveolar bone widths were measured on three axial slices which represented the deep, middle and shallow layer of the socket of T on two CBCT scans. So were the heights of alveolar bone on labial and palatal sides.
- After 3 months of extraction of the maxillary central incisor, horizontal resorption of labial alveolar bone occurred at different depths of the extraction site – the further towards the alveolar ridge, the more resorption occurred. Vertical resorption occurred on both labial and palatal sides, the resorption was more pronounced at the labial bone wall than the palatal bone wall.