Cite this as: Jia-fei YAN, Tian-tao KUANG, Da-yong JI, Xiao-wu XU, Dan-song WANG, Ren-chao ZHANG, Wei-wei JIN, Yi-ping MOU, Wen-hui LOU, 2015. Laparoscopic versus open distal pancreatectomy for benign or premalignant pancreatic neoplasms: a two-center comparative study. *Journal of Zhejiang University-Science B (Biomedicine & Biotechnology)*. **16**(7):573-579. [doi:10.1631/jzus.B1400257]

Laparoscopic Versus Open Distal Pancreatectomy for Benign or Premalignant Pancreatic Neoplasms: A Two-Center Comparative Study

JZUS-B

Key words: Laparoscopy, Distal pancreatic resection, Pancreatic neoplasm, Splenic preservation, Pancreatic benign tumors

Research Summary

The treatment for pancreatic body and tail neoplasms

Laparoscopic distal pancreatectomy

LDP(45 cases)



V.S.

Open distal pancreatectomy

ODP(46 cases)

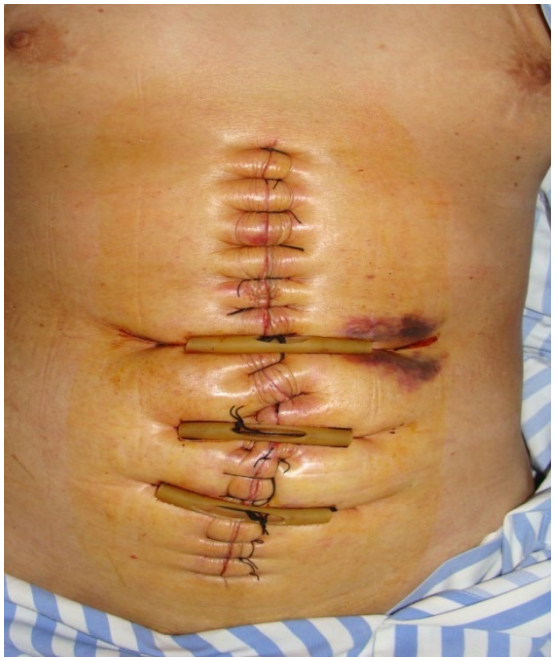

Innovation points

- All the pancreatic lesions in the two groups were benign or low grade malignant.
- The LDP and ODP were done by two separate surgeon teams in two hospital.
- The high rate of splenic conservation in the LDP group .

IZUS-B

Innovation points

- **lower blood loss (LDP 122.6±61.1 ml vs ODP 203.1±84.8 ml)**
- **lower post-operative complication (LDP 26.7% vs ODP 43.5%)**
- **shorter hospital stay (LDP 7.9±3.8 day vs ODP 11.9±5.8 day)**
- **equal pancreatic fistula rate (LDP 15.6% vs ODP19.6%)**



LDP is safe and effective for pancreatic neoplasms, featuring lower blood loss and substantially faster recovery.