Cite this as: Chen XIE, Xiu-yi LI, Hong-guang CUI, 2015. Potential candidate cells for constructing tissue-engineered lacrimal duct epithelium: a histological and cytological study in rabbits. *Journal of Zhejiang University-Science B (Biomedicine & Biotechnology)*, **16**(11):904-913. [doi:10.1631/jzus.B1500115]

Potential candidate cells for constructing tissue-engineered lacrimal duct epithelium: a histological and cytological study in rabbits

Key words: Conjunctival epithelial cells; Lacrimal duct epithelial cells; Tissue engineering; Cytokeratin; Mucin; Proliferating cell nuclear antigen

Research Summary

This study mainly focused on characterizing the potential candidate conjunctival epithelial cells in different areas for constructing tissue-engineered lacrimal duct epithelium:

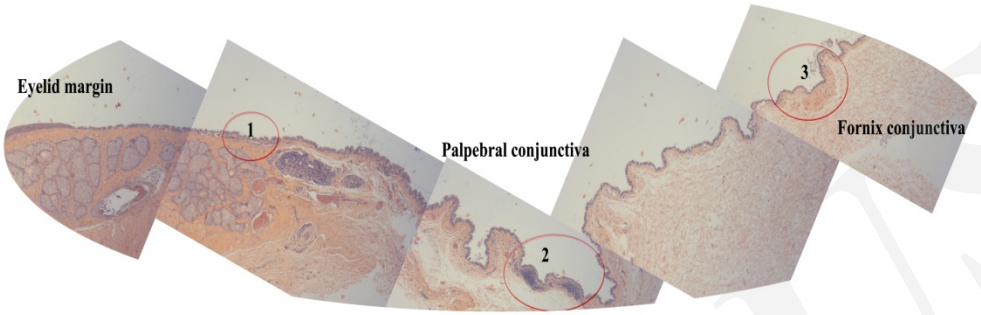



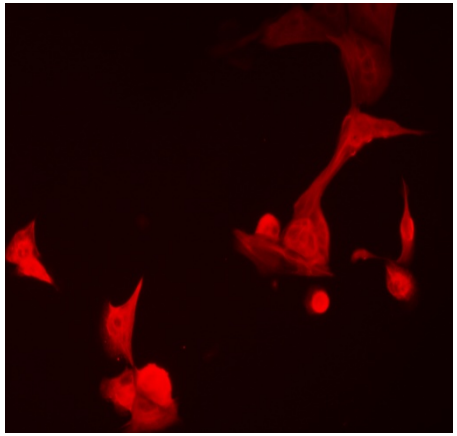

- **Histological evaluation of the conjunctiva and lacrimal duct tissue**
- **Electron microscopy of conjunctiva and lacrimal duct tissue**
- **Isolated epithelial cells identification**

Innovation points

●Highly proliferative conjunctival epithelial cells concentrated in a dome structure of the posterior palpebral conjunctiva.

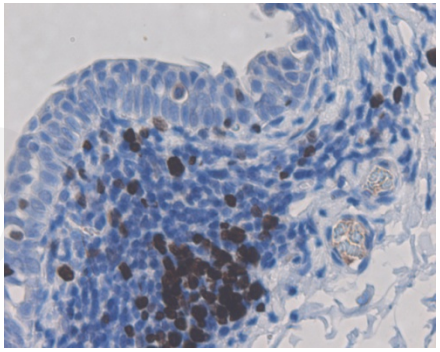

●Typical goblet cells discharging mucin granules found in the posterior palpebral and fornix conjunctiva



●The epithelial cells from the palpebral conjunctiva showed similar proliferative rate with the lacrimal duct

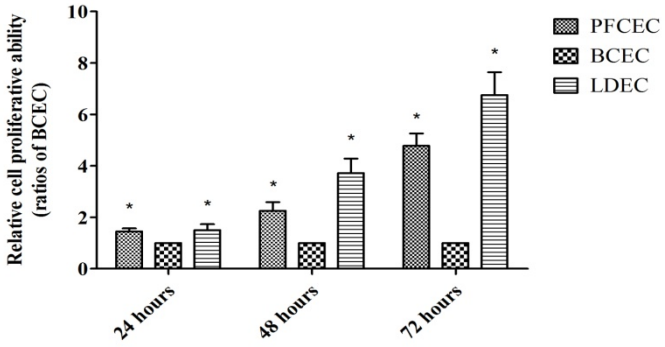

Innovation points

A series of figures were generated to demonstrate the core contents of this study:

Figure 1｜ Histologic observation of epithelium at eyelid margin, conjunctiva and lacrimal duct with light microscopy.

Figure 2｜ Observation of epithelium at eyelid margin, conjunctiva and lacrimal duct with electron microscopy.

Figure 3｜ Light microscopy and immunocytochemical evaluation of isolated epithelial cells

Figure 4｜ Proliferative ability and PCNA expression of cultured palpebral and fornical conjunctival epithelial cells (PFCECs), bulbar conjunctival epithelial cells (BCECs) and lacrimal duct epithelial cells (LDECs).

IZUS-B