Cite this as: Shi-cheng YU, Hai-yang WU, Wei WANG, Li-wei XU, Guo-qing DING, Zhi-gen ZHANG, Gong-hui LI, 2016. High-pressure balloon dilation for male anterior urethral stricture: single-center experience. *Journal of Zhejiang University-Science B (Biomedicine & Biotechnology)*. **17**(9):722-727. http://dx.doi.org/10.1631/jzus.B1600096

High-pressure balloon dilation for male anterior urethral stricture: single-center experience

Key words: Urethral stricture, High-pressure balloon dilation, Urethrotomy

From January 2009 to December 2012, a total of 31 patients with anterior urethral strictures underwent high-pressure balloon dilation (HPBD), while another 25 cases were treated by direct vision internal urethrotomy (DVIU).

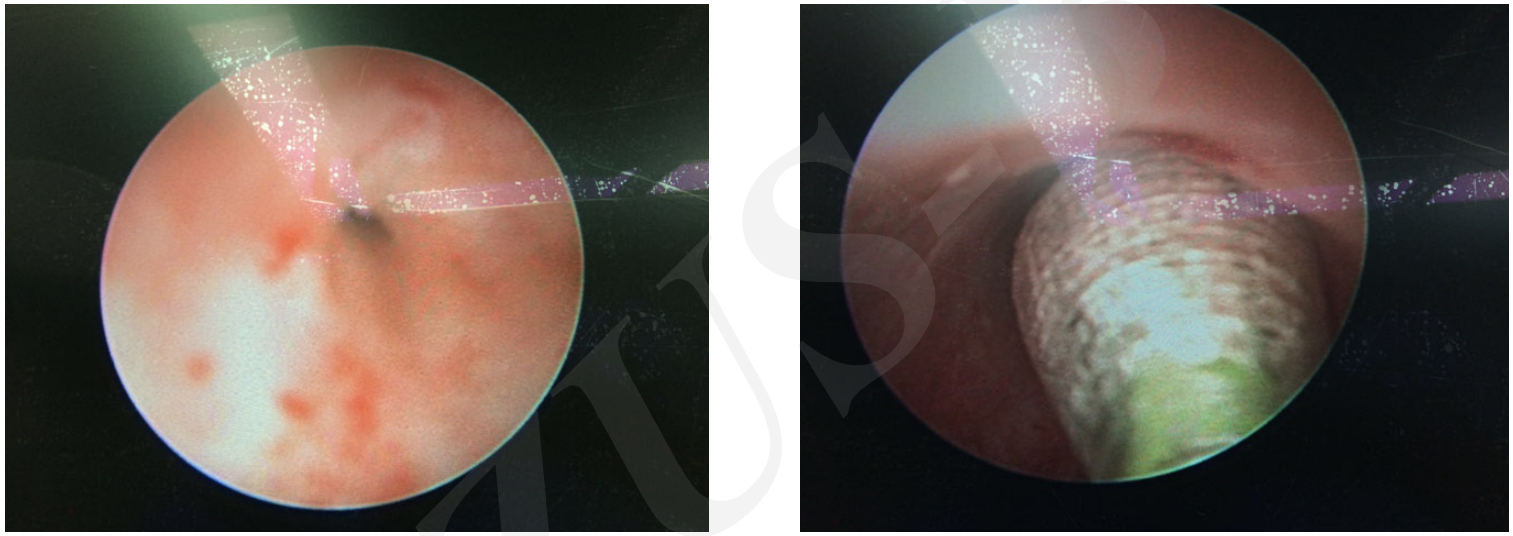

A B

(a) The appearance of urethral stricture at the beginning of the HPBD procedure. **(b)** The high pressure balloon catheter was inserted through the stricture segment over the guide wire.

A

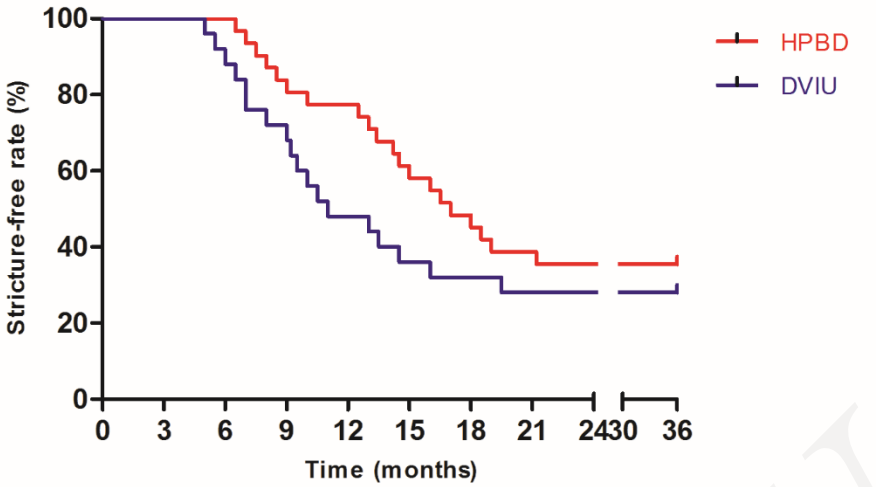

B

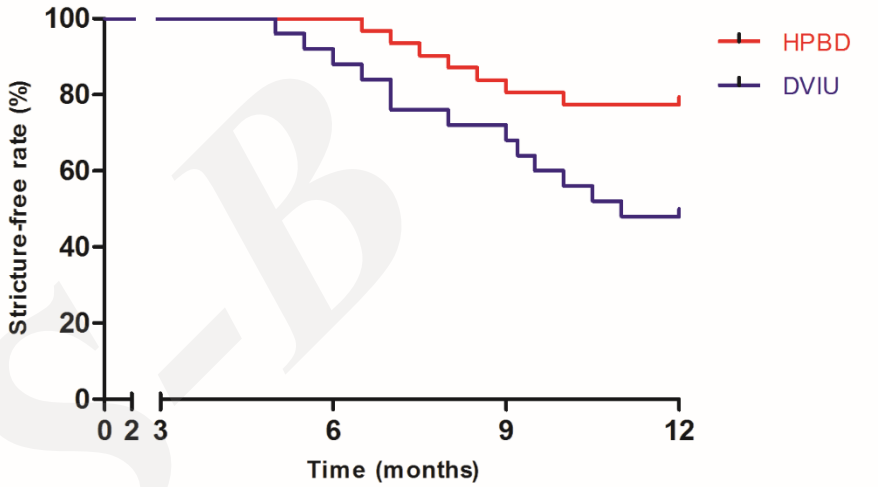

Kaplan-Meier curves predicting stricture-free rate after HPBD and DVIU: **(A)** Survival analysis demonstrated no significant difference at 36 months (p=0.21). **(B)** Survival analysis showed significantly higher stricture-free rate in the HPBD group at 12 months (p=0.02).

JKUS-B

Conclusion

HPBD might be an alternative for the treatment modality of anterior urethral stricture disease.

JZUS-B