Cite this as: Liu-xin CAI, Fang-qiang WEI, Yi-chen YU, Xiu-jun CAI, 2016. Can retrohepatic tunnel be quickly and easily established for laparoscopic liver hanging maneuver by Goldfinger dissector in laparoscopic right hepatectomy? *Journal of Zhejiang University-Science B (Biomedicine & Biotechnology).* **17**(9): 712-721.
http://dx.doi.org/10.1631/jzus.B1600180

Can retrohepatic tunnel be quickly and easily established for laparoscopic liver hanging maneuver by Goldfinger dissector in laparoscopic right hepatectomy?

Key words: Retrohepatic tunnel, Liver hanging maneuver, Goldfinger dissector, Laparoscopic right hepatectomy

Research Summary

This article mainly focused how to quickly and easily establish retrohepatic tunnel (RT) for laparoscopic liver hanging maneuver (LHM) in laparoscopic right hepatectomy(LRH) and reported employment of the Goldfinger dissector to create a total RT for the first time . The key aspects including:



- **Create a five-step strategy with the Goldfinger dissector**
- **Establishment of RT**
- **Achievement of laparoscopic LHM**
- **Achievement of LRH**

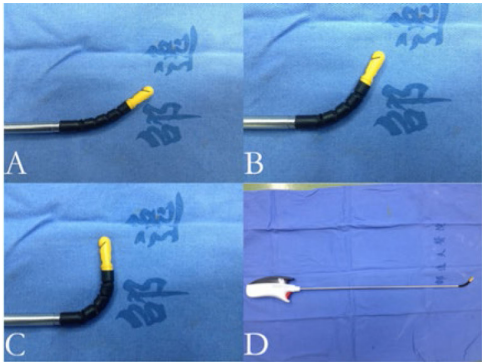

JZUS-B

Innovation points

- **Introduction** of the Goldfinger dissector to create a five-step strategy

- **Emphasis** of the newly established technique to create a total RT under laparoscope for laparoscopic LHM in LRH

- **Summary** of recent studies regarding LRH with the use of LHM or not.

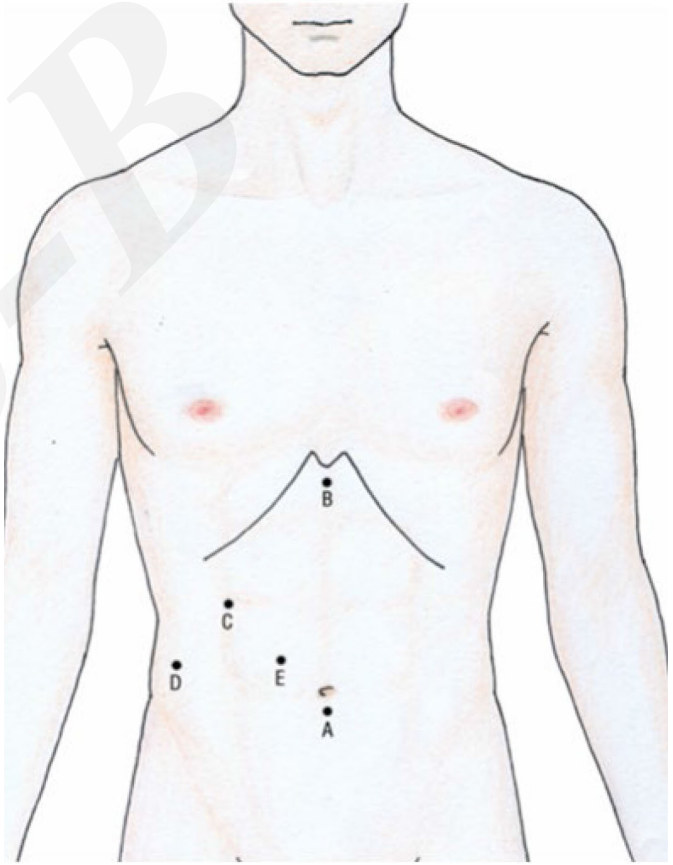

Figure 4

Innovation points

A series of comprehensive figures were generated to summarize the newly established and detailed technique to create a total RT under laparoscope for laparoscopic LHM in LRH

Figure 1 | Presentation of the Goldfinger dissector

Figure 2 | Port sites for laparoscopic right hepatectomy.

Figure 3 | Establishing the caudal portion of the retrohepatic tunnel (cad-RT).

Figure 4 | Establishing the cranial portion of the retrohepatic tunnel (cra-RT).

Figure 5 | A 3-0 leading Vicryl was passed through the whole retrohepatic tunnel (RT).

Figure 6 | Parenchymal transection of the anterior inferior part of the median hepatic fissure.

JZUS-B

Innovation points

A series of comprehensive figures were generated to summarize the newly established and detailed technique to create a total RT under laparoscope for laparoscopic LHM in LRH

Figure S1 | Establishing the initial caudal portion of the retrohepatic tunnel (cad-RT).

Figure S2 | Establishing the median portion of the retrohepatic tunnel (med-RT).

Figure S3 | Establishing the total retrohepatic tunnel (RT).

Figure S4 | Placement of the hanging tape through the whole retrohepatic tunnel (RT).

Figure S5 | Parenchymal transection of the median hepatic fissure (MHF).

Figure S6 | Achievement of hemostasis after removal of the specimen.

JZUS-B