Cite this as: Chun-xi WANG, Shu-li GUO, Li-na HAN, 2017. Successful treatment of accessory breast cancer with endocrine therapy. *Journal of Zhejiang University-Science B (Biomedicine & Biotechnology),* 18(1):70-75.
http://dx.doi.org/10.1631/jzus.B1600220

Successful treatment of accessory breast cancer with endocrine therapy

Key words: Accessory breast cancer, Aged man, Endocrine therapy

Abstract

Accessory breasts cancer in males are extremely rare. The 87-year-old male patient reported in this paper was diagnosed with an accessory breast cancer. Having undergone successful resection and postoperative adjuvant endocrine therapy, he was the oldest male patient with an accessory breast cancer reported in the Chinese Hospital Knowledge Database and PubMed literature from 1975 to 2015.

JZUSB

Results



Fig. 1. Delineation of surgical resection before operation.

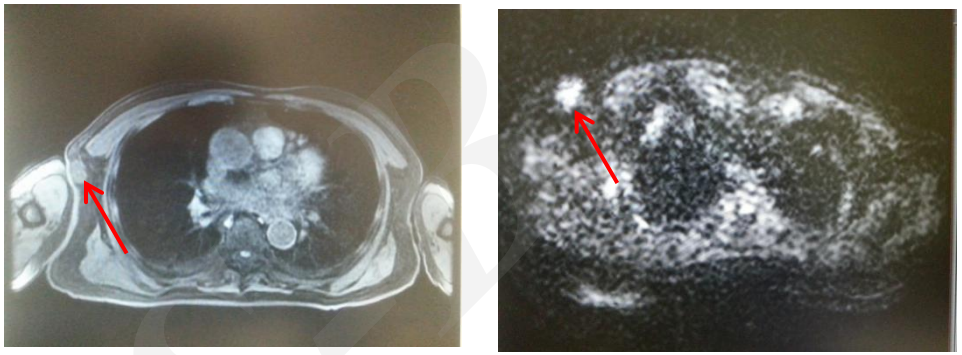

Fig. 2 MRI findings of the breast.

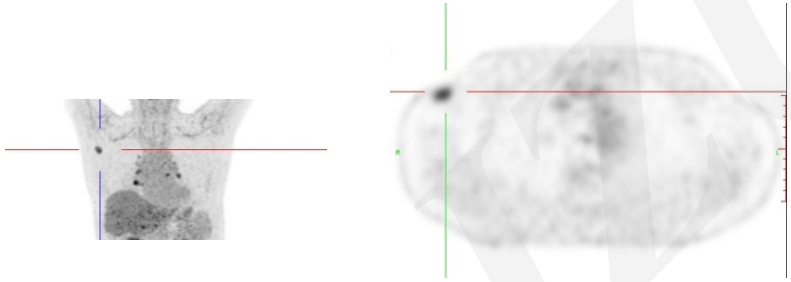

Fig. 3 PET-CT findings

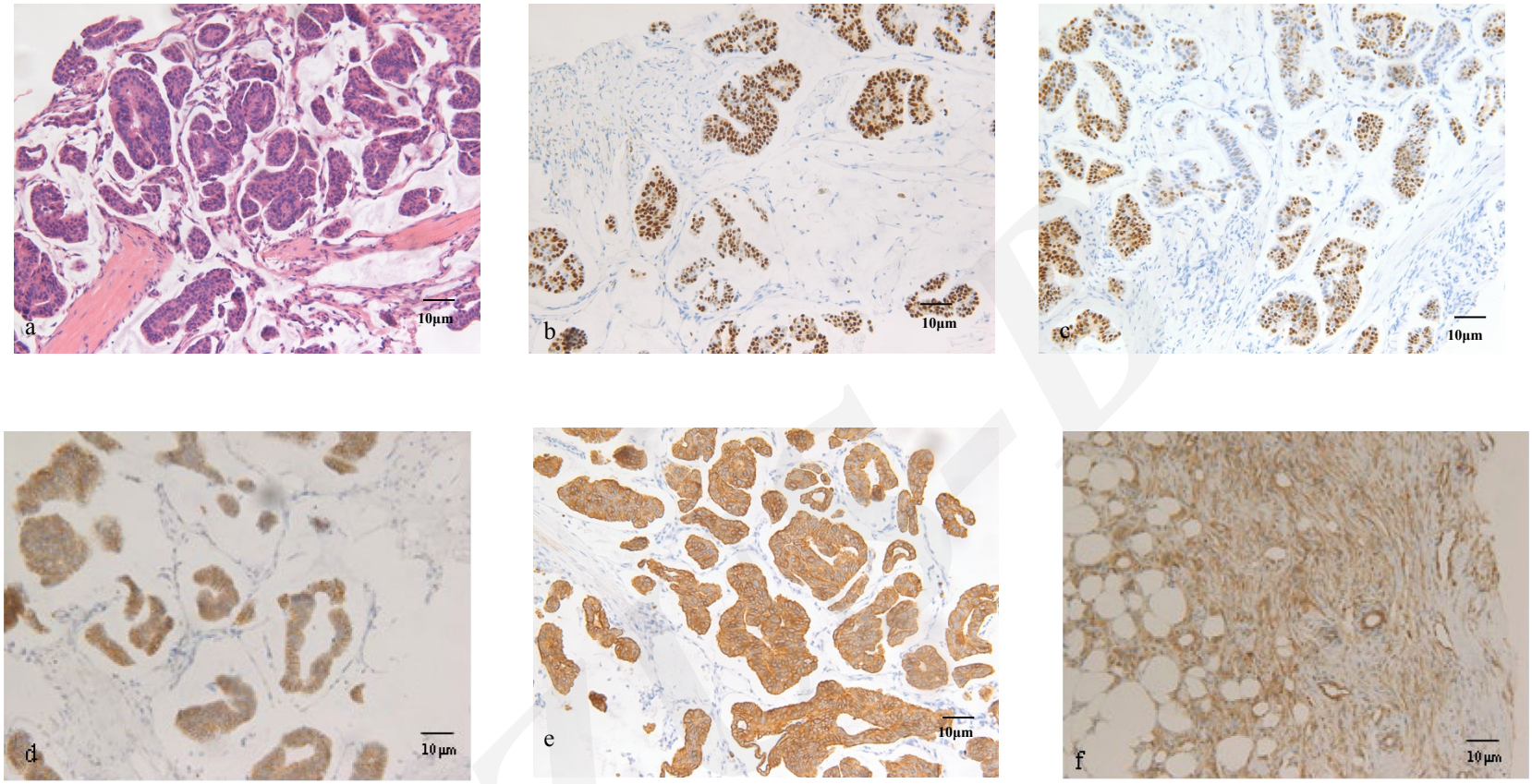

Fig. 4 Pathological images before operation.
(a) HE staining ×20.(b–f) immunohistochemical staining results:
(b) ER (+, ＞75%) ×20; (c) PR (+, ＞75%) ×20; (d) HER-2 (2+) ×20;
(e) CK7 (+) ×20; (f) p120 (film +) ×20.

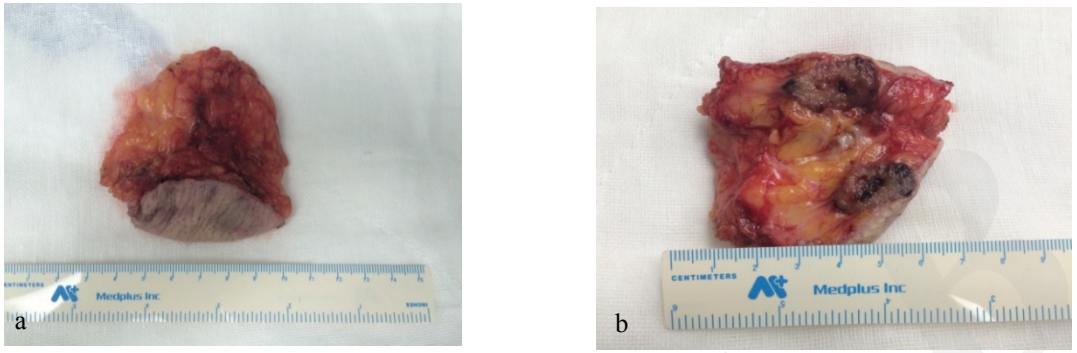

Fig. 5 Cut-down accessory breast cancer.
(a) Cut-down accessory breast cancer. (b) Opened accessory breast cancer.

JZUS-B

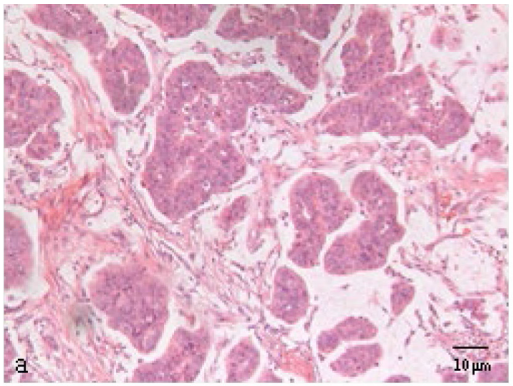
a
10 µm

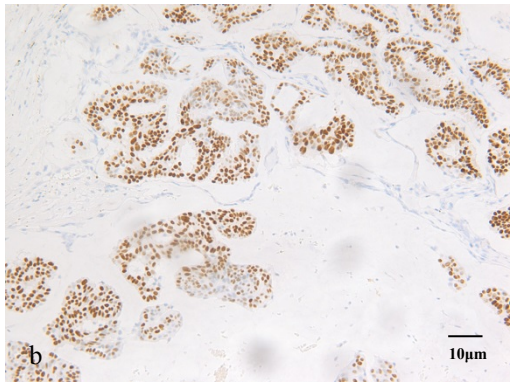
b
10µm

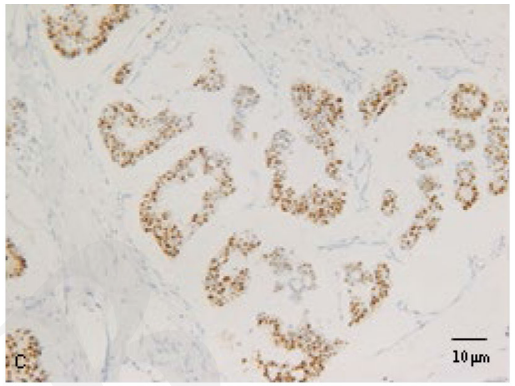
c
10 µm

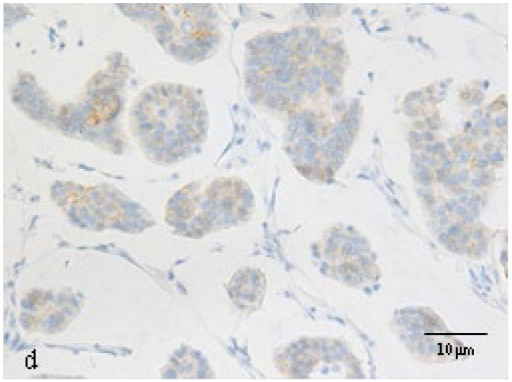
d
10 µm

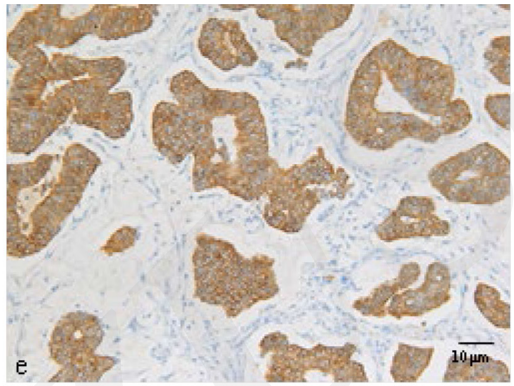
e
10 µm

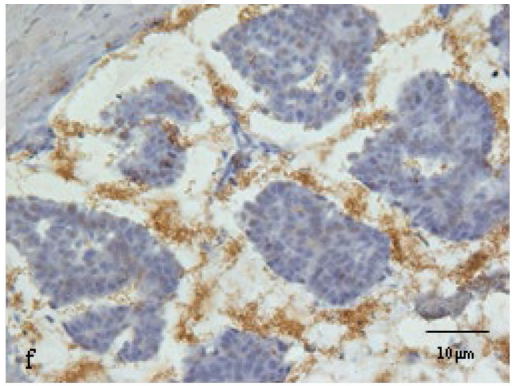
f
10 µm

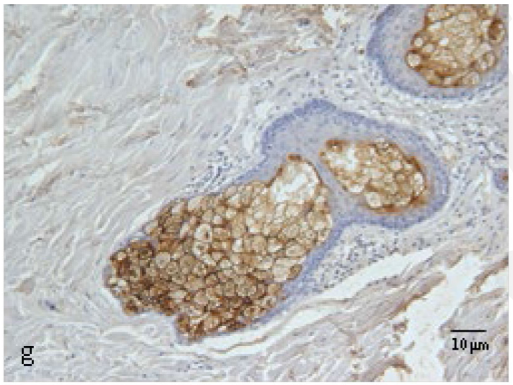
g
10 µm

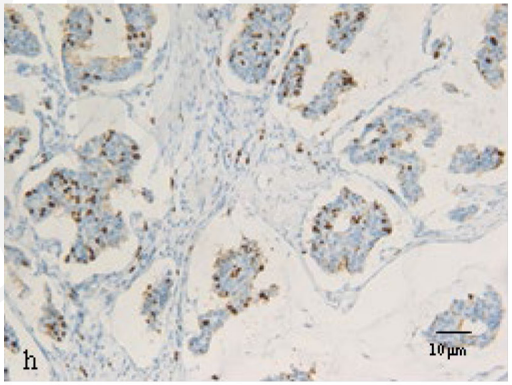
h
10 µm

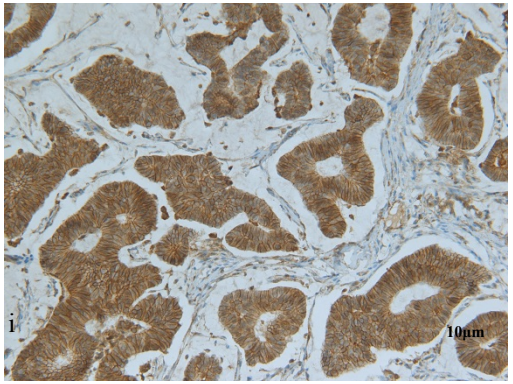
i
10µm

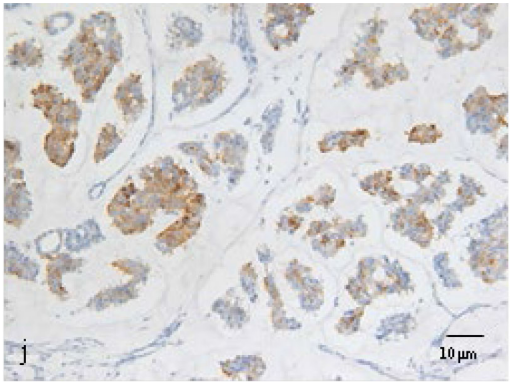

Fig. 6 Pathological images after operation.
(a) H&E stain ×20. (b–j) Immunohistochemical staining results:
(b) ER(+ >75%) ×20; (c) PR (+ >75%) ×20; (d) HER-2 (+) ×40; (e) CK7 (+) ×20; (f) CK20 (weak +) ×40; (g) EMA (outer rim +) ×20; (h) Ki-67(+ <25%) ×20; (i) p120(film +) ×20; (j) Syn (focal +) ×20

JZUS-B