Cite this as: Ye-sheng XU, Wen-jia XIE, Yu-feng YAO, 2017. Satisfactory clinical outcome following delayed repositioning of a traumatic post-LASIK flap with dislocation and shrinkage managed by irrigation, stretching, and debridement. *Journal of Zhejiang University-Science B (Biomedicine & Biotechnology)*, 18(6):539-543. http://dx.doi.org/10.1631/jzus.B1600363

Satisfactory clinical outcome following delayed repositioning of a traumatic post-LASIK flap with dislocation and shrinkage managed by irrigation, stretching, and debridement

Key words: Delayed repositioning; LASIK; Traumatic flap dislocation

Research Summary

This article reports the surgical management and favorable outcome in a case with delayed repair of traumatic laser in situ keratomileusis (LASIK) flap dislocation with shrinkage and folds

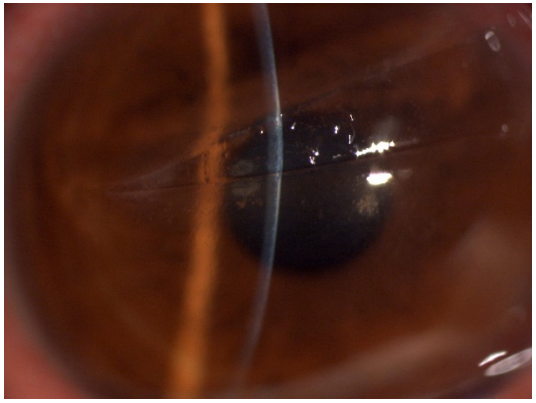

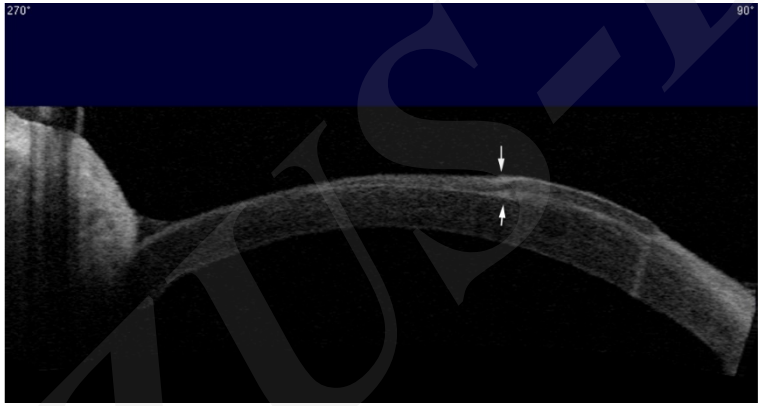

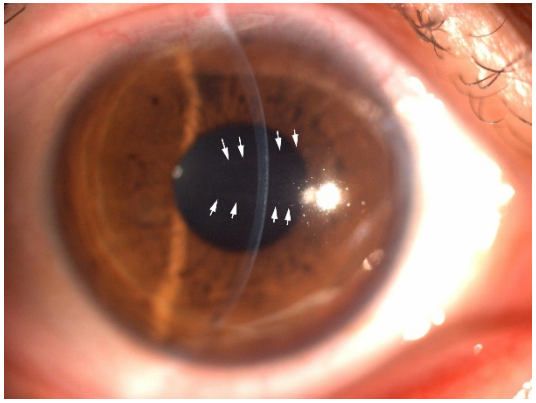

Three key manipulations to achieve a satisfactory result:

- ✓ **Carefully stretching the flap**
- ✓ **Thoroughly debriding ingrown epithelium**
- ✓ **Perfectly matching the flap with its original margin**

JZUS-B

Innovation points

- **Describe** the surgical method to deal with the delayed repositioning of post-LASIK flap with dislocation and shrinkage.

- **Report** the satisfactory clinical result can be achieved by surgery without suturing

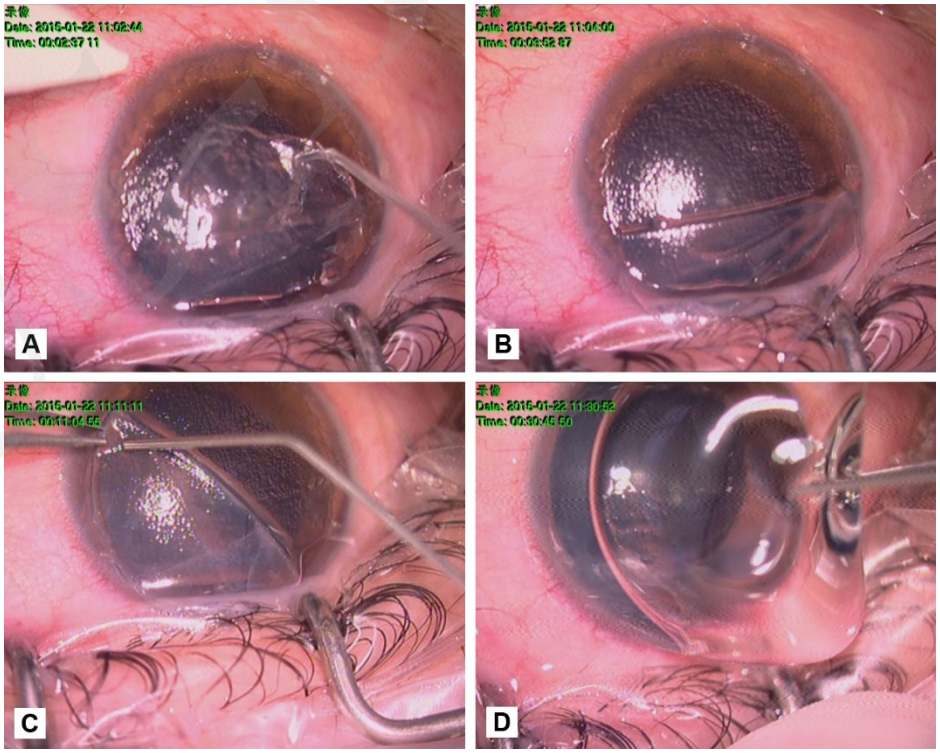

JZUER