Cite this as: Li-li SUN, Wen-xiong TANG, Lei LIU, Wei WANG, Si-xun ZHANG, Zun-jing LIU, 2017. Dural arteriovenous fistula disguised as cerebral venous sinus thrombosis. *Journal of Zhejiang University-Science B (Biomedicine & Biotechnology)*, 18(8):733-736.
http://dx.doi.org/10.1631/jzus.B1600499

Dural arteriovenous fistula disguised as cerebral sinus thrombosis

Key words：Dural arteriovenous fistula, Cerebral sinus thrombosis, Susceptibility-weighted MRI, Digital subtraction angiography

JZUS-B

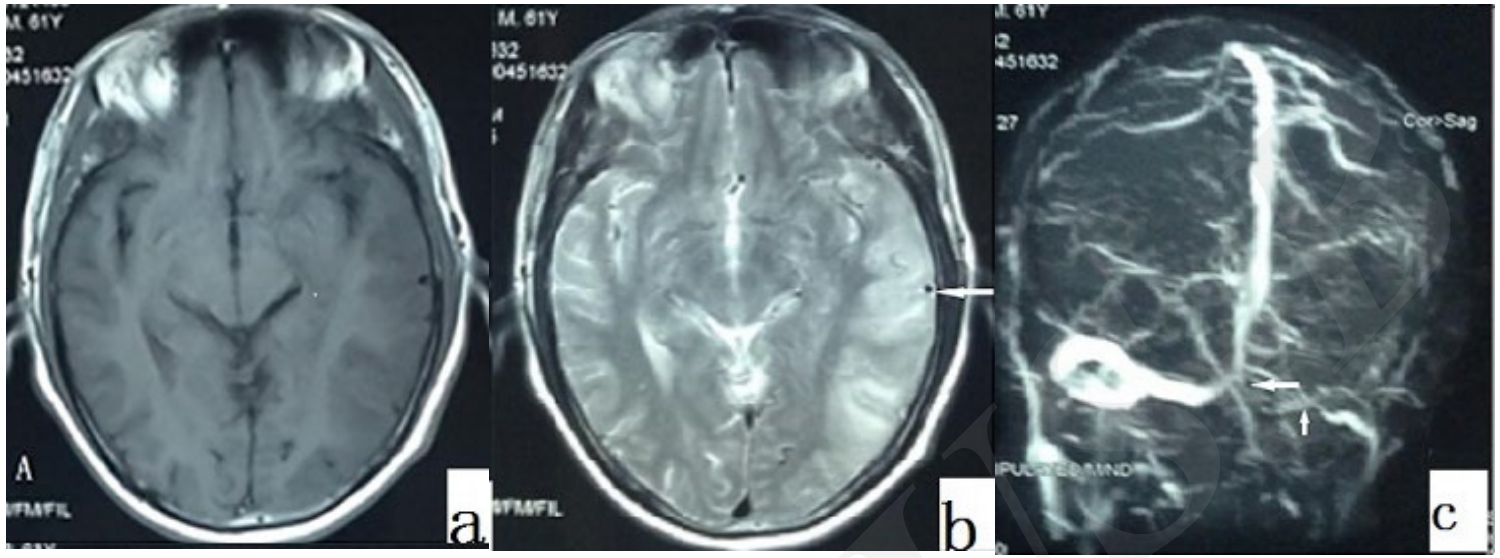

A 61-year-old male was admitted after suffering a speech disorder and slow reactions. One day after admission, he had two episodes of general epileptic seizure.

MRI revealed ischemic lesions of the left temporal and occipital lobes with mass effect and perifocal edema (Figures a、 b).

MRV revealed a filling defect in the torcular and left transverse and sigmoid sinus(Figures c).

Therefore,the initial diagnosis was made as “**left transverse and sigmoid sinus thrombosis**”.

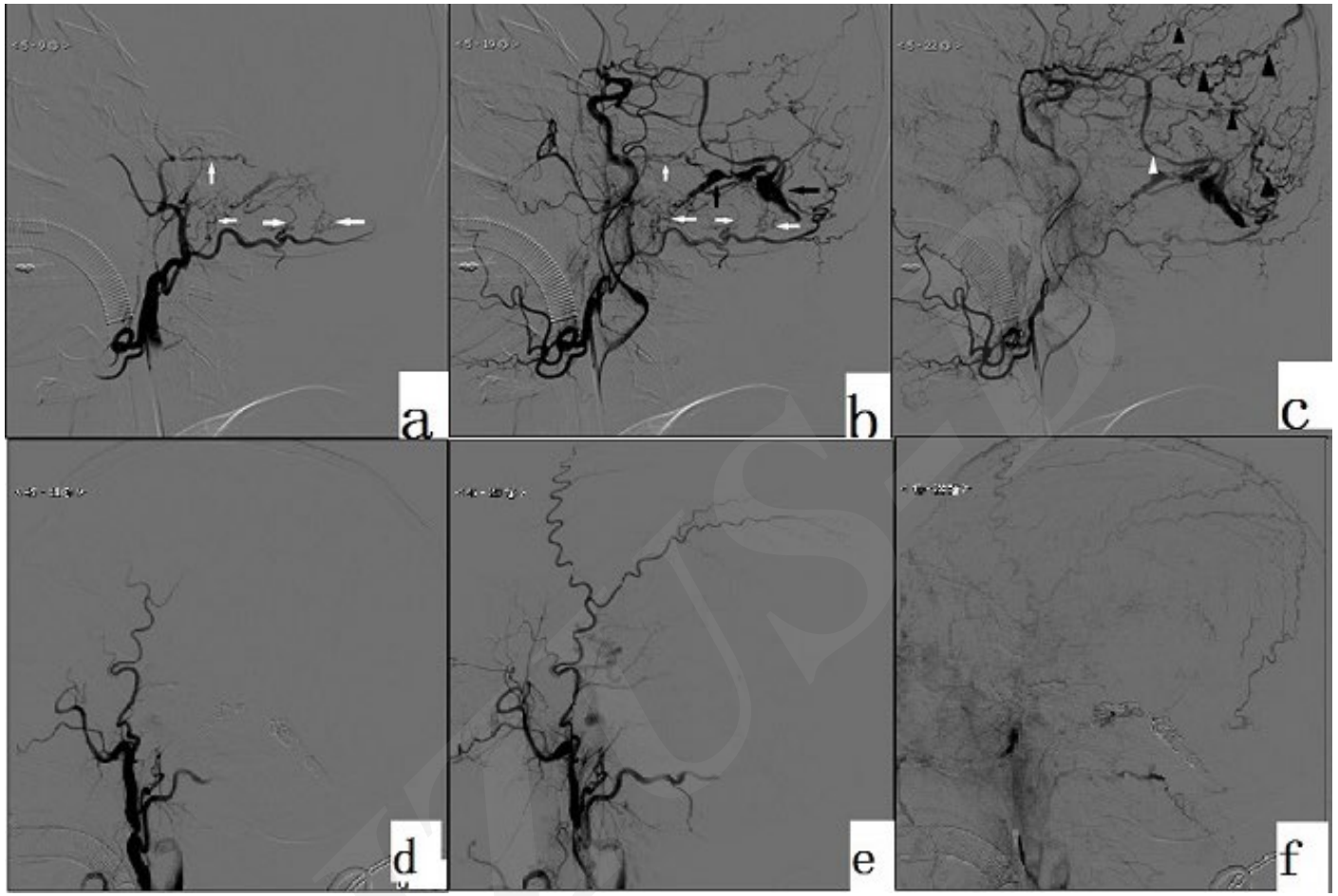

However, DSA was performed furtherly, which revealed an **arteriovenous fistula** fed by both the middle meningeal artery and the occipital artery(white arrows), and draining into the left transverse and sigmoid sinus.

Summary

- After literature reviewed, we summarized the possible reasons for misdiagnosis. The limitation of noninvasive examinations and the fact that DAVF and CST may reinforce each other were the main reasons for this mis-diagnosis.

- In conclusion, a DSA examination should be recommended for patients with “sinus thrombosis” following non-invasive examinations, especially when hyperintensity is revealed by SWI (Figure d).

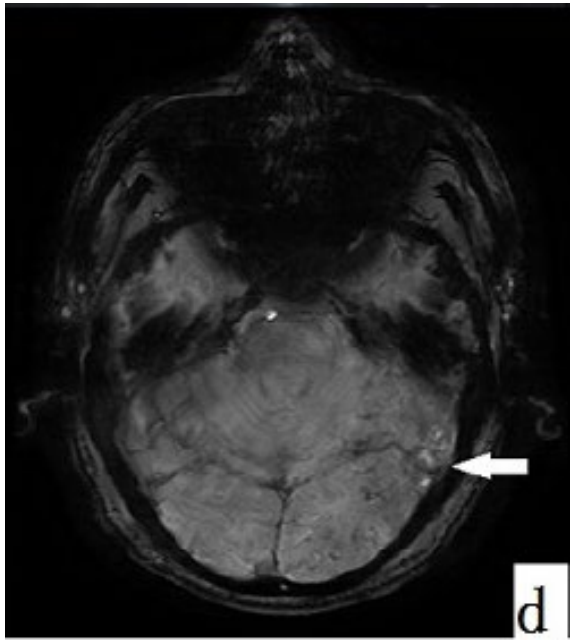

JZUSB