Cite this as: Yuan LIANG, Zhou YANG, Zi-gang XU, Lin MA, 2017. Toxic epidermal necrolysis after dactinomycin and vincristine combination chemotherapy for nephroblastoma. *Journal of Zhejiang University-Science B (Biomedicine & Biotechnology)*, 18(7):649-652.
http://dx.doi.org/10.1631/jzus.B1700065

Toxic epidermal necrolysis after dactinomycin and vincristine combination chemotherapy for nephroblastoma

Key words: Drug reaction, Malignant neoplasm, Toxic epidermal necrolysis, Chemotherapy, Nephroblastoma

Case Report Summary

We describe a patient with nephroblastoma who has developed toxic epidermal necrolysis associated with combination chemotherapy administration of dactinomycin and vincristine :



Fig.1 Coalescing violaceous macules with flaccid bullae developed on face



Fig.2 Right arm showing bullae on the original erythematous dusky red macules



Fig.3 Erosions with hemorrhagic crusts on lips and conjunctivitis can be seen

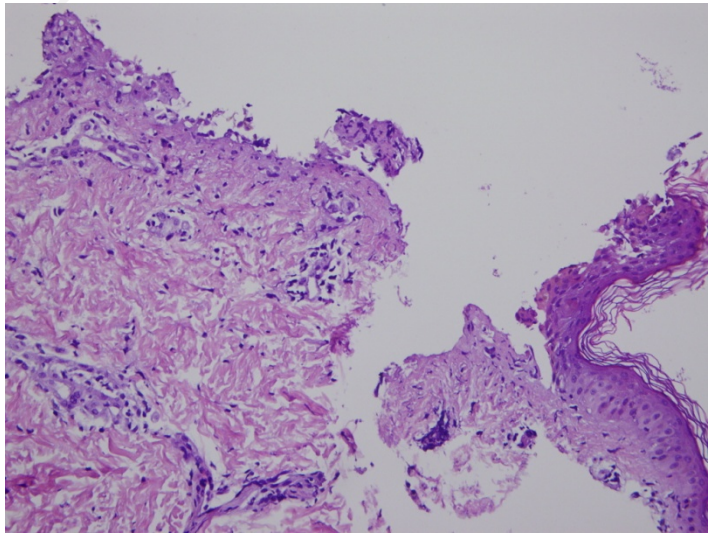

Fig.4 Completely necrotic epidermis is detached from underlying dermis, with mild chronic inflammation was noted in the dermo-epidermal junction and upper dermis (H&E, ×20)

Innovation points

- **A pediatric case of dactinomycin-induced TEN**
- **An alert for the oncologist aware of the particular syndrome-TEN**
- **An alert for the dermatologist cautious of TEN occurred in oncologic patients with chemotherapy**

JZUSB