***Cite this as*:** Wen-jia XIE, Ye-sheng XU, Xia ZHANG, Yu-feng YAO, 2018. Assessments of tear meniscus height, tear film thickness, and corneal epithelial thickness after deep anterior lamellar keratoplasty. *Journal of Zhejiang University-Science B (Biomedicine & Biotechnology)*, 19(3):218-226.
https://doi.org/10.1631/jzus.B1700095

Assessments of tear meniscus height, tear film thickness, and corneal epithelial thickness after deep anterior lamellar keratoplasty

Key words: Tear meniscus height, Corneal epithelial thickness, Tear film, Deep anterior lamellar keratoplasty (DALK), High-definition optical coherence tomography (HD-OCT), Keratoconus

Research Summary

This is the first study to assess corneal thickness along with tear film thickness and tear meniscus height after DALK using HD-OCT

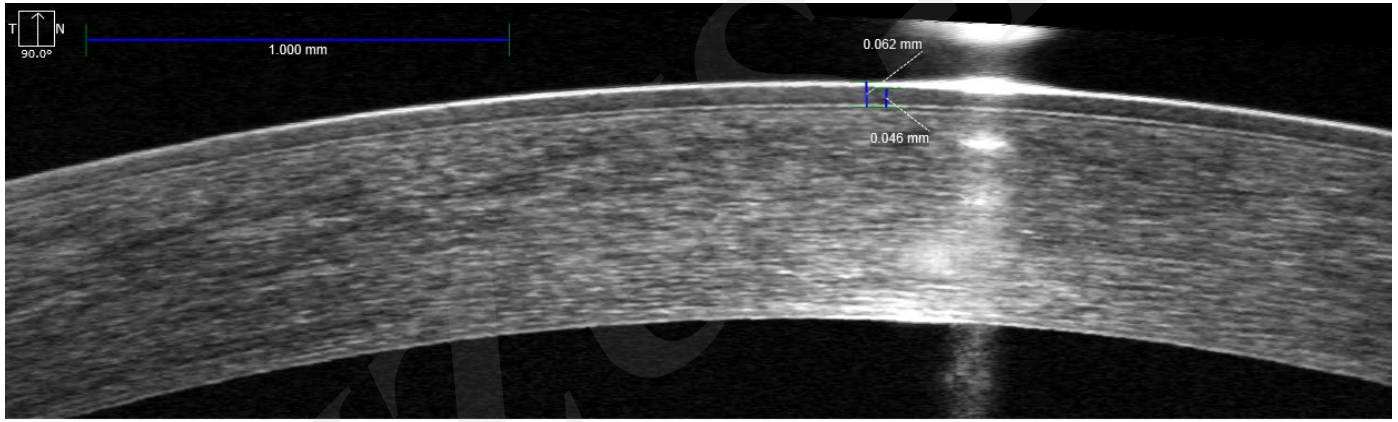



Main findings

- Patients with keratoconus have a thinner corneal epithelium
- Corneal epithelium keeps regenerating over time after DALK
- DALK did not induce a significant change in tear volume
- Postoperative tear function might depend on an individual's general condition

JZUSEB

Figure 4