Cite this as: Le-xing ZHANG, Jing-jing XIANG, Pei-ying WEI, Jin-wang DING, Ding-cun LUO, Zhi-yi PENG, Zhi-jiang HAN, 2018. Diagnostic value of computed tomography (CT) histogram analysis in thyroid benign solitary coarse calcification nodules. *Journal of Zhejiang University-Science B (Biomedicine & Biotechnology)*, 19(3):211-217.
https://doi.org/10.1631/jzus.B1700119

Diagnostic value of computed tomography (CT) histogram analysis in thyroid benign solitary coarse calcification nodules

Key words: **Thyroid nodule, thyroid cancer, coarse calcification, computed tomography**

Research Summary

This study investigate the diagnostic value of the CT histogram in thyroid benign solitary coarse calcification nodules.



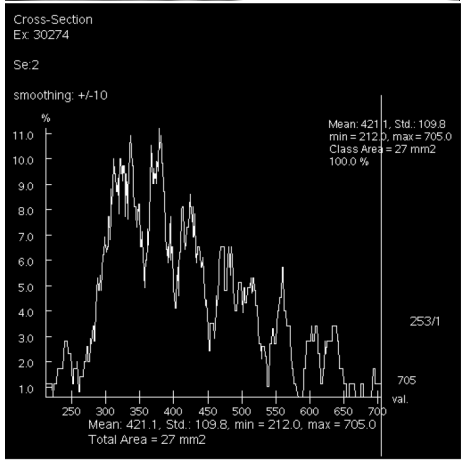

- Calcification is commen in thyroid nodules.
- The density of calcifications is correlated with benign or malignant nodules.
- The CT histogram can reflect the pixel density of the calcifications.

JZUS-B

Innovation points

- Firstly use CT histogram for the differential diagnosis of MSCN and BSCN.

- Different cut-off value and area percentage can provide differert accuracy, sensitivity and specificity.

- This can provide an important basis for reducing the misdiagnosis, and unnecessary surgical trauma.

JZUS-B