

***Cite this as:*** Ping WANG, Congying SONG, Yuanqiang LU. Isolated superior mesenteric artery rupture caused by abdominal trauma[J]. Journal of Zhejiang University Science B, 2022, 23(12): 1065-1068.

<http://doi.org/10.1631/jzus.B2200288>

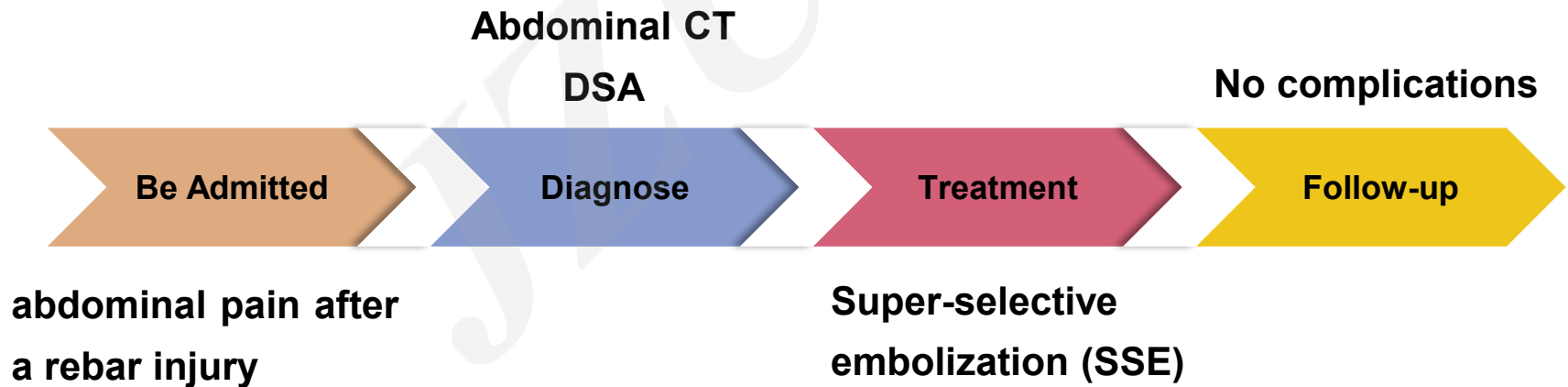
# **Isolated superior mesenteric artery rupture caused by abdominal trauma**

**Key words:** Blunt abdominal mesenteric injury; Superior mesenteric artery injury; Super-selective embolization

# ***Innovation points***

**This unique case report describes a patient with a ruptured isolated superior mesenteric artery caused by a rebar accident.**

## **timeline**



# ***Innovation points***



## **Lesson 1**

**Isolated mesenteric injuries should be considered in any patient presenting with blunt abdominal trauma.**



## **Lesson 2**

**SSE may be a promising therapy to treat mesenteric injuries, on account of the reduction in major complications and recurrent bleeding.**

