Cite this as: Xianbao LIU, Hanyi DAI, Jiaqi FAN, Dao ZHOU, Gangjie ZHU, Abuduwufuer YIDILISI, Jun CHEN, Yeming XU, Lihan WANG, Jian'an WANG. Cerebral ischemic injury after transcatheter aortic valve replacement in patients with pure aortic regurgitation[J]. Journal of Zhejiang University Science B, 2023, 24(6): 530-538. http://doi.org/10.1631/jzus.B2200444

Cerebral ischemic injury after transcatheter aortic valve replacement in patients with pure aortic regurgitation

Key words: Cerebral ischemic injury; Transcatheter aortic valve replacement; Pure aortic regurgitation; Transfemoral; Transapical

Research Summary

This review mainly showed cerebral ischemic injury was common in patients after TAVR. The incidence, number and total volume of cerebral ischemic lesions were comparable between the AS and the pure AR groups.

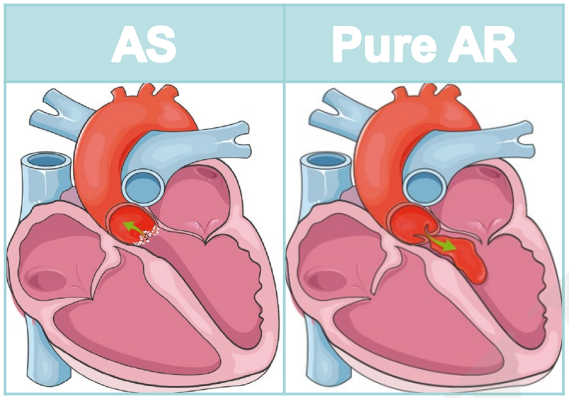

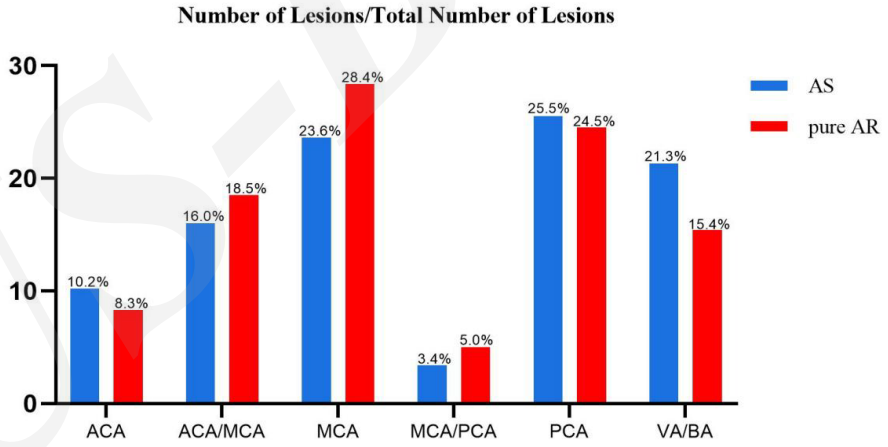

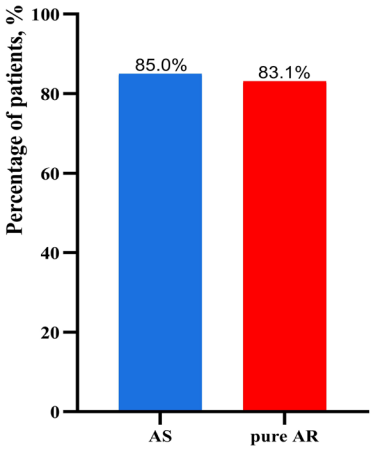

Incidence

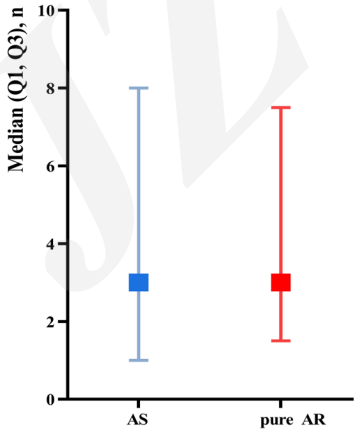

Total Number

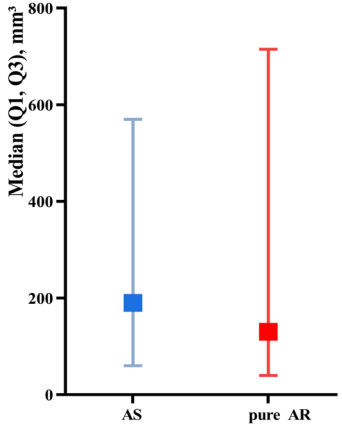

Total Volume

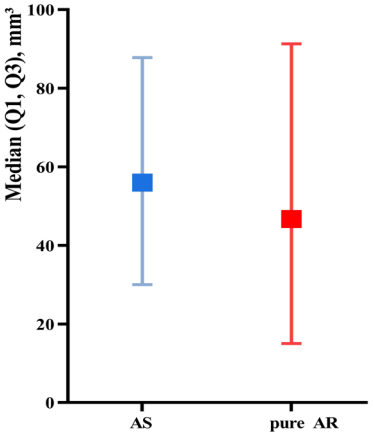

Volume/Number

Innovation points

Introduction

To compare the detailed characteristics in cerebral ischemic lesions between AS and the pure AR patients.

Summary

Cerebral ischemic lesions after TAVR were prevalent and there no differences were found between AS and the pure AR patients.

Emphasis

The incidence, number and total volume of cerebral ischemic lesions were comparable between the AS and the pure AR groups.

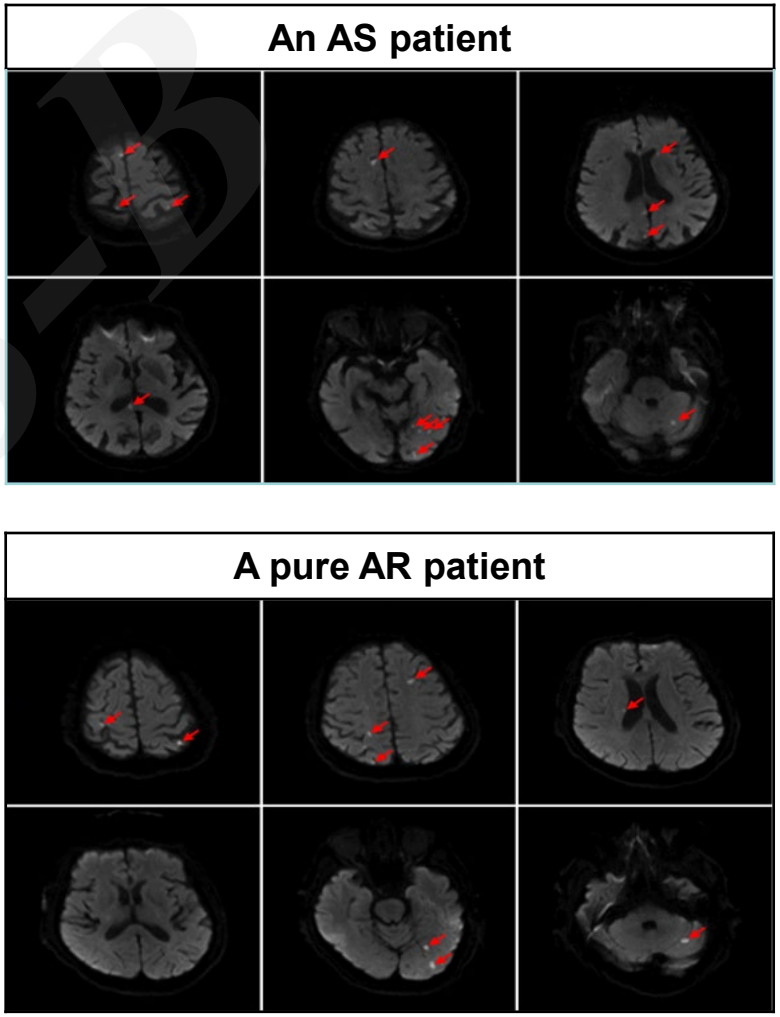

Figure 4

Innovation points

A series of comprehensive tables were generated to summarize the detailed characteristics of cerebral ischemic lesions.

Table 1| Baseline Data of AS and Pure AR Patients.

Table 2| Procedural characteristics and in-hospital clinical outcomes.

Table 3| DW-MRI Findings for AS and Pure AR patients.

Table 4| DW-MRI Findings for Pure AR patients.

Table 5| Poisson regression analysis for the prediction of the number of post-procedural lesions in pure AR patients.

JZUS-B