

Case Report:

Vascular complications following prophylactic balloon occlusion of the internal iliac arteries resolved by successful interventional thrombolysis in a patient with morbidly adherent placenta*

Ning ZHANG^{§1}, Wei-hua LOU^{§1}, Xue-bin ZHANG², Jia-ning FU³,
Yun-yan CHEN¹, Zhi-guo ZHUANG⁴, Jian-hua LIN^{†‡1}

¹Department of Obstetrics and Gynecology, Renji Hospital, School of Medicine, Shanghai Jiao Tong University, Shanghai 200126, China)

²Department of Interventional Oncology, Renji Hospital, School of Medicine, Shanghai Jiao Tong University, Shanghai 200126, China)

³Columbia Center for Translational Immunology, Columbia University Medical Center, New York, NY 10032, USA)

⁴Department of Radiology, Renji Hospital, School of Medicine, Shanghai Jiao Tong University, Shanghai 200126, China)

[†]E-mail: linjhuarj@126.com

Received July 9, 2016; Revision accepted Sept. 12, 2016; Crosschecked Feb. 8, 2017

Abstract: The increasing incidence of morbidly adherent placenta (MAP) is placing women at a higher risk of life-threatening massive hemorrhage. The involvement of interventional radiology to manage this complex condition by performing prophylactic iliac artery balloon occlusion has been reported recently. However, the effectiveness and safety of this technique have not been fully determined. Here we report the case of a 25-year-old woman with placenta increta with preemptive bilateral internal iliac artery balloons who had external iliac artery thrombosis detected by computed tomography angiography (CTA) 72 h post cesarean section. A digital subtraction angiogram (DSA) and intra-arterial thrombolysis were instantly performed followed by supplementary conservative treatments, leading to a desirable resolution of thrombus without sequela. This is the first report of vascular complications with successful interventional thrombolysis in this setting. Our experience suggests that prophylactic iliac artery balloon occlusion should be used cautiously in cases of MAP and consideration given to minimizing vascular complications given the hypercoagulable state of pregnancy.

Key words: Balloon catheter; Internal iliac artery; Placenta accrete; Vascular complication; Interventional thrombolysis
<http://dx.doi.org/10.1631/jzus.B1600315>

CLC number: R714.2

1 Introduction

Massive hemorrhage from abnormal placentation is a leading cause of postpartum maternal death and hysterectomy after cesarean section. Morbidly

adherent placenta (MAP), a condition that causes significant maternal morbidity and mortality from primary postpartum hemorrhage, is experiencing an increase in line with the increased incidence of cesarean delivery.

Nowadays, endovascular surgeons and radiologists assist in the management of abnormal placentation by inserting bilateral internal iliac artery balloon occlusion catheters (IIABOCs) to potentially decrease surgical bleeding. However, this practice still lacks supporting data, and the rate of procedure-related complications has not been fully determined. We

[‡] Corresponding author

[§] The two authors contributed equally to this work

* Project supported by the Natural Science Foundation of Science and Technology Commission of Shanghai Municipality (No. 16ZR1420000), China

ORCID: Ning ZHANG, <http://orcid.org/0000-0001-6306-4819>

© Zhejiang University and Springer-Verlag Berlin Heidelberg 2017

report on a patient with an MAP who underwent a cesarean delivery successfully, preserving the uterus with the aid of IIABOC. Although the vascular complication of arterial thrombosis occurred in this patient after the operation, no sequela developed because of subsequent successful interventional thrombolysis.

2 Case report

A 25-year-old G3P2 (1-1-0-1) woman was admitted at 29⁺² weeks gestation for spotty vaginal bleeding. She had experienced two prior cesarean deliveries due to fetal distress and previous cesarean section, respectively. Partial placenta previa and suspected placenta increta were indicated by ultrasonography. Subsequent magnetic resonance imaging (MRI) revealed the partial placenta previa and discontinuation of the myometrium as well as abundant engorged and tortuous peri-uterine veins in the region of the cervical os, confirming a morbid placenta increta (Fig. 1).

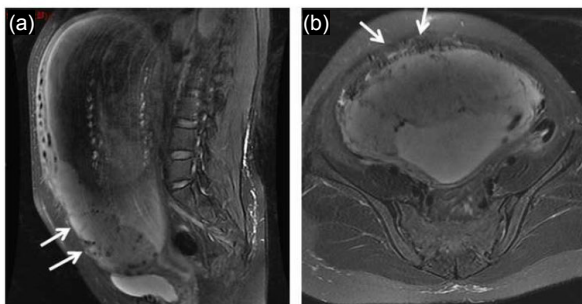


Fig. 1 Magnetic resonance imaging (MRI) at 30 weeks of gestation demonstrating an irregular border between the myometrium and placenta (arrows)

Sagittal MRI (a) and axial MRI (b) demonstrate segment of placenta extending outside of the visible myometrium in the region of the anterior inferior abdominal wall as well as the thinning and incontinuity of the myometrium

The patient was monitored closely. When approaching 33 weeks of gestation, frequent minimal vaginal bleeding occurred under treatment with tocolytic medicine: massive hemorrhage was anticipated, and an elective cesarean section with the aid of IIABOC was scheduled. At 33 weeks of gestation, we performed the operation. The patient was brought to the interventional radiology suite after a ureteral stent was inserted by a urologist. Both common femoral arteries were punctured under local anesthesia, and a

6-Fr sheath was inserted. Heparin was not administered due to the hemorrhage risk. The proper positioning of the balloons and effective vascular occlusion were confirmed angiographically. The patient was then transferred to the operating room. General anesthesia was administered and a transverse hysterotomy was performed. The infant was delivered and the cord was clamped instantly followed by the inflation of both occlusion balloon catheters to the predetermined volume by the interventional radiologist. Total intraoperative blood loss was 4200 ml, and with transfusion of 9 units of packed red blood cells and 12 units of fresh frozen plasma, the patient was maintained stable throughout the surgery.

The balloon catheter was kept continuously inflated overnight; the sheaths and occlusion balloon catheters were removed by the interventional radiologist the next morning (specifically, 16 h post-operation). Of note, the patient did not follow the post-operative advice to keep her lower limbs still. Instead, she agitated and twisted her legs and feet frequently during the post-operative period of balloon catheter inflation.

The patient was started on low molecular weight heparin (LMWH) 24 h post-operation with a hemoglobin level of 8.8 g/dl and D-dimer level of 5.592 $\mu\text{g/ml}$. She remained unremarkable until Day 3 post-operation when she complained of decreased muscle strength in the right lower limb. Physical examination found a warm foot but diminished right dorsalis pedis pulse. Vascular ultrasound and computed tomography angiography (CTA) (Figs. 2a and 2b) indicated thrombosis or embolism of the right iliac artery (the D-dimer level was 0.627 $\mu\text{g/ml}$).

Interventional radiologists and vascular surgeons were consulted immediately and proceeded with emergent interventional thrombolysis. A digital subtraction angiogram (DSA) confirmed the complete occlusion of the right external iliac artery (Fig. 3a). Thrombolysis with heparin and urokinase was performed. Repeated DSA (Fig. 3b) then showed patency of the whole right external iliac artery accompanied by residual mural thrombus, and well-developed femoral and distal arteries. She was maintained with conservative treatment of LMWH and warfarin supplemented with other agents for anticoagulation, capillary improvement as well as appropriate guidance on physical therapy. Repeated CTA (Figs. 2c and 2d) on Day 3 post-thrombolysis

showed good patency of the right external iliac artery. The patient was discharged on post-thrombolytic Day 11, without sequela and with continuous outpatient treatment with anticoagulation. Final pathology revealed placenta increta with chorionic villi invading into the uterine wall.

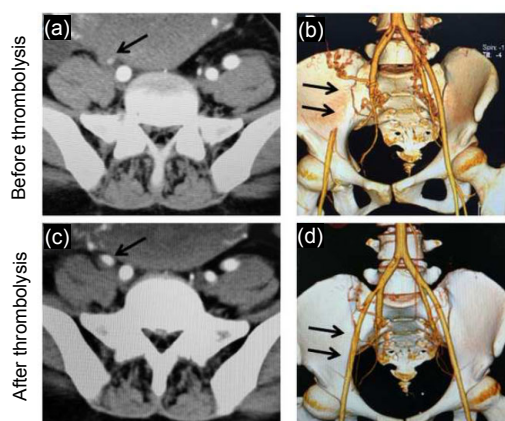


Fig. 2 Imaging studies of iliac arteries using angiograph and 3D multi-detector computed tomography (MDCT) before and after thrombolysis

Before thrombolysis angiograph (a) and MDCT (b) reconstructed images show the extent and degree of thrombosis (indicated by arrows) with complete occlusion of the right external iliac artery. After interventional thrombolysis angiograph (c) and MDCT (d) reconstructed images show good patency (indicated by arrows) of the right external iliac artery

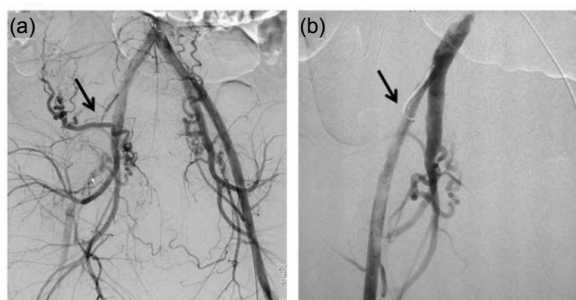


Fig. 3 Imaging studies of iliac arteries using digital subtraction angiogram (DSA) before and after thrombolysis

(a) Before thrombolysis DSA confirms occlusion (indicated by arrows) of right external iliac artery and patency of left iliac artery system. (b) After interventional thrombolysis DSA demonstrates patency (indicated by arrows) of right external iliac artery

3 Discussion

Placenta accreta and its variants, increta or percreta, represent one of the most challenging situations confronted by obstetricians. The traditional

standard management for this potentially life-threatening condition is cesarean delivery followed by hysterectomy with or without bowel or bladder resection. The alternative therapies include compression sutures and balloon tamponade with the placenta remaining in situ, which carry a risk of sepsis and delayed haemorrhage. Other effective approaches such as artery ligation and interventional radiology have attracted great interest for further investigation.

Paull *et al.* (1995) first reported the use of infrarenal aortic balloon occlusion to minimize massive obstetric hemorrhage. Soon after, prophylactic IIABOC was successfully used in two patients with placenta percreta (Dubois *et al.*, 1997). The role of interventional radiology as a lifesaving procedure in the field of obstetric hemorrhage has since been widely investigated. The UK is the only country so far to issue a national guideline, in 2007, which recommends the use of interventional radiology with prophylactic placement of IIABOCs to reduce intraoperative bleeding during caesarean section for women with abnormal placentation (Royal College of Obstetricians and Gynaecologists *et al.*, 2007).

To date, however, there is a lack of robust evidence showing the benefit of this therapy in terms of hemorrhage control and uterus preservation. The current published literature has been limited to case reports (Sewell *et al.*, 2006; Greenberg *et al.*, 2007; Bishop *et al.*, 2011; Matsueda *et al.*, 2015), descriptive case series (Carnevale *et al.*, 2011; Teixidor Vinas *et al.*, 2014; Chou *et al.*, 2015), small case-control comparisons (Shrivastava *et al.*, 2007), or small prospective cohort studies (Bodner *et al.*, 2006), which have yielded mixed results. Failure of this procedure is often due to extensive anastomosis in the pelvic vasculature. Technique-related multiple complications have also contributed to the controversy over this procedure. Several vascular complications, such as popliteal artery thrombosis and iliac artery thrombosis, were initially reported by Sewell *et al.* (2006) and Greenberg *et al.* (2007). Similar cases with arterial complication were subsequently reported by others (Sewell *et al.*, 2006; Greenberg *et al.*, 2007; Shrivastava *et al.*, 2007; Bishop *et al.*, 2011; Carnevale *et al.*, 2011; Teixidor Vinas *et al.*, 2014; Chou *et al.*, 2015; Matsueda *et al.*, 2015).

Our unit, a tertiary obstetric and referral center for complicated pregnancies in the Shanghai

municipality, has been using the IIABOCs technique since 2011. Thirty cases have been performed with no arterial complications until this case (5%, 1/20). In a review of previous literature, arterial thrombosis associated with balloon catheter placement occurred in 3 of 19 (15.8%) (Shrivastava *et al.*, 2007), 2 of 13 (15.4%) (Chou *et al.*, 2015), 1 of 27 (3.7%) (Teixidor Vinas *et al.*, 2014), and 2 of 21 subjects (9.5%) (Carnevale *et al.*, 2011). The risk of occlusion is 0.5% from the iliac artery, 0.3% due to pseudoaneurysm, and 0.6% involving vessel rupture in the non-pregnant population (Royal College of Radiologists and British Society of Interventional Radiology, 2007). The hypercoagulable state of pregnancy increases the risk of a thromboembolic event, and the vascular wall remodeling of arteries in pregnant women also enhances the complication and susceptibility of dissection.

Prolonged catheterisation is a significant contributing factor to vascular complication, and early device removal has been recommended by many institutions (Carnevale *et al.*, 2011). However, currently there is no definitive guideline for determining the duration of inflation and the appropriate time for device removal. Teixidor Vinas *et al.* (2014) presented a protocol of keeping balloons inflated for 4 h post-operation, based on the fact that 66% of hemorrhages occur within 2 h after delivery, and leaving the catheters in situ for 24 h to allow rapid re-inflation if needed, as 33% of haemorrhages occur more than 4 h after delivery.

In our tertiary center, we performed the first case in 2011 by removing the preset balloon immediately after cesarean section, resulting in significant blood loss and requiring emergent embolization and hysterectomy. We then modified the protocol to maintain balloon inflation 12–24 h post-operation; no post-operative haemorrhage or vascular complication occurred until the case reported in this paper. Keeping the lower extremities strictly still is the priority advice to patients during the period of device placement, but in this case the patient was unable to follow the recommendation, which we suggest is the most significant contributing factor for the vascular complication as the agitation and twisting contributed to the displacement of the catheter and damage of the vessel. However, this case prompted us to reconsider the current protocol of reducing the duration of inflation

and device placement. The key issue waiting to be addressed is the time-related probability of post-operative hemorrhage in order to maximize the advantage of prophylactic balloon occlusion and minimize the risk of vascular complications. We will continue collecting data on subsequent patients.

The safety and effectiveness of preoperative occlusive balloon catheters for abnormal placenta remains controversial. We encouraged this novel technique based on our previous experience, but caution must be exercised given the lack of meaningful evidence to support this strategy and the occurrence of practice-related dangerous vascular complications. Further research is needed to support the standardization of the proposed method in clinical application. A centralized registry is highly recommended for assembling scattered data and collecting evidence, which will record more instances of this procedure and possibly generate new variants of the technique. Meanwhile, tracking potential complications and associated cofactors will facilitate future comparisons and the development of international guidelines.

Acknowledgements

We acknowledge all the multidisciplinary members of the obstetrics, interventional radiology, vascular surgery, and anesthetics teams from Renji Hospital (Shanghai, China) for their dedication and support.

Compliance with ethics guidelines

Ning ZHANG, Wei-hua LOU, Xue-bin ZHANG, Jia-ning FU, Yun-yan CHEN, Zhi-guo ZHUANG, and Jian-hua LIN declare that they have no conflict of interest.

All procedures followed were in accordance with the ethical standards of the responsible committee on human experimentation (institutional and national) and with the Helsinki Declaration of 1975, as revised in 2008 (5). Informed consent was obtained from the patient for being included in the study. Additional informed consent was obtained from the patient for which identifying information is included in this article.

References

- Bishop, S., Butler, K., Monaghan, S., *et al.*, 2011. Multiple complications following the use of prophylactic internal iliac artery balloon catheterisation in a patient with placenta percreta. *Int. J. Obstet. Anesth.*, **20**(1):70-73. <http://dx.doi.org/10.1016/j.ijoa.2010.09.012>
- Bodner, L.J., Noshier, J.L., Gribbin, C., *et al.*, 2006. Balloon-assisted occlusion of the internal iliac arteries in patients with placenta accreta/percreta. *Cardiovasc. Intervent.*

- Radiol.*, **29**(3):354-361.
<http://dx.doi.org/10.1007/s00270-005-0023-2>
- Carnevale, F.C., Kondo, M.M., de Oliveira Sousa, W., et al., 2011. Perioperative temporary occlusion of the internal iliac arteries as prophylaxis in cesarean section at risk of hemorrhage in placenta accreta. *Cardiovasc. Intervent. Radiol.*, **34**(4):758-764.
<http://dx.doi.org/10.1007/s00270-011-0166-2>
- Chou, M.M., Kung, H.F., Hwang, J.I., et al., 2015. Temporary prophylactic intravascular balloon occlusion of the common iliac arteries before cesarean hysterectomy for controlling operative blood loss in abnormal placentation. *Taiwan J. Obstet. Gynecol.*, **54**(5):493-498.
<http://dx.doi.org/10.1016/j.tjog.2014.03.013>
- Dubois, J., Garel, L., Grignon, A., et al., 1997. Placenta percreta: balloon occlusion and embolization of the internal iliac arteries to reduce intraoperative blood losses. *Am. J. Obstet. Gynecol.*, **176**(3):723-726.
[http://dx.doi.org/10.1016/S0002-9378\(97\)70582-9](http://dx.doi.org/10.1016/S0002-9378(97)70582-9)
- Greenberg, J.L., Suliman, A., Iranpour, P., et al., 2007. Prophylactic balloon occlusion of the internal iliac arteries to treat abnormal placentation: a cautionary case. *Am. J. Obstet. Gynecol.*, **197**(5):470.e1-470.e4.
<http://dx.doi.org/10.1016/j.ajog.2007.05.017>
- Matsueda, S., Hidaka, N., Kondo, Y., et al., 2015. External iliac artery thrombosis after common iliac artery balloon occlusion during cesarean hysterectomy for placenta accreta in cervico-isthmic pregnancy. *J. Obstet. Gynaecol. Res.*, **41**(11):1826-1830.
<http://dx.doi.org/10.1111/jog.12777>
- Paull, J.D., Smith, J., Williams, L., et al., 1995. Balloon occlusion of the abdominal aorta during cesarean hysterectomy for placenta percreta. *Anaesth. Intens. Care*, **23**(6):731-734.
- Royal College of Obstetricians and Gynaecologists, Royal College of Radiologists, British Society of Interventional Radiology, 2007. The Role of Emergency and Elective Interventional Radiology in Postpartum Haemorrhage. (Good Practice Guidance No. 6). Royal College of Obstetricians and Gynaecologists.
- Royal College of Radiologists, British Society of Interventional Radiology, 2007. Achieving Standards in Vascular Radiology. Royal College of Radiologists, London.
- Sewell, M.F., Rosenblum, D., Ehrenberg, H., 2006. Arterial embolus during common iliac balloon catheterization at cesarean hysterectomy. *Obstet. Gynecol.*, **108**(3 Pt 2):746-748.
<http://dx.doi.org/10.1097/01.AOG.0000201992.80130.2c>
- Shrivastava, V., Nageotte, M., Major, C., et al., 2007. Case-control comparison of cesarean hysterectomy with and without prophylactic placement of intravascular balloon catheters for placenta accreta. *Am. J. Obstet. Gynecol.*, **197**(4):402.e1-402.e5
<http://dx.doi.org/10.1016/j.ajog.2007.08.001>
- Teixidor Vinas, M., Chandraran, E., Moneta, M.V., et al., 2014. The role of interventional radiology in reducing haemorrhage and hysterectomy following caesarean section for morbidly adherent placenta. *Clin. Radiol.*, **69**(8):e345-e351.
<http://dx.doi.org/10.1016/j.crad.2014.04.005>

中文概要

题目: 介入溶栓成功治愈前置球囊术在凶险性前置胎盘应用中诱发的动脉血栓

目的: 球囊预置术的在产科领域的应用缺乏指南规范, 该病例分析和文献汇纳分析将为该技术在产科临床应用中的利弊和并发症防治提供参考指导。

创新点: 首例报道介入溶栓成功治愈前置球囊术在凶险性前置胎盘应用中诱发的动脉血栓。

方法: 结合病例报道和文献汇纳分析。患者女, 25岁, 入院诊断: (1) G3P2 (1-1-0-1) 孕 29⁺2周单活胎, (2) 产前出血原因为凶险性前置胎盘, (3) 疤痕子宫, (4) 先兆早产。孕 33 周后实施双侧髂内动脉球囊置入术后行子宫下段剖宫产术。剖宫产术后第 3 天, 计算机断层扫描血管造影术 (CTA) 明确诊断“右髂外动脉血栓, 右髂总动脉夹层”, 立即行数字减影动脉造影 (DSA) + 介入溶栓术 + 药物巩固治疗。无并发症出院, 随访无后遗症。

结论: 球囊预置术在胎盘植入中的应用尚无指南遵循, 有效性尚存争议, 安全性有待明确, 需要各中心的数据汇纳和经验集享, 以规范该技术的最优化应用。球囊预置术导致血栓形成的并发症处理, 需要根据病情及时采取个体化治疗方案: 介入溶栓、动脉取栓、药物抗凝、期待治疗或者综合治疗等。

关键词: 球囊导管; 髂内动脉; 胎盘植入; 血管并发症; 介入溶栓