

Phyllanthus emblica leaf extract ameliorates testicular damage in rats with chronic stress^{*}

Supatcharee ARUN^{†1,2}, Jaturon BURAWAT¹, Supataechasit YANNASITHINON¹,
Wannisa SUKHORUM³, Akgpol LIMPONGSA², Sitthichai IAMSAARD^{†‡1,2}

¹Department of Anatomy, Faculty of Medicine, Khon Kaen University, Khon Kaen 40002, Thailand

²Center for Research and Development of Herbal Health Product, Faculty of Pharmaceutical Sciences, Khon Kaen 40002, Thailand

³School of Medicine, Mae Fah Luang University, Chiang Rai 57100, Thailand

[†]E-mail: supatar@kku.ac.th; sittia@kku.ac.th

Received July 4, 2018; Revision accepted Sept. 18, 2018; Crosschecked Nov. 21, 2018

Abstract: Stress affects the male reproductive system and can cause sub-fertility or infertility. Although *Phyllanthus emblica* L. (PE) extract has been shown to have high antioxidant capacity and protective properties in damaged tissue, the preventive effects of PE extract on testicular function from stress-related impairment have never been demonstrated. This study aimed to investigate the effects of PE aqueous leaf extract on testicular impairment and protein marker changes in rats suffering from chronic stress. Adult male rats were divided into four groups: a control group, a chronic stress (CS) group, and two groups with CS that received different doses of PE extract (50 or 100 mg/kg body weight (BW)). In the treatment groups, the animals were given PE extract daily before stress induction for 42 consecutive days. Stress was induced through immobilization (4 h/d) followed by forced cold swimming (15 min/d). Sperm quality and the histology of the testes and caudal epididymis were examined, as were levels of serum corticosterone, testosterone, and malondialdehyde (MDA). The expressions of testicular steroidogenic acute regulatory (StAR) and tyrosine-phosphorylated proteins were investigated using immuno-Western blot analysis, as these proteins are assumed to play important roles in spermatogenesis and androgen synthesis. The results showed that PE (50 mg/kg BW) significantly increased sperm concentration and testosterone levels, while decreasing corticosterone levels, MDA levels, sperm head abnormalities, and acrosome-reacted sperm in CS rats. In addition, PE at both doses was found to diminish testicular histopathology in the CS rats. We also found that 50 mg/kg BW of PE significantly improved StAR protein expression and altered the intensities of some tyrosine-phosphorylated proteins in testis. We conclude that PE leaf extract at 50 mg/kg BW can prevent testicular damage in rats with CS.

Key words: *Phyllanthus emblica* L. leaf extract; Chronic stress; Testicular damage; Tyrosine phosphorylation
<https://doi.org/10.1631/jzus.B1800362>

CLC number: R931


1 Introduction

Stress is a major cause of functional and structural disorders in various organs, including the male

reproductive organs, which can lead to sub-fertility or infertility (Popović and Pajović, 2010; Reis et al., 2011; Bitgul et al., 2013; Everds et al., 2013; Naninck et al., 2015). Numerous studies in animals and humans have shown that stress, in addition to significantly increasing corticosterone levels, has adverse effects on the cardiovascular, digestive, immune, and reproductive systems (İzgüt-Uysal et al., 2014; Matsuura et al., 2015; Pertsov et al., 2015; Prabsattroo et al., 2015). In males, stress decreases the levels of

[‡] Corresponding author

^{*} Project supported by the Faculty of Medicine, Khon Kaen University, Khon Kaen, Thailand (No. IN61105)

 ORCID: Supatcharee ARUN, <https://orcid.org/0000-0002-7518-2406>; Sitthichai IAMSAARD, <https://orcid.org/0000-0002-6793-2879>

© Zhejiang University and Springer-Verlag GmbH Germany, part of Springer Nature 2018

gonadotropin-releasing hormone (GnRH), follicle-stimulating hormone (FSH), and luteinizing hormone (LH), which leads to reductions in testosterone levels (Retana-Márquez et al., 2003; Rai et al., 2004; Lin et al., 2014; Prabsattroo et al., 2015). In conjunction with this decrease in testosterone, the expression of testicular steroidogenic acute regulatory (StAR) and cytochrome P450 family 11 subfamily A member 1 (CYP11A1) proteins has been shown to decrease in animals in which stress is induced via immobilization (IMO) (Dhanabalan et al., 2010; Lin et al., 2014; Arun et al., 2016a, 2016b). Such reductions can diminish sperm quality in terms of epididymal sperm count, motility, viability, morphological abnormality, and acrosome reacted status (Rai et al., 2003; Priya and Reddy, 2012; Rao et al., 2015; Zhang et al., 2015; Arun et al., 2016a, 2016b). In addition, an increase of oxidative stress, especially malondialdehyde (MDA), can damage testicular tissue in rats subjected to restraint-induced stress (Richburg, 2000; Aziz et al., 2013; Bitgul et al., 2013; Prabsattroo et al., 2015; Rao et al., 2015). Our previous research has demonstrated that both acute and chronic stress (CS) alter the expression patterns of testicular tyrosine-phosphorylated proteins, which are assumed to be associated with the impairment of testicular function and reductions in sperm quality (Arun et al., 2016a, 2016b). In addition, a recent study has revealed that tyrosine-phosphorylated proteins are expressed and localized in Leydig cells, Sertoli cells, spermatogonia, spermatocytes, and spermatids (Chaichun et al., 2017). This indicates that those proteins are involved in normal testicular function such as sperm and testosterone production. Moreover, various studies have demonstrated that changes in testicular tyrosine phosphorylation can occur with exposure to drugs, toxic substances, or herbal preventive treatments, especially those that use plant extracts in traditional medicine (Arun et al., 2016a, 2016b; Sampannang et al., 2017; Sukhorum and Iamsaard, 2017; Iamsaard et al., 2018; Maneenin et al., 2018).

Phyllanthus emblica L. (PE) is a plant that is widely used as traditional medicine in many countries, including Thailand, and is known to have various pharmacological properties. Previous studies reported that many parts of PE extracts (fruit, leaf, branch, and bark) contain large amounts of phenolic compounds and have excellent reactive oxygen species (ROS)

scavenging capacities (Liu et al., 2008; Sawant et al., 2010; She et al., 2013; Iamsaard et al., 2014; Sripanidkulchai and Junlatat, 2014; Kumnerdkhongaen et al., 2018). Also, PE extract has been shown to have anti-cancer, anti-inflammatory, anti-microbial, anti-virus, hypolipidemic, and hypoglycemic activity (Luo et al., 2011; Zhong et al., 2011; Krishnaveni and Mirunalini, 2012; Sripanidkulchai and Junlatat, 2014; Zhao et al., 2015; Srinivasan et al., 2018). Moreover, PE extract can prevent chemically or drug-induced damage to various types of tissue including testicular tissue (Pramyothin et al., 2006; Tasanarong et al., 2014; Iamsaard et al., 2015). However, the preventive effects of PE leaf extract against adverse male reproductive parameters in rats exposed to CS have never been documented. Thus, the aim of this study was to investigate the protective reproductive effects of aqueous PE leaf extract in rats suffering from CS.

2 Materials and methods

2.1 Chemicals and antibodies

Hematoxylin and eosin (H&E) were purchased from Bio-Optica Milano SpA (San Faustino, Italy), Coomassie Brilliant Blue R-250 from Bio-Rad Laboratories, Inc. (Hercules, CA, USA), and sodium dodecyl sulfate (SDS) from Loba Chemie Pvt. Ltd. (Mumbai, India). Trichloroacetic acid (TCA), butylated hydroxytoluene (BHT), and 1,1,3,3-tetraethoxypropane (TEP) were purchased from Sigma-Aldrich, Inc. (St. Louis, MO, USA). The following antibodies were used in this study: anti-StAR, StAR lysate, anti- β -actin, rabbit polyclonal antibody, and mouse polyclonal antibody. These were purchased from Santa Cruz Biotechnology, Inc. (CA, USA). Anti-phosphotyrosine, epidermal growth factor (EGF) stimulated A413 cell lysate, and bovine serum albumin (BSA) were purchased from Merck Millipore Co. (Billerica, MA, USA).

2.2 PE leaf extract collection and preparation

PE plants were purchased from the Khundong 58 Punmai Farm in the Daeng Yai district of Khon Kaen Province in Thailand. The samples were authenticated by Prof. Pranom CHANTARANOTHAI (Faculty of Science, Khon Kaen University (KKU), Thailand). Voucher specimens of PE were deposited

in the KKU herbarium (#Supatcharee Arun01 [KKU]). Fresh leaves (10–15 cm) were collected from the plants and dried in a hot air oven (60 °C) for seven days. The dried sample (2 kg) was crushed using a hammer-mill crusher. For the extraction, the crushed sample was added to 10 L of boiling distilled water for 30 min and then filtered using nylon (Toyang et al., 2012). Subsequently, the PE filtrate was powdered using a spray dryer. The extraction yield of the resulting PE leaf extract was 9.94%. The PE aqueous extract used in this experiment was proven to have high total phenolic content and exhibit antioxidant activity (Iamsaard et al., 2014).

2.3 Animals and experimental design

Male Sprague-Dawley (SD) rats weighing 150–180 g were purchased from the Mahidol University National Laboratory Animal Center (Salaya, Nakhon Pathom, Thailand). The animals were housed in plastic cages under controlled environmental conditions (temperature (22±2) °C, 12-h light/dark cycles, humidity 30%–60%, sound <85 decibels, light intensity 350–400 Lux). The experiments were approved by the Animal Ethics Committee of the Faculty of Medicine, Khon Kaen University, based on the Ethics of Animal Experimentation of the National Research Council of Thailand (No. 0514.7.1.2.2/112 with record No. AEMDKKU 005/2018). Twenty-eight rats were divided into four groups ($n=7$). The rats in each treatment group were given different doses of PE leaf extract by oral gavage before exposure to CS by IMO inside a restraint cage (4 h/d) and forced swimming in cold water (15 min/d) for 42 consecutive days (Table 1). Each rat's body weight (BW) was recorded daily.

2.4 Plasma hormone analyses

At the end of experiment, animals were euthanized by cervical dislocation. Blood was then collected and centrifuged at 13000 r/min at 4 °C for

7 min. The plasma was sent to the immunology unit, Srinagarind Hospital, Faculty of Medicine, KKU, Thailand for corticosterone and testosterone assays. The hormone levels were determined using a cobas e immunoanalyzer (Roche Diagnostics, Mannheim, Germany) and an electrochemiluminescence immunoassay (Roche Diagnostics).

2.5 Morphology and histology of the male reproductive organs

The male reproductive organs (testes, epididymis plus vas deferens, seminal vesicle plus prostate gland, and penis) were collected and the relative weight (g/100 g) of each was calculated. The gross structures of all organs were then captured using a digital camera (Nikon Coolpix S2600, Japan) and examined. Histological examination was conducted by fixing the testes and caudal epididymis (right side) in 10% phosphate buffered formalin (pH 7.4) for 48 h. The tissues were processed in a routine manner for light microscope technique. Paraffinized-tissue blocks were subsequently sectioned (7- μ m thickness) and stained using H&E (Bio-Optical Milano SpA, San Faustino, Italy). After washing, the tissue-stained slides were dehydrated, cleared, and mounted. Finally, histological images were captured using a Nikon light ECLIPSE E200 microscope equipped with a DXM1200 digital camera.

2.6 Sperm concentration and head morphological examination

The left caudal epididymis plus vas deferens was harvested and squeezed to obtain the sperm fluid. Epididymal sperm fluid was dipped and suspended in phosphate buffer saline (PBS; 37 °C, pH 7.4). Subsequently, the diluted sperm was centrifuged at 3000 r/min at 25 °C for 2 min to wash the mature sperm and separate them from the fluid. The sperm pellets were re-suspended with PBS. The sperm

Table 1 Stress induction and treatment in each group

Group	Co-administration (42 consecutive days)	
	Treatment (via orogastric administration)	Stress induction
Control	None	None
CS	DW	IMO (4 h/d)+SM, 15 °C (15 min/d)
PE50+CS	PE extract (50 mg/kg BW)	IMO (4 h/d)+SM, 15 °C (15 min/d)
PE100+CS	PE extract (100 mg/kg BW)	IMO (4 h/d)+SM, 15 °C (15 min/d)

CS: chronic stress; PE: *Phyllanthus emblica* L.; DW: distilled water; BW: body weight; IMO: immobilization; SM: swimming

suspension was dropped on a Neubauer counting chamber and covered by a glass slip. The number of sperm cells was counted under a light microscope (Nikon ECLIPSE E200, Japan) and examined in triplicate (Iamsaard et al., 2013). The sum number of sperm cells was calculated as a concentration (10^6 cells/ml).

To examine sperm head abnormalities, the diluted sperm suspension was smeared on a slide and dried in a hot air oven at 50 °C. The dried sperm were then fixed with methyl alcohol for 20 min and stained using H&E (Sakr et al., 2014; Arun et al., 2016a, 2016b). After washing, the stained sperm were dehydrated using graded alcohol for 5 min. Abnormal sperm heads were classified as described by Sakr et al. (2014). Images of all sperm heads were subsequently captured using a Nikon light ECLIPSE E200 microscope equipped with a DXM1200 digital camera. Two hundred sperm heads from each animal were counted and the percentage of cells with abnormal heads was calculated.

2.7 Sperm acrosome reaction assay

The sperm suspensions were smeared on slides and dried at room temperature (RT). The dried sperm were then stained with 0.22% Coomassie Brilliant Blue G 250 (Bio-Rad Laboratories, Inc.) for 5 min. After being washed with distilled water (DW), the stained-tissue slides were mounted using mounting media. Acrosome reacted sperm were observed and classified based on the method of Iamsaard et al. (2013). Sperm with Coomassie Blue staining on the acrosome cap were classified as acrosome intact sperm (IR), whereas sperm without Coomassie Blue staining on acrosome cap were classified as acrosome reacted sperm (AR). Representative acrosome status was captured using a Nikon light ECLIPSE E200 microscope equipped with a DXM1200 digital camera. Two hundred sperm cells were counted. The number of AR sperm was calculated as a percentage.

2.8 Immuno-Western blot assay

Protein extraction was conducted by homogenizing each testis and centrifuging the homogenate at 12000 r/min at 4 °C for 10 min to separate the testicular lysate from the pellet. The total protein concentration of the testicular lysate was measured using a NanoDrop ND-1000 spectrophotometer (NanoDrop Technologies, Inc., USA) at an absorbance of 280 nm.

To examine the testicular expression of StAR and phosphotyrosine proteins, the testicular proteins (80 µg for StAR; 90 µg for anti-phosphotyrosine) were loaded and separated on a 10% (0.1 g/ml) SDS polyacrylamide gel. Separated proteins were transferred to nitrocellulose membranes (for measurement of anti-phosphotyrosine protein) or polyvinylidene difluoride membranes (for measurement of anti-StAR protein). Following this, all membranes were incubated with 5% skim milk in 0.1% PBST (0.1% Tween-20, PBS, pH 7.4) for 1 h to block non-specific binding proteins, and individually incubated with StAR (1:1000 dilution), anti-phosphotyrosine (1:2000 dilution), or β -actin antibody (1:2000 dilution) at 4 °C overnight. After washing, the membranes were incubated with specific secondary antibody conjugated with horseradish peroxidase (HRP) for 1–2 h at RT. The membranes were subsequently washed and examined using an enhanced chemiluminescence (ECL) substrate under a gel doct 4 imaging system (ImageQuant 400, GH Healthcare, USA). To confirm the actual reactivity of the primary antibody, StAR lysate, EGF stimulated A413 cell lysate, or purified β -actin was used as specific a positive control. BSA was used as a negative control. For quantitative analysis, the intensities of protein patterns were measured and analyzed using ImageJ Program (Version 1.49p).

2.9 Malondialdehyde assay

After homogenization, testicular lysate (0.6 ml) was mixed with 0.5 ml of 10% TCA, 0.5 ml of 5 mmol/L ethylenediaminetetraacetic acid (EDTA), 0.2 ml of 8% SDS, and 40 µl of 0.01% BHT. The mixture was incubated for 10 min at RT. After this, 0.5 ml of 0.6% thiobarbituric acid (TBA) was added and mixed. The mixture was then boiled (at 95–100 °C) in a water bath for 30 min. After cooling, the mixture was centrifuged at 1600g for 10 min at RT. The absorbance of the supernatant was measured at 534 nm using a spectrophotometer (Evolution 600, Thermo Scientific, USA). A standard curve was plotted from the appropriate concentrations (10–70 nmol/L) of TEP. The MDA concentration is expressed as nmol/L per mg protein.

2.10 Statistical analysis

The experimental data are expressed as the mean and standard deviation (SD). Statistical comparison

between groups was conducted using a one-way analysis of variance (ANOVA) in SPSS Statistics 19.0 (SPSS Inc., Armonk, New York, USA). Differences with $P < 0.05$ were considered significant.

3 Results and discussion

3.1 Effects of PE leaf extract on serum corticosterone levels

The corticosterone levels of all groups as measured on the final day of the experiment are shown in Fig. 1. The results showed that the corticosterone levels of rats exposed to CS were significantly higher ($P < 0.05$) than those of the control rats. After PE administration, the corticosterone levels in rats in the PE-treated groups (50 and 100 mg/kg BW) were significantly lower ($P < 0.05$) than those of the rats in the CS group (Fig. 1).

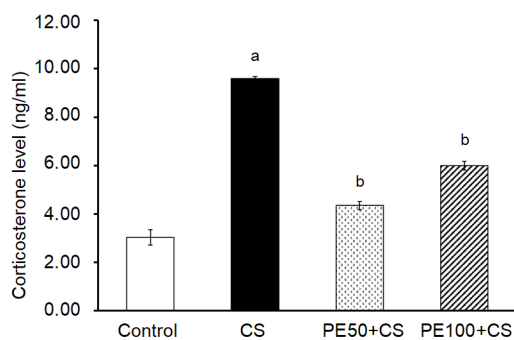


Fig. 1 Effect of oral administration of *Phyllanthus emblica* (PE) leaf extract on the corticosterone levels in rats suffering from chronic stress

CS: chronic stress; PE50 and PE100: PE leaf extract at the doses of 50 and 100 mg/kg BW, respectively. Each bar represents the mean \pm SD ($n=7$). ^a $P < 0.05$ vs. the control group; ^b $P < 0.05$ vs. the CS group

3.2 Effects of PE leaf extract on BW and the morphology of male reproductive organs

During the experimental period, the control, CS, and PE-treated rats did not differ in terms of BW, except at Day 35 (Fig. 2a). Both doses of PE leaf extract slightly increased the testicular size ($(2.01 \pm 0.15) \text{ cm} \times (3.17 \pm 0.12) \text{ cm}$ and $(1.97 \pm 0.06) \text{ cm} \times (3.20 \pm 0.10) \text{ cm}$, respectively) compared to that of rats in the CS group ($(1.57 \pm 0.06) \text{ cm} \times (2.50 \pm 0.17) \text{ cm}$) (Fig. 2b). Such morphometric results were correlated with absolute weight (Table 1). However, there were no significant differences in the size or weight of the penis,

epididymis plus vas deferens, or seminal vesicle plus prostate glands among the control and treated groups (Fig. 2b and Table 2).

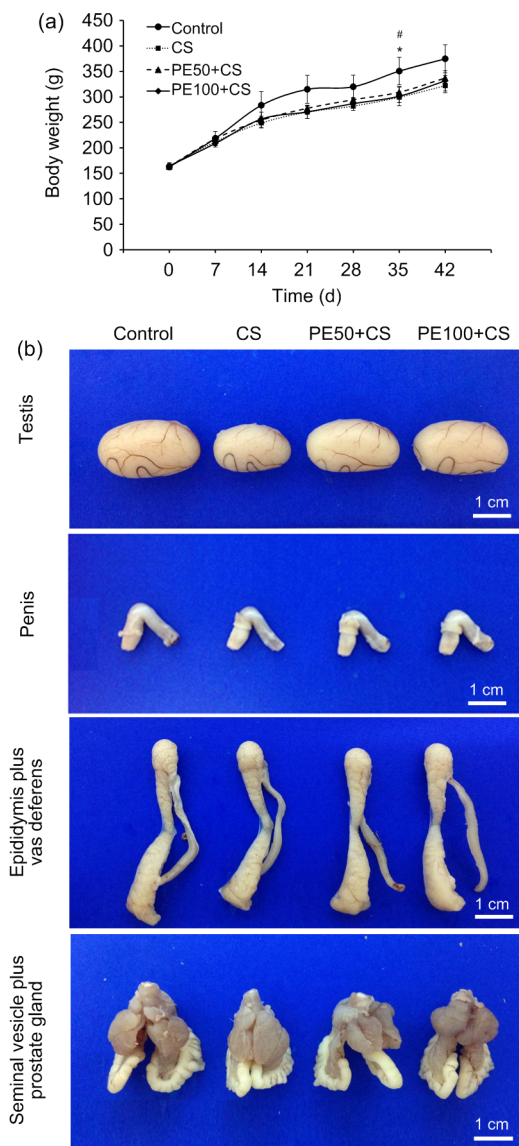


Fig. 2 Changes in body weight at each week of the experiment (a) and photographs comparing the morphological characteristics of the male reproductive organs (b) in the control, CS, PE50+CS, and PE100+CS groups

CS: chronic stress; PE50 and PE100: PE leaf extract at the doses of 50 and 100 mg/kg BW, respectively. Each data point represents the mean \pm SD ($n=7$). ^{*} $P < 0.05$, CS vs. the control group; [#] $P < 0.05$, PE+CS vs. the CS group

3.3 Effects of PE leaf extract on reproductive organ weight, testosterone level, and sperm parameters

The weights of the male reproductive organs in each group are shown in Table 2. Only the CS group

Table 2 Effects of PE leaf extract on male reproductive organ weight, testosterone level, sperm concentration, head abnormality, and acrosome reaction in rats with chronic stress

Group	Testis		Epididymis plus vas deferens		Seminal vesicle plus prostate gland	
	Absolute weight (g)	Relative weight (g/100 g)	Absolute weight (g)	Relative weight (g/100 g)	Absolute weights (g)	Relative weight (g/100 g)
Control	1.93±0.16	0.52±0.01	0.67±0.06	0.16±0.00	1.90±0.14	0.51±0.01
CS	1.50±0.26 ^a	0.48±0.09	0.54±0.05	0.17±0.01	1.86±0.15	0.56±0.03
PE50+CS	1.71±0.11	0.51±0.03	0.56±0.04	0.17±0.01	1.94±0.18	0.57±0.04
PE100+CS	1.64±0.06	0.52±0.06	0.57±0.03	0.18±0.02	1.90±0.24	0.63±0.01

Group	Testosterone level (ng/ml)	Sperm concentration (×10 ⁶ cells/ml)	Sperm head abnormality (%)	Sperm reacted sperm (%)
Control	4.97±1.77	74.50±3.01	2.50±0.97	6.25±2.55
CS	1.02±0.01 ^a	56.28±6.36 ^a	27.44±2.07 ^a	22.14±2.54 ^a
PE50+CS	1.39±0.21 ^b	69.22±7.85 ^b	10.56±2.19 ^b	15.00±2.54 ^b
PE100+CS	1.00±0.04	58.67±1.53	29.67±2.95	20.50±2.08

CS: chronic stress; PE50 and PE100: PE leaf extract at doses of 50 and 100 mg/kg BW, respectively. Data are represented as mean±SD ($n=7$). ^a $P<0.05$ vs. the control group; ^b $P<0.05$ vs. the CS group

showed a significant decrease in absolute testicular weight ($P<0.05$) compared to the control. By contrast, absolute testicular weight in the PE-treated rats was not significantly different from that of rats in the control group (Table 2). Also, there were no differences in the relative weight of the reproductive organs among the four groups (Table 2).

After hormonal analyses (Table 2), the CS group showed a significant decrease in testosterone levels ($P<0.05$) compared to the control group. Interestingly, PE at a dose of 50 mg/kg BW significantly improved testosterone levels ($P<0.05$) in CS rats (Table 2). In addition, the sperm concentration of rats in the PE50 group was significantly higher, and the percentages of cells with abnormal heads and AR sperm were significantly lower ($P<0.05$) than those of rats in the CS group (Table 2).

3.4 Effects of PE leaf extract on the histology of the testes and epididymis

Examination of testicular histopathology revealed that the CS rats had a higher prevalence of atrophic seminiferous tubules (with or without degenerative germ cells), greater vascular dilation, and wider interstitial spaces compared to rats in the control group (Figs. 3a and 3b). Interestingly, we observed rats given a low dose of PE extract (50 mg/kg BW) had less testicular damage than the CS rats (Figs. 3b and 3c). However, some atrophic tubules and wide interstitial spaces were observed in the rats given the higher dose of PE (100 mg/kg BW) (Fig. 3d). Moreover the results showed that the numbers of round cells

within the epididymal lumens of CS rats were higher than those of the control (Figs. 3e and 3f), but were lower in the rats in both PE groups (Figs. 3g and 3h).

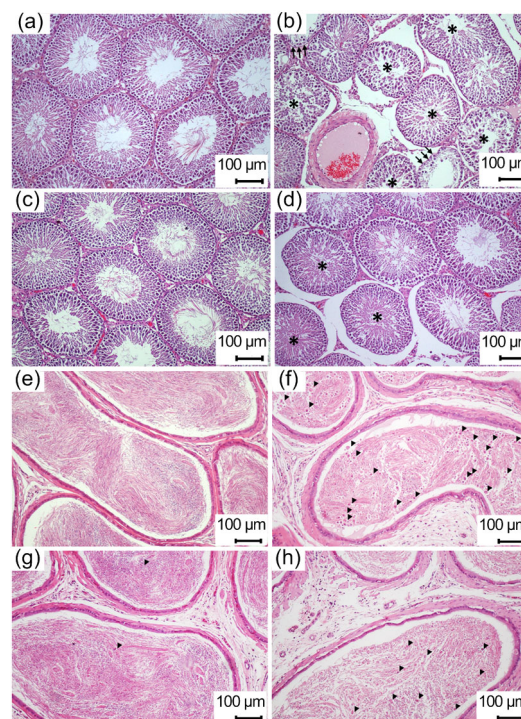


Fig. 3 Representative photomicrographs showing histologies of testes (a–d) and caudal epididymis (e–h) stained with H&E in the control (a, e), CS (b, f), and PE+CS (50 (c, g) and 100 mg/kg BW (d, h)) groups

Asterisks: atrophic seminiferous tubules; arrows: seminiferous tubular atrophy with degenerative germ cells; arrowheads: round cells. Wide interstitial spaces are abundant in the CS group

3.5 Effects of PE leaf extract on malondialdehyde levels

The results demonstrated that both doses of PE (50 and 100 mg/kg BW) significantly reduced ($P < 0.05$) testicular MDA levels in rats subjected to IMO plus swimming stress. By contrast, CS significantly increased ($P < 0.05$) the MDA levels of rat testes (Fig. 4).

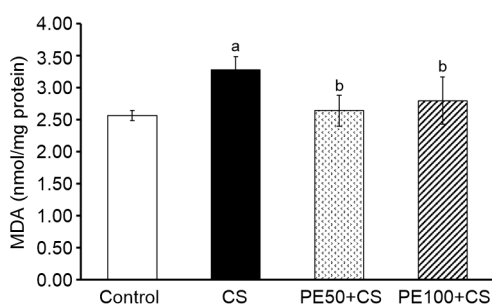


Fig. 4 Effect of PE leaf extract on testicular MDA levels in chronic stress rats

CS: chronic stress; PE50 and PE100: PE leaf extract at doses of 50 and 100 mg/kg BW, respectively. Each bar represents the mean \pm SD ($n=7$). ^a $P < 0.05$ vs. the control group; ^b $P < 0.05$ vs. the CS group

3.6 Effects of PE leaf extract on expression levels of testicular StAR proteins

The expression and intensities of StAR proteins in the testicular lysate of each group are shown in Fig. 5. According to immuno-Western blot analysis, only the rats in the PE50 group exhibited higher StAR expression than those in the CS group (Fig. 5a). This was confirmed by intensity quantification using β -actin as an internal control, which demonstrated that StAR protein expression in the PE50 group (but not in the PE100 group) was significantly higher than that in the CS group ($P < 0.05$; Fig. 5b).

3.7 Effects of PE leaf extract on expression patterns of tyrosine-phosphorylated proteins

The profile of equal testicular proteins ascertained using SDS-polyacrylamide gel electrophoresis (PAGE) was used to confirm the presence of equal amounts of total proteins (Fig. 6a). In all groups, the results of immuno-Western blot analysis showed five major bands of tyrosine-phosphorylated proteins (60, 51, 34, 23, and 14 kDa, respectively; Fig. 6b). Compared to the control, the rats in the CS group had

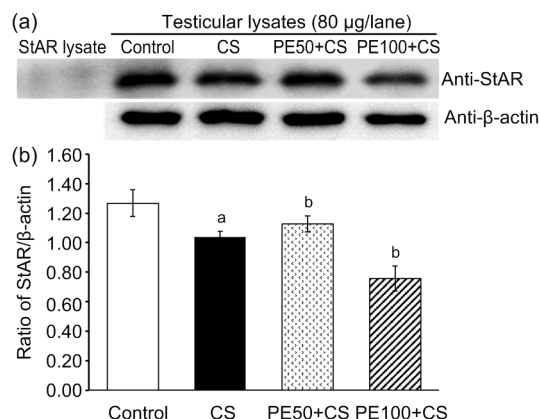


Fig. 5 Representative immuno-Western blot analysis showing the expression of testicular steroidogenic acute regulatory (StAR) protein (a) and the ratio of StAR/ β -actin (b) in chronic stress rats treated with PE leaf extract

StAR lysate and β -actin were used as positive and internal controls, respectively. Each bar represents the mean \pm SD ($n=7$). ^a $P < 0.05$ vs. the control group; ^b $P < 0.05$ vs. the CS group

markedly higher expression of tyrosine-phosphorylated proteins of 60, 51, and 23 kDa, but lower expression of those of 34 and 14 kDa in the (Fig. 6b). Pretreatment with PE (50 mg/kg BW) resulted in decreases in the expression of 60, 51, and 23 kDa proteins and increased expression of 34 and 14 kDa proteins in CS testes (Fig. 6b). Also, all testicular phosphorylated protein expression in PE100 rats was lower than that in the CS rats (Figs. 6b and 6c).

4 Discussion

The present study has demonstrated that the leaf extract of PE could ameliorate testicular impairments in rats with CS. The administration of PE extract prevented increases in testicular MDA levels, seminiferous tubular damage, decreases in testosterone levels, and a reduction of sperm quality that can result from stress. This study was consistent with previous reports which have shown that many parts of PE extracts may also prevent many types of drug/chemical-induced tissue injuries, including those in the stomach (Bandyopadhyay et al., 2000), liver (Pramyothin et al., 2006; Lu et al., 2016; Huang et al., 2017), kidneys (Khandelwal et al., 2002), and testes (Verma and Chakraborty, 2008; Iamsaard et al., 2015) in animals.

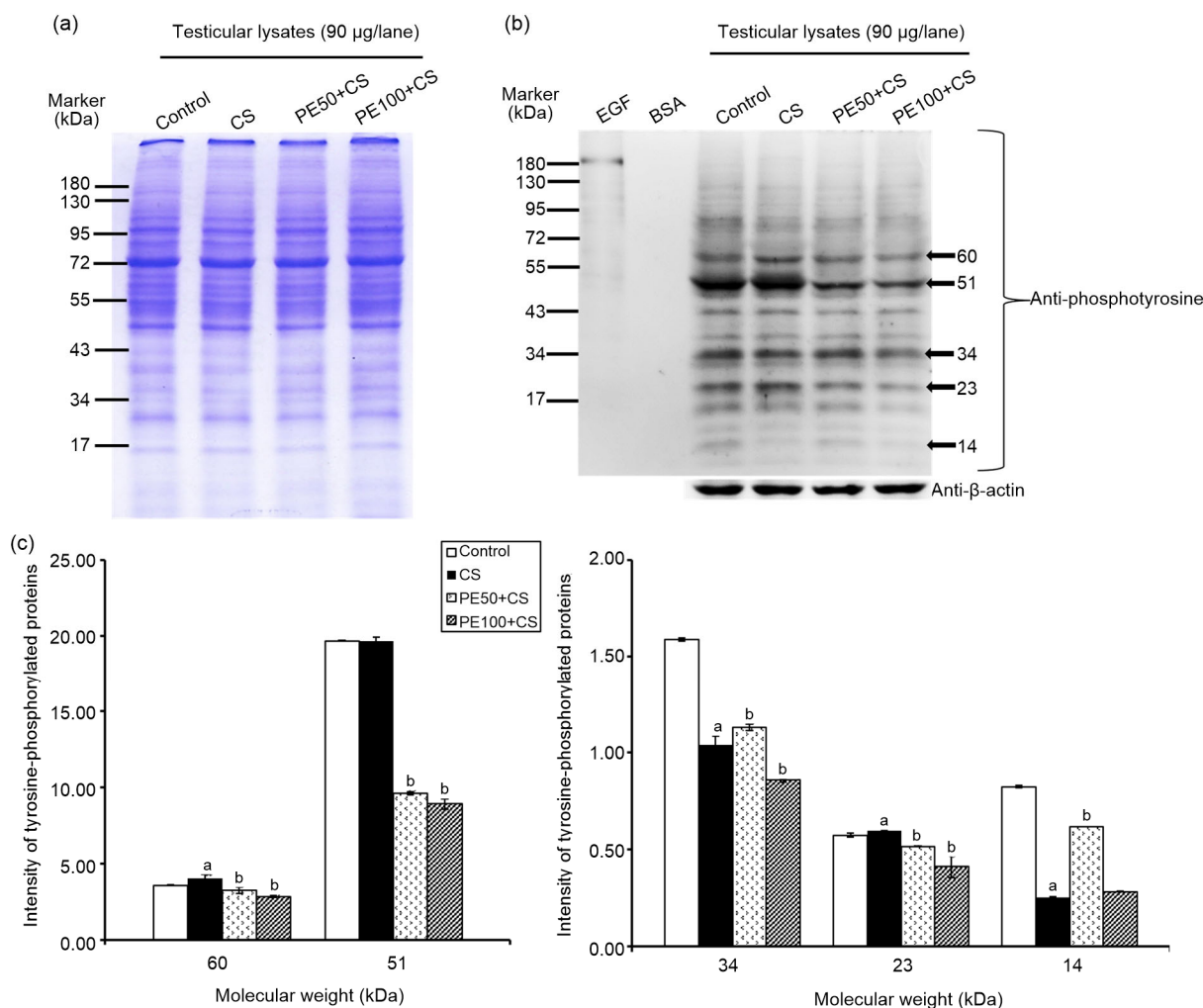


Fig. 6 Representative Coomassie Blue-stained protein profiles (a), patterns of testicular tyrosine-phosphorylated proteins according to immuno-Western blot analysis (b), and intensities of 60, 51, 34, 23, and 14 kDa phosphorylated proteins (c) in the control, CS, and PE+CS (50 and 100 mg/kg BW) groups

Epidermal growth factor (EGF) and bovine serum albumin (BSA) were used as positive and negative controls, respectively. β-Actin was used as an internal control. Each bar represents the mean ± SD ($n=7$). ^a $P < 0.05$ vs. the control group; ^b $P < 0.05$ vs. the CS group

For the first time, this study showed that PE exhibits protective effects against testicular damage in rats exposed to long-term stress. It is known that corticosterone levels are elevated under stress induced by excess ROS, leading to increased MDA levels and tissue injury (Bhatia et al., 2011; Prabsattroo et al., 2015; Arun et al., 2016a, 2016b). Some natural products and plants have been developed and used as alternative medicines to diminish stress by reducing the levels of cortisol and oxidants (Bitgul et al., 2013; Xu et al., 2014; Prabsattroo et al., 2015; Lee et al., 2017). Consistent with previous reports, we found that PE leaf extract significantly reduced corticosterone and testicular MDA levels in rats subjected to

restraint (Figs. 1 and 4). This may be explained by the fact that, as we have previously reported (Iamsaard et al., 2014, 2015), PE at this concentration has a high phenolic content and antioxidant capacity. In addition, PE has been shown to increase superoxide dismutase (SOD), catalase (CAT), and glutathione peroxidase (GSH-Px) in damaged tissue (Bandyopadhyay et al., 2000; Saha and Verma, 2015; Tahir et al., 2016). It is possible that PE extract exhibits antioxidant activity that can prevent or reduce stress, resulting in the protection of testicular histopathology (Figs. 3a–3d and 4). Correlated with improvement in testicular histopathology, rats suffering from CS that were given PE extracts (especially at 50 mg/kg BW)

exhibited decreases in round cells within the epididymal lumens (Figs. 3e–3h), a finding similar to that described by Iamsaard et al. (2015).

Reductions in the testosterone levels of rats under stress have been shown to be caused by low expression levels of crucial steroidogenic machinery in Leydig cells, such as StAR, CYP11A1, and hydroxysteroid dehydrogenase (Lin et al., 2014; Arun et al., 2016a, 2016b). In this study, a low dose of PE extract was able to prevent low expression of StAR protein in CS testes, indicating that StAR expression is correlated with improvement in testosterone levels. Consequently, such prevention and treatments maintained normal spermatogenesis via normal testosterone production. In addition, normal testis function may be associated with tyrosine phosphorylation. This intracellular process is a kind of post-translational modification that has been shown to be involved in many biological and physiological processes especially spermatogenesis, sperm capacitation, and acrosome reaction (Hunter and Cooper, 1985; Hanks et al., 1988; Ullrich and Schlessinger, 1990; Yanagimachi, 1994; Visconti and Kopf, 1998). Specifically, many tyrosine-phosphorylated proteins have been identified and localized in the Leydig cells, Sertoli cells, spermatogonia, spermatocytes, and spermatids (round and elongated) of rat testes (Chaichun et al., 2017). Previous reports have demonstrated that the patterns of expression of testicular tyrosine-phosphorylated proteins can change with the induction of drugs or other chemicals (Iamsaard et al., 2014, 2015; Sampannang et al., 2017; Sukhorum and Iamsaard, 2017; Maneenin et al., 2018). In addition, in a previous study, we demonstrated the alteration of phosphorylated protein bands in the testes of rats with restraint-induced stress (Arun et al., 2016a, 2016b). A recent study showed that PE leaf extracts could change such expression patterns in rats suffering from CS compared to healthy control rats. Although testicular tyrosine-phosphorylated proteins specific to the actual function of 4G10-antibodies have not been discovered, we assume that they may play an important role in androgen production, spermatogenesis, and sperm differentiation within germinal epithelium and interstitial tissue cells (Arad-Dann et al., 1993; Chaichun et al., 2017). Therefore, the decreases in tyrosine-phosphorylated proteins of 60, 51, and 23 kDa and increases of 34 and 14 kDa proteins in rat

testes treated with PE may be involved in sperm production, including acrosome biogenesis, as part of the spermiogenesis process of spermatids. This could explain why the PE extract was able to prevent sperm head abnormalities and precocious acrosome reaction, as well as increase sperm concentration in the CS rats (Table 2). In the same vein, previous studies have reported that plant extracts can change the expression of the testicular phosphorylated proteins in animals administered with drugs such as valproic acid (VPA) (Iamsaard et al., 2014, 2015; Sampannang et al., 2017; Maneenin et al., 2018). However, systematic identification and characterization of such phosphorylated proteins are necessary to understand the actual function or mechanism involved in this process. Our results indicate that PE at a dose of 50 mg/kg BW is effective in mitigating the effects of CS on sperm quality parameters through the restoration of StAR protein, MDA levels, and testicular phosphorylated proteins. However, PE100 did not protect such parameters in CS rats. The high dose of PE (100 mg/kg BW) may contain some toxic substances, since it was extracted in the form of a crude extract. It was previously reported that PE crude extracts contain toxic cellular components like tannins and saponins (Calixto et al., 1998; Al-Shafi, 2002; Podolak et al., 2010; Akinpelu et al., 2012; Chaphalkar et al., 2017). Therefore, the high amount of such toxins included within the PE100 extract may affect the structure and function of reproductive cells resulting in changes in the expression of testicular proteins including increases in MDA levels and testicular damage.

Thus, we conclude that PE leaf extract attenuates testicular damage by preventing low sperm quality and changes to functional proteins, especially testicular tyrosine-phosphorylated proteins, in rats with CS.

Compliance with ethics guidelines

Supatcharee ARUN, Jaturon BURAWAT, Supataechasit YANNASITHINON, Wannisa SUKHORUM, Akgpol LIM-PONGSA, and Sithichai IAMSAARD declare that they have no conflicts interest.

All institutional and national guidelines for the care and use of laboratory animals were followed.

References

Akinpelu BA, Oyedapo OO, Iwalewa EO, et al., 2012. Biochemical and histopathological profile of toxicity induced

- by saponin fraction of *Erythrophleum suaveolens* (Guill. & Perri.) bark extract. *Phytopharmacology*, 3(1):38-53.
- Al-Shafi SM, 2002. Toxic effect of tannic and related compounds on human plasma proteins. *Saudi Med J*, 23(2): 221-225.
- Arad-Dann H, Beller U, Haimovitch R, et al., 1993. Immunohistochemistry of phosphotyrosine residues: identification of distinct intracellular patterns in epithelial and steroidogenic tissues. *J Histochem Cytochem*, 41(4):513-519.
<https://doi.org/10.1177/41.4.7680679>
- Arun S, Burawat J, Sukhorum W, et al., 2016a. Changes of testicular phosphorylated proteins in response to restraint stress in male rats. *J Zhejiang Univ-Sci B (Biomed & Biotechnol)*, 17(1):21-29.
<https://doi.org/10.1631/jzus.B1500174>
- Arun S, Burawat J, Sukhorum W, et al., 2016b. Chronic restraint stress induces sperm acrosome reaction and changes in testicular tyrosine phosphorylated proteins in rats. *Int J Reprod Biomed (Yazd)*, 14(7):443-452.
- Aziz NM, Ragy MM, Gayyed MF, 2013. Effect of acute immobilization stress with or without a heme oxygenase inducer on testicular structure and function in male albino rats. *J Basic Clin Physiol Pharmacol*, 24(4):255-462.
<https://doi.org/10.1515/jbcpp-2012-0066>
- Bandyopadhyay SK, Pakrashi SC, Pakrashi A, 2000. The role of antioxidant activity of *Phyllanthus emblica* fruits on prevention from indomethacin induced gastric ulcer. *J Ethnopharmacol*, 70(2):171-176.
[https://doi.org/10.1016/S0378-8741\(99\)00146-4](https://doi.org/10.1016/S0378-8741(99)00146-4)
- Bhatia N, Jaggi AS, Singh N, et al., 2011. Adaptogenic potential of curcumin in experimental chronic stress and chronic unpredictable stress-induced memory deficits and alterations in functional homeostasis. *J Nat Med*, 65(3-4): 532-543.
<https://doi.org/10.1007/s11418-011-0535-9>
- Bitgul G, Tekmen I, Keles D, et al., 2013. Protective effects of resveratrol against chronic immobilization stress on testis. *ISRN Urol*, 2013:278720.
<https://doi.org/10.1155/2013/278720>
- Calixto JB, Santos ARS, Filho CV, et al., 1998. A review of the plants of the genus *Phyllanthus*: their chemistry, pharmacology, and therapeutic potential. *Med Res Rev*, 18(4):225-258.
[https://doi.org/10.1002/\(SICI\)1098-1128\(199807\)18:4<225::AID-MED2>3.0.CO;2-X](https://doi.org/10.1002/(SICI)1098-1128(199807)18:4<225::AID-MED2>3.0.CO;2-X)
- Chaichun A, Arun S, Burawat J, et al., 2017. Localization and identification of tyrosine phosphorylated proteins in adult sprague-dawley rat testis. *Int J Morphol*, 35(4):1322-1327.
<https://doi.org/10.4067/S0717-95022017000401322>
- Chaphalkar R, Apte KG, Talekar Y, et al., 2017. Antioxidants of *Phyllanthus emblica* L. Bark extract provide hepatoprotection against ethanol-induced hepatic damage: a comparison with silymarin. *Oxid Med Cell Longev*, 2017: 3876040.
<https://doi.org/10.1155/2017/3876040>
- Dhanabalan S, Jubendradass R, Latha P, et al., 2010. Effect of restraint stress on 2,3,7,8 tetrachloro dibenzo-*p*-dioxin induced testicular and epididymal toxicity in rats. *Hum Exp Toxicol*, 30(7):567-578.
<https://doi.org/10.1177/0960327110376548>
- Everds NE, Snyder PW, Bailey KL, et al., 2013. Interpreting stress responses during routine toxicity studies: a review of the biology, impact, and assessment. *Toxicol Pathol*, 41(4):560-614.
<https://doi.org/10.1177/0192623312466452>
- Hanks SK, Quinn AM, Hunter T, 1988. The protein kinase family: conserved features and deduced phylogeny of the catalytic domains. *Science*, 241(4861):42-52.
<https://doi.org/10.1126/science.3291115>
- Huang CZ, Tung YT, Hsia SM, et al., 2017. The hepatoprotective effect of *Phyllanthus emblica* L. fruit on high fat diet-induced non-alcoholic fatty liver disease (NAFLD) in SD rats. *Food Funct*, 8(2):842-850.
<https://doi.org/10.1039/C6FO01585A>
- Hunter T, Cooper JA, 1985. Protein-tyrosine kinases. *Annu Rev Biochem*, 54(1):897-930.
<https://doi.org/10.1146/annurev.bi.54.070185.004341>
- Iamsaard S, Prabsattroo T, Sukhorum W, et al., 2013. *Anethum graveolens* Linn. (dill) extract enhances the mounting frequency and level of testicular tyrosine protein phosphorylation in rats. *J Zhejiang Univ-Sci B (Biomed & Biotechnol)*, 14(3):247-252.
<https://doi.org/10.1631/jzus.B1200287>
- Iamsaard S, Arun S, Burawat J, et al., 2014. Phenolic contents and antioxidant capacities of Thai-Makhnam Pom (*Phyllanthus emblica* L.) aqueous extracts. *J Zhejiang Univ-Sci B (Biomed & Biotechnol)*, 15(4):405-408.
<https://doi.org/10.1631/jzus.B1300284>
- Iamsaard S, Arun S, Burawat J, et al., 2015. *Phyllanthus emblica* L. branch extract ameliorates testicular damage in valproic acid-Induced rats. *Int J Morphol*, 33(3):1016-1022.
<https://doi.org/10.4067/S0717-95022015000300033>
- Iamsaard S, Welbat JU, Sukhorum W, et al., 2018. Methotrexate changes the testicular tyrosine phosphorylated protein expression and seminal vesicle epithelia of adult rats. *Int J Morphol*, 36(2):737-742.
<https://doi.org/10.4067/S0717-95022018000200737>
- İzgüt-Uysal VN, Gemici B, Birsen İ, et al., 2014. The protective effect of apelin against water-immersion and restraint stress-induced gastric damage. *J Physiol Sci*, 64(4):279-289.
<https://doi.org/10.1007/s12576-014-0317-8>
- Khandelwal S, Shukla LJ, Shanker R, 2002. Modulation of acute cadmium toxicity by *emblica officinalis* fruit in rat. *Indian J Exp Biol*, 40(5):564-570.
- Krishnaveni M, Mirunalini S, 2012. Chemopreventive efficacy of *Phyllanthus emblica* L. (amla) fruit extract on 7,12-dimethylbenz(a)anthracene induced oral carcinogenesis—a dose-response study. *Environ Toxicol Pharmacol*, 34(3): 801-810.
<https://doi.org/10.1016/j.etap.2012.09.006>
- Kummerdkhonkaen P, Saenglee S, Asgar MA, et al., 2018.

- Antiproliferative activities and phenolic acid content of water and ethanolic extracts of the powdered formula of *Houttuynia cordata* Thunb. Fermented broth and *Phyllanthus emblica* Linn. Fruit. *BMC Complement Altern Med*, 18:130.
<https://doi.org/10.1186/s12906-018-2185-x>
- Lee SH, Choi KH, Cha KM, et al., 2017. Protective effects of Korean Red Ginseng against sub-acute immobilization stress-induced testicular damage in experimental rats. *J Ginseng Res*, in press.
<https://doi.org/10.1016/j.jgr.2017.09.002>
- Lin H, Yuan KM, Zhou HY, et al., 2014. Time-course changes of steroidogenic gene expression and steroidogenesis of rat Leydig cells after acute immobilization stress. *Int J Mol Sci*, 15(11):21028-21044.
<https://doi.org/10.3390/ijms151121028>
- Liu XL, Cui C, Zhao MM, et al., 2008. Identification of phenolics in the fruit of emblica (*Phyllanthus emblica* L.) and their antioxidant activities. *Food Chem*, 109(4):909-915.
<https://doi.org/10.1016/j.foodchem.2008.01.071>
- Lu CC, Yang SH, Hsia SM, et al., 2016. Inhibitory effects of *Phyllanthus emblica* L. on hepatic steatosis and liver fibrosis *in vitro*. *J Funct Foods*, 20:20-30.
<https://doi.org/10.1016/j.jff.2015.10.012>
- Luo W, Zhao MM, Yang B, et al., 2011. Antioxidant and antiproliferative capacities of phenolics purified from *Phyllanthus emblica* L. fruit. *Food Chem*, 126(1):277-282.
<https://doi.org/10.1016/j.foodchem.2010.11.018>
- Maneenin C, Burawat J, Maneenin N, et al., 2018. Antioxidant capacity of *Momordica charantia* extract and its protective effect on testicular damage in valproic acid-induced rats. *Int J Morphol*, 36(2):447-453.
<https://doi.org/10.4067/S0717-95022018000200447>
- Matsuura N, Nagasawa K, Minagawa Y, et al., 2015. Restraint stress exacerbates cardiac and adipose tissue pathology via β -adrenergic signaling in rats with metabolic syndrome. *Am J Physiol Heart Circ Physiol*, 308(10):H1275-H1286.
- Naninck EFG, Hoeijmakers L, Kakava-Georgiadou N, et al., 2015. Chronic early life stress alters developmental and adult neurogenesis and impairs cognitive function in mice. *Hippocampus*, 25(3):309-328.
<https://doi.org/10.1002/hipo.22374>
- Pertsov SS, Koplík EV, Kalinichenko LS, 2015. Effect of interleukin-4 on peripheral blood leukocytes in rats with various behavioral characteristics during acute stress. *Bull Exp Biol Med*, 158(5):595-599.
<https://doi.org/10.1007/s10517-015-2814-z>
- Podolak I, Galanty A, Sobolewska D, 2010. Saponins as cytotoxic agents: a review. *Phytochem Rev*, 9(3):425-474.
<https://doi.org/10.1007/s11101-010-9183-z>
- Popović N, Pajović SB, 2010. Lithium modulates the chronic stress-induced effect on blood glucose level of male rats. *Arch Biol Sci*, 62(2):289-295.
<https://doi.org/10.2298/ABS1002289P>
- Prabsattroo T, Wattanathorn J, Iamsaard S, et al., 2015. *Moringa oleifera* extract enhances sexual performance in stressed rats. *J Zhejiang Univ-Sci B (Biomed & Biotechnol)*, 16(3):179-190.
<https://doi.org/10.1631/jzus.B1400197>
- Pramyothin P, Samosorn P, Pongshompoo S, et al., 2006. The protective effects of *Phyllanthus emblica* Linn. extract on ethanol induced rat hepatic injury. *J Ethnopharmacol*, 107(3):361-364.
<https://doi.org/10.1016/j.jep.2006.03.035>
- Priya PH, Reddy PS, 2012. Effect of restraint stress on lead-induced male reproductive toxicity in rats. *J Exp Zool A Ecol Genet Physiol*, 317(7):455-465.
<https://doi.org/10.1002/jez.1738>
- Rai J, Pandey SN, Srivastava RK, 2003. Effect of immobilization stress on spermatogenesis of albino rats. *J Anat Soc India*, 52(1):55-57.
- Rai J, Pandey SN, Srivastava RK, 2004. Testosterone hormone level in albino rats following restraint stress of long duration. *J Anat Soc India*, 53(1):17-19.
- Rao M, Zhao XL, Yang J, et al., 2015. Effect of transient scrotal hyperthermia on sperm parameters, seminal plasma biochemical markers, and oxidative stress in men. *Asian J Androl*, 17(4):668-675.
<https://doi.org/10.4103/1008-682X.146967>
- Reis DG, Scopinho AA, Guimarães FS, 2011. Behavioral and autonomic responses to acute restraint stress are segregated within the lateral septal area of rats. *PLoS ONE*, 6(8):e23171.
<https://doi.org/10.1371/journal.pone.0023171>
- Retana-Márquez S, Bonilla-Jaime H, Vázquez-Palacios G, et al., 2003. Changes in masculine sexual behavior, corticosterone and testosterone in response to acute and chronic stress in male rats. *Horm Behav*, 44(4):327-337.
<https://doi.org/10.1016/j.yhbeh.2003.04.001>
- Richburg JH, 2000. The relevance of spontaneous- and chemically-induced alterations in testicular germ cell apoptosis to toxicology. *Toxicol Lett*, 112-113:79-86.
[https://doi.org/10.1016/S0378-4274\(99\)00253-2](https://doi.org/10.1016/S0378-4274(99)00253-2)
- Saha S, Verma RJ, 2015. Antioxidant activity of polyphenolic extract of *Phyllanthus emblica* against lead acetate induced oxidative stress. *Toxicol Environ Health Sci*, 7(1):82-90.
<https://doi.org/10.1007/s13530-015-0224-2>
- Sakr SA, Zowail ME, Marzouk AM, 2014. Effect of saffron (*Crocus sativus* L.) on sodium valproate induced cytogenetic and testicular alterations in albino rats. *Anat Cell Biol*, 47(3):171-179.
<https://doi.org/10.5115/acb.2014.47.3.171>
- Sampannang A, Arun S, Sukhorum W, et al., 2017. Antioxidant and hypoglycemic effects of *Momordica cochinchinensis* Spreng. (Gac) aril extract on reproductive damages in streptozotocin (STZ)-induced hyperglycemia mice. *Int J Morphol*, 35(2):667-675.
<https://doi.org/10.4067/S0717-95022017000200046>
- Sawant L, Pandita N, Prabhakar B, 2010. Determination of gallic acid in *Phyllanthus emblica* Linn. Dried fruit

- powder by HPTLC. *J Pharm Bioallied Sci*, 2(2):105-108. <https://doi.org/10.4103/0975-7406.67012>
- She GM, Cheng RY, Sha L, et al., 2013. A novel phenolic compound from *Phyllanthus emblica*. *Nat Prod Commun*, 8(4):461-462.
- Srinivasan P, Vijayakumar S, Kothandaraman S, et al., 2018. Anti-diabetic activity of quercetin extracted from *Phyllanthus emblica* L. fruit: *in silico* and *in vivo* approaches. *J Pharm Anal*, 8(2):109-118. <https://doi.org/10.1016/j.jpha.2017.10.005>
- Sripanidkulchai B, Junlatat J, 2014. Bioactivities of alcohol based extracts of *Phyllanthus emblica* branches: antioxidant, antimelanogenesis and anti-inflammation. *J Nat Med*, 68(3):615-622. <https://doi.org/10.1007/s11418-014-0824-1>
- Sukhorum W, Iamsaard S, 2017. Changes in testicular function proteins and sperm acrosome status in rats treated with valproic acid. *Reprod Fertil Dev*, 29(8):1585-1592. <https://doi.org/10.1071/RD16205>
- Tahir I, Khan MR, Shah NA, et al., 2016. Evaluation of phytochemicals, antioxidant activity and amelioration of pulmonary fibrosis with *Phyllanthus emblica* leaves. *BMC Complement Altern Med*, 16:406. <https://doi.org/10.1186/s12906-016-1387-3>
- Tasanarong A, Kongkham S, Itharat A, 2014. Antioxidant effect of *Phyllanthus emblica* extract prevents contrast-induced acute kidney injury. *BMC Complement Altern Med*, 14:138. <https://doi.org/10.1186/1472-6882-14-138>
- Toyang NJ, Ateh EN, Keiser J, et al., 2012. Toxicity, antimicrobial and anthelmintic activities of *Vernonia guineensis* Benth. (Asteraceae) crude extracts. *J Ethnopharmacol*, 144(3):700-704. <https://doi.org/10.1016/j.jep.2012.10.016>
- Ullrich A, Schlessinger J, 1990. Signal transduction by receptors with tyrosine kinase activity. *Cell*, 61(2):203-212. [https://doi.org/10.1016/0092-8674\(90\)90801-K](https://doi.org/10.1016/0092-8674(90)90801-K)
- Verma R, Chakraborty D, 2008. *Emblica officinalis* aqueous extract ameliorates ochratoxin-induced lipid peroxidation in the testis of mice. *Acta Pol Pharm*, 65(2):187-194.
- Visconti PE, Kopf GS, 1998. Regulation of protein phosphorylation during sperm capacitation. *Biol Reprod*, 59(1):1-6. <https://doi.org/10.1095/biolreprod59.1.1>
- Xu ML, Wei QW, Zheng KZ, et al., 2014. Protective effects of Big-leaf mulberry and physiological roles of nitric oxide synthases in the testis of mice following water immersion and restraint stress. *Acta Histochem*, 116(8):1323-1330. <https://doi.org/10.1016/j.acthis.2014.08.003>
- Yanagimachi R, 1994. Mammalian fertilization. In: Knobil E (Ed.), *The Physiology of Reproduction*. Raven Press, New York, p.189-317.
- Zhang MH, Shi ZD, Yu JC, et al., 2015. Scrotal heat stress causes sperm chromatin damage and cysteinyl aspartate-specific proteinases 3 changes in fertile men. *J Assist Reprod Genet*, 32(5):747-755. <https://doi.org/10.1007/s10815-015-0451-0>
- Zhao TJ, Sun Q, Marques M, et al., 2015. Anticancer properties of *Phyllanthus emblica* (Indian Gooseberry). *Oxid Med Cell Longev*, 2015:950890. <https://doi.org/10.1155/2015/950890>
- Zhong ZG, Wu DP, Huang JL, et al., 2011. Progallin A isolated from the acetic ether part of the leaves of *Phyllanthus emblica* L. induces apoptosis of human hepatocellular carcinoma BEL-7404 cells by up-regulation of Bax expression and down-regulation of Bcl-2 expression. *J Ethnopharmacol*, 133(2):765-772. <https://doi.org/10.1016/j.jep.2010.11.001>

中文概要

题目: *Phyllanthus emblica* 叶提取物对慢性应激大鼠睾丸损伤有改善作用

目的: 探讨 *Phyllanthus emblica* L. (PE) 叶提取物对慢性应激大鼠睾丸损伤和相关蛋白标志物变化的影响。

方法: 将成年雄性大鼠分成四组: 对照组、慢性应激 (CS) 组和两组 PE 提取物治疗组 (50 或 100 mg/kg 体重 (BW))。对各组的精子质量、睾丸和尾附睾的组织学特征、以及血清皮质酮、睾酮和丙二醛 (MDA) 的水平进行分析比较。并使用免疫印迹分析研究睾丸类固醇合成快速调节蛋白 (StAR) 和酪氨酸磷酸化蛋白的表达。

结论: 结果显示, 50 mg/kg BW 的 PE 能显著增加精子浓度和睾酮水平, 同时降低 CS 大鼠中皮质酮水平、MDA 水平、以及精子头异常和顶体反应精子的比例。此外, 两种剂量的 PE 都能缓解 CS 大鼠的睾丸组织病理学特征。同时我们还发现, 50 mg/kg BW 的 PE 可以显著提高 StAR 蛋白的表达, 并改变睾丸中部分酪氨酸磷酸化蛋白的强度。总之, 50 mg/kg BW 的 PE 叶提取物可以预防 CS 大鼠的睾丸损伤。

关键词: *Phyllanthus emblica* L. 叶提取物; 慢性应激; 睾丸损伤; 酪氨酸磷酸化