Journal of Zhejiang University-SCIENCE B (Biomedicine & Biotechnology) in press
www.jzus.zju.edu.cn; www.springer.com/journal/11585
E-mail: jzus_b@zju.edu.cn

Correspondence

https://doi.org/10.1631/jzus.B2300765

Repetitive transcranial magnetic stimulation combined with imaginal exposure therapy for adolescents with acute stress disorder: case report

Miaomiao ZhAO[1,2,3], Ying LI[1,2,3], Haoyang ZHAO[1,2,3], Chaonan JIANG[1,2,3],Manli HUANG[1,2,3]✉

[1]*Department of Psychiatry, The First Affiliated Hospital, Zhejiang University School of Medicine; Key Laboratory of Mental Disorder's Management of Zhejiang Province, Hangzhou, 310003, China*
[2]*Brain Research Institute of Zhejiang University, Hangzhou, 310003, China*
[3]*Zhejiang Engineering Center for Mathematical Mental Health, Hangzhou, 310003, China*

Acute stress disorder (ASD) is a transient psychiatric disorder that may arise subsequent to abrupt, extreme trauma exposure, and serves as a reliable indicator for the subsequent development of posttraumatic stress disorder (PTSD)(Bryant, 2011; Battle, 2013). It exhibits rapid progression in the aftermath of trauma and persists for a duration of days or weeks (not exceeding one month), manifesting symptoms of dissociation, re-experiencing, avoidance, and hyperarousal (Bielas et al., 2018). In the absence of efficacious and prompt intervention, ASD is linked to substantial morbidity and functional impairment (Mclean et al., 2022a). However, there is a deficiency in terms of providing sensitive diagnosis and effective treatment for adolescents diagnosed with ASD, with the majority of current approaches being derived from PTSD treatment. The prevailing strategies for addressing PTSD in children and young individuals primarily involve psychological intervention and pharmaceuticals, including selective serotonin reuptake inhibitors (SSRIs) (Smith et al., 2013). Nevertheless, the efficacy of SSRIs in adolescents with ASD remains suboptimal (Robb et al., 2010; Locher et al., 2017; Boaden et al., 2020).

Psychotherapy continues to be the preferred and efficacious intervention for adolescents suffering from PTSD. Recent research has indicated that cognitive behavioral therapy (CBT) administered during the during the acute phase can effectively mitigate the development of subsequent PTSD (Bryant, 2018). Consequently, early intervention in the aftermath of trauma is imperative, and the dearth of treatment options for ASD and PTSD necessitates immediate resolution.

Successful application of exposure therapy in treating PTSD has demonstrated the potential for symptom amelioration (Mclean et al., 2022b). This trauma-focused treatment modality encompasses imaginal exposure (Mclean, et al., 2022a). In a controlled environment, patients were subjected to imaginal exposure, wherein memories of traumatic events were intentionally recalled, resulting in desensitization to the events and the subjects' realization that they were no longer at risk (Kaczkurkin and Foa, 2015). Consequently, the patients experienced relaxation and a gradual improvement in their anxiety and/or fear associated with the traumatic

✉ Manli HUANG, huangmanli@zju.edu.cn
Manli HUANG, https://orcid.org/0000-0002-0853-0386
Miaomiao ZHAO, https://orcid.org/0009-0004-6678-7341

Received Oct. 19, 2023; Revision accepted Feb. 20, 2024;
Crosschecked xxx. xx, 20xx; Published online xxx. xx, 20xx

© Zhejiang University Press 2024

unedited

memories. This trauma-focused treatment has been deemed secure, efficacious, and highly viable for children and adolescents diagnosed with post-traumatic stress disorder (PTSD), offering the potential for early intervention.(Smith, et al., 2013).

Repetitive transcranial magnetic stimulation (rTMS), a non-invasive neurostimulation technique based on electromagnetic induction, is employed in this context; it is widely used in treating psychiatric disorders, especially major depressive disorder(George et al., 2010; Gaynes et al., 2014). Several studies in functional neuroimaging have found an elevation in oxygen perfusion within the right prefrontal cortex when individuals with PTSD were exposed to reminders of their traumatic experiences (Herringa, 2017). This finding has led to a prevailing interpretation that heightened activity in the right hemisphere of PTSD patients is associated with involvement of the right hemisphere in anxiety and other negative emotional experiences (Simmons et al., 2004; Milad et al., 2006). Moreover, most investigations on repetitive transcranial magnetic stimulation (rTMS) for PTSD have targeted the right prefrontal cortex(Kozel, 2018), specifically the right dorsolateral prefrontal cortex (DLPFC), which is known to be sensitive to non-verbal affective content and has been implicated in anxiety disorders, fear, and PTSD(White et al., 2023). Previous research has indicated that low- and high-frequency rTMS yield contrasting outcomes, with low-frequency rTMS exhibiting a propensity to reduce cortical excitability, thereby potentially serving as a more efficacious intervention for PTSD (George et al., 2000; Hoffman and Cavus, 2002; Huang et al., 2004). Nevertheless, it has also been reported that high-frequency stimulation demonstrated greater effectiveness(Iglesias, 2020). Furthermore, an additional study elucidated that the therapeutic benefits of low-frequency stimulation were observed as a result of the partial inhibition of lateralized right-sided hyperactivity within the DLPFC (Berlim and Van Den Eynde, 2014). Numerous recent clinical trials have indicated that rTMS holds promise as an intervention for alleviating symptoms associated with PTSD, including anxiety and fear memory (Osuch et al., 2009; Kozel et al., 2019; Philip et al., 2019); but further research is necessary to establish precise treatment parameters, duration, and potential side effects. It is worth noting that several studies have only employed rTMS treatment, which typically spans a duration of 4-6 weeks (Osuch, et al., 2009; Kozel, et al., 2019; Philip, et al., 2019). Therefore, the efficacy and rationality of employing low-frequency rTMS for treating PTSD are recognized. However, utilization of rTMS in the context of ASD has received limited attention in the existing literature.

unedited

Actually, many studies have suggested that combination therapy is more effective in psychiatric disorders(O'neal and Baslet, 2018; Pan et al., 2019). Several recent studies have shown that rTMS is effective in the treatment of post-traumatic stress disorder after stroke and can be accelerated by adding a brief exposure program(Jiang et al., 2023). Repeated ultra-short exposure therapy combined with deep transcranial magnetic stimulation may be an effective treatment for post-traumatic stress disorder, and repeated stimulation of mPFC by magnetic coils may interfere with traumatic memory-mediated regression(Isserles et al., 2021). Thus, there is increasing evidence that magnetic stimulation combined with exposure therapy for PTSD fills the treatment gap while yielding favourable outcomes. On account of the severe consequences and specifics of adolescent ASD(March, 2003), various obstacles hinder treatment, such as parents' concerns about side effects, potential developmental impacts, and slow effect. Therefore, there is urgent demand for prompt, secure, and efficacious interventions.

Here, we present a preliminary experiment involving 5 days of twice-a-day low-frequency (1 Hz) rTMS performed in the DLPFC, in conjunction with imaginal exposure, for the treatment of ASD in adolescents. Based on the principle that rTMS stimulation of the DLPFC can reduce cortical excitability(Simmons, et al., 2004; Milad, et al., 2006; Kozel, 2018; White, et al., 2023)and thus improve PTSD anxiety behaviour, we hypothesize that anxiety behaviour in ASD can also be improved by the same stimulation pattern, so that the first low-frequency stimulation per day in dlPFC can improve and control existing symptoms. Based on the principle of gradually desensitizing patients to traumatic stimuli through imaginative exposure therapy, incorporation of a second low-frequency stimulation in daily treatment, along with imaginative exposure, has

the potential to elicit anxiety and fear associated with trauma. This induced anxiety can subsequently be addressed through daily application of a second low-frequency stimulation. After a 5-day treatment period, notable improvements in patient anxiety and fear levels were observed. This approach may also serve to mitigate the likelihood of Acute Stress Disorder (ASD) progressing into Post-Traumatic Stress Disorder (PTSD).

The patient 1, a 16-year-old female high-school student of Han ethnicity, received a diagnosis of acute stress disorder following a severe traumatic event. Specifically, she was subjected to sexual assault by her geography teacher during after-school lessons. Upon returning to school, the patient experienced distressing recollections of the incident while attending geography class, often resulting in emotional outbursts. Notably, the patient had no familial history of mental illness, prior occurrences of mental disorders, or any other medical conditions. There was also no evidence of alcohol or substance abuse or any significant medical comorbidities. As a result of the apprehension expressed by the parents regarding the potential adverse effects of the recommended medication, the patient was not administered medication prior to undergoing combination therapy. The initial assessment using the Children's Revised Impact of Event Scale version 8 (CRIES-8) yielded a cumulative score of 23, with intrusion and avoidance subscale scores of 3 and 20, respectively. The patient's baseline scores on the Hamilton Depression Rating Scale (HAMD), Hamilton Anxiety Rating Scale (HAMA), and Baker Scale for Suicidal Ideation- Chinese Version (BSI-CV) were 31, 13, and 10, respectively. We followed up at 7 days and 1 month. By the end of the treatment, her total scores on the HAMD, HAMA, and BSI-CV were 5 (83.87% improvement), 6 (53.85% improvement), and 6 (40% improvement), respectively (Figure 1, Table 1). Strikingly, the patient reported no subjective side effects after any rTMS session.

The patient 2, a 17-year-old male high-school student of Han ethnicity, unfortunately witnessed his father's death in a car accident. Subsequently, the patient consistently displayed resistance towards recollecting the incident or acknowledging the veracity of his father's passing.His aunt perceived him as excessively apathetic. The patient's family history did not indicate any instances of mental illness, prior episodes of mental disorders, or other medical conditions. There was also no evidence of alcohol or substance abuse, nor any significant medical ailments. Prior to the commencement of combination therapy, the patient exhibited reluctance to take medication. Low-frequency rTMS combined with imaginal exposure rapidly ameliorated mental symptoms and maintained the effect for at least one month post treatment (with no other treatment). The patient's baseline total scores on the HAMD, HAMA and BSI-CV were 12, 7, and 0, respectively. We followed up at 7 days and 1 month after treatment. By the end of the treatment, his total scores on the HAMD and HAMA were 2 (83.33% improvement) and 2 (71.43% improvement), respectively (Figure 1, Table 1).

unedited

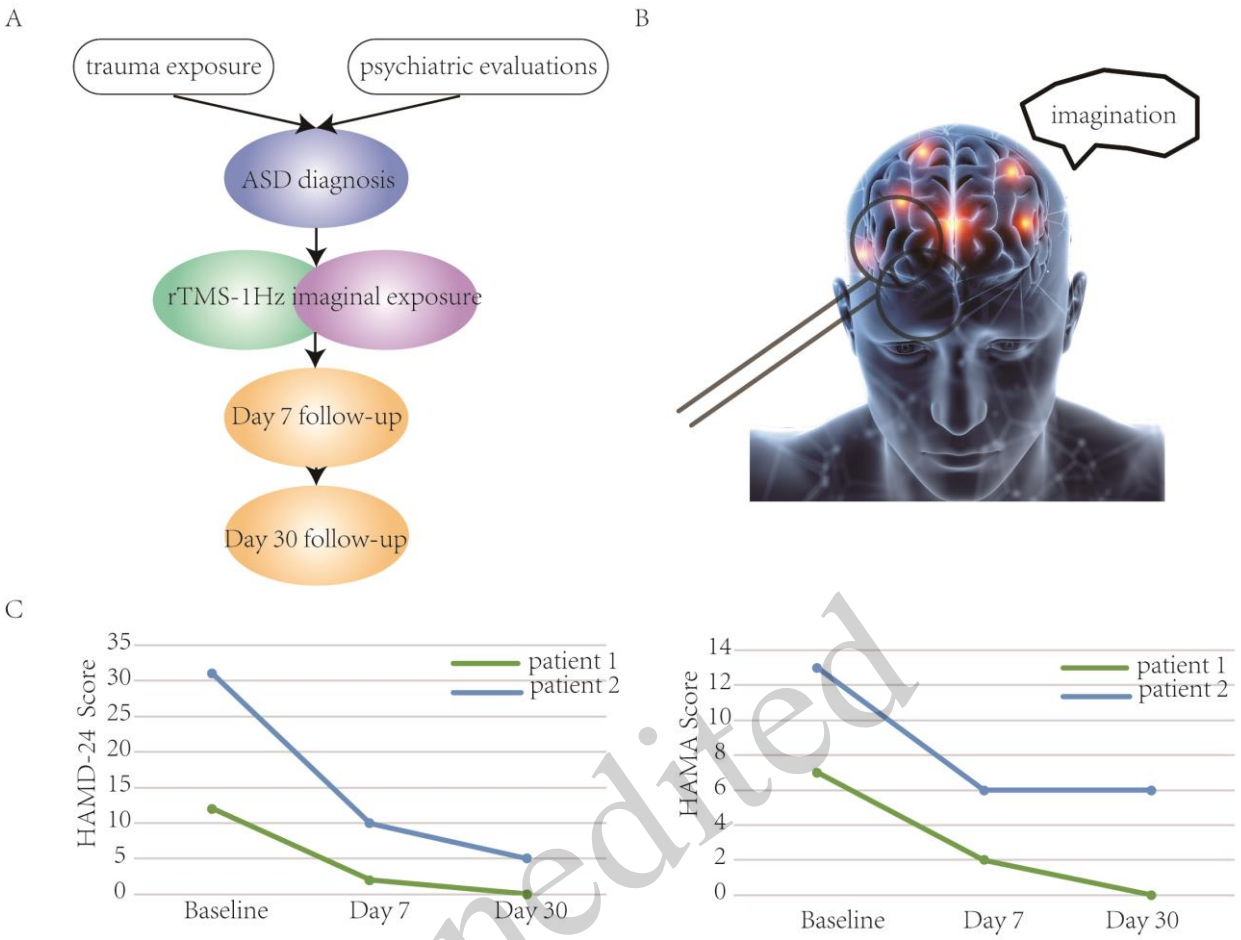

unedited

Fig.1 Results of depression assessment after 5 days of treatment.
(A) Program flowchart of ASD treatment. (B) Schematic diagram of rTMS combined with imaginal exposure for ASD. The picture of the 3D brain was taken from the freepik website. (C) Changes in depression assessments for ASD.

Table 1

	Baseline	DAY 7	DAY 30
Patient 1			
HAMD	31	10	5
HAMA	13	6	6
BSI-CV	10	7	6
Patient 2			
HAMD	12	2	
HAMA	7	2	
BSI-CV	0	0	0

Abbreviations: HAMD, Hamilton depression scale;HAMA, Hamilton Anxiety Scale;
BSI-CV, Beck Scale for Suicide Ideation-Chinese Version;

Assessments and rTMS procedure

Both subjects met the criteria for acute stress disorder in the Diagnostic and Statistical Manual of Mental Disorders, V Edition (DSM-V). This was assessed using structured clinical interviews based on the DSM-V (SCID), conducted by two professional psychiatrists. Both patients scored ≥ 30 on the trauma score at baseline and met the criteria for current major depression. Neither patient used drugs before or after receiving the

combination therapy because their parents showed concern about the occurrence and development of side effects. As mentioned, upon study entry, both subjects had had intermittent, disturbing flashbacks and trauma exposure history for less than 1 month. Primary outcomes at baseline were measured by means of the HAMD-24 and HAMA on Days 7 and 30.

The rTMS treatment was delivered by a Magstim® magnetic stimulator with an eight-figured coil (The Magstim Company Ltd, Whitland, UK). We defined the right dorsolateral prefrontal cortex target using the international electroencephalogram 10-20 standard positioning system. The rTMS protocol involved applying 1 Hz frequency for 5 consecutive days. Each daily rTMS session comprised two stimulations: 800 and 1600 pulses. The interval between the two stimuli was 30 minutes. Each day, the first treatment was 800 pulses, and the second (1600 pulses) was accompanied by imaginal exposure (recalling the traumatic event). The stimulus intensity was 100% of the resting motor threshold (MT) based on participant tolerance. The MT was defined as the lowest intensity of TMS required to induce a motor response in the contralateral resting abductor pollicis brevis muscle.

Imaginal exposure exposes patients to previous traumatic event(s) in a controlled setting. Our patients were asked to provide a list of 8 events or clues that would be used for systematic exposure during rTMS. These lists started with item 0, which was chosen by the subject as a calming or soothing experience. The next item (#1) was a neutral experience. Items 2 to 7 were various aspects of the event related to their traumatic experience that they believed would trigger increasing distress. These personalized lists were then used during exposure as a means of activating brain circuits associated with the patients' invasive flashback symptoms.

In our study, the combination of rTMS and imaginal exposure proved to be a safe and effective therapeutic approach for adolescents with ASD. Notably, the symptoms of both patients showed significant improvement following a total of five sessions of low-frequency rTMS, each session comprising one stimulation with and one without imaginal exposure, at different frequencies. These findings align with a previous study on rTMS treatment in adults, which demonstrated the efficacy of rTMS administered over a two-week period (3-5 sessions per week) for the treatment of refractory PTSD (Osuch, et al., 2009). Based on the difference in function of the main regulation of the left and right cerebral cortices, the right DLPFC is generally recognized as the main stimulus target for rTMS in the treatment of PTSD (Iglesias, 2020). Low-frequency stimulation can also reduce cortical excitability(Klomjai et al., 2015) and alter synaptic strength(Iglesias, 2020). It is not fully understood how low-frequency rTMS produces favourable changes to PTSD symptoms; however, one model explains that therapeutic effects are observed due to partial inhibition of lateralized right-sided hyperactivity of the DLPFC(Berlim and Van Den Eynde, 2014). Neurobiological evidence seems to show that low-frequency stimulation can induce long-term depression (LTD) (Klomjai, et al., 2015). A gradual, slight increase in calcium concentration after prolonged low-frequency stimulation promotes LTD and produces various changes to synapses(Klomjai, et al., 2015). These findings illustrate how the setting of rTMS can alter memory and plasticity; this has clinical applications in post-traumatic stress disorder, where individuals are severely impaired by miscoded invasive memories(Iglesias, 2020).

We hypothesized that the first treatment in a day with one rTMS session would stabilize acute symptoms, and the second one, which included imaginal exposure may activate the anxious and depressive symptoms then inhibited by the second rTMS. This study is the first to report adolescents with ASD who responded to rTMS combined with imaginal exposure. Both patients showed surprising results after treatment, at the 7-day follow-up and one-month follow-up; and the efficacy of the combined treatment continued for at least one month in both patients without medication before or after treatment. However, there are several limitations to the study. The sample size was very small, and we did not have a longer follow-up period to determine whether the treatment could prevent progression to PTSD or recrudescence of the original symptoms. However, our finding that the effect lasted at least one month without any other intervention is highly valuable for patients, especially adolescents. Importantly, rTMS combined with imaginative exposure appears to be a promising therapy to rapidly ameliorate ASD in adolescents . Overall, the clinically significant improvement in these cases supports

Unedited

the combination of physical and psychological therapy in adolescents with acute stress disorder.

In summary, rTMS combined with imaginal exposure could be used to rapidly and significantly ameliorate depressive and anxious symptoms of adolescents with ASD. The effect lasts for one month in the absence of other interventions. Further well-designed, sham-controlled studies and more participants are needed to test the efficacy and safety of this therapy in adolescents with ASD.

Data availability statement

All data generated and analysed during this study are available from the corresponding author upon reasonable request.

Acknowledgments

This work is supported by the grants from the National Natural Science Foundation of China (No.82271562) and Key Research and Development Program of Zhejiang Province of China (No. 2023C03077). The authors wish to thank the research assistants and staff of The First Affiliated Hospital, Zhejiang University School of Medicine.

Author contributions

Miaomiao ZHAO: Study design; acquisition, analysis and interpretation of data; drafting and revising the article. Ying LI: Analysis and interpretation of data; revising the article critically for important intellectual content. Haoyang ZHAO: Revising the article critically for important intellectual content. Chaonan JIANG: Revising the article critically for important intellectual content. Manli Huang: Study design; acquisition of data; critical revision of the article for important intellectual content. All authors approved the final version of the manuscript to be submitted.

Compliance with ethics guidelines

All the authors declare that they have no conflict of interest.

All procedures followed were in accordance with the ethical standards of the responsible committee on human experimentation (institutional and national) and with the Helsinki Declaration of 1975, as revised in 2008 (5). Informed consent was obtained from all patients for being included in the study. Additional informed consent was obtained from all patients for whom identifying information is included in this article.

unedited

References

Battle DE, 2013. Diagnostic and statistical manual of mental disorders (dsm). *Codas*, 25(2):191-192. https://doi.org/10.1590/s2317-17822013000200017

Berlim MT, Van Den Eynde F, 2014. Repetitive transcranial magnetic stimulation over the dorsolateral prefrontal cortex for treating posttraumatic stress disorder: An exploratory meta-analysis of randomized, double-blind and sham-controlled trials. *Can J Psychiatry*, 59(9):487-496. https://doi.org/10.1177/070674371405900905

Bielas H, Meister-Langraf RE, Schmid JP, et al., 2018. Acute stress disorder and c-reactive protein in patients with acute myocardial infarction. *Eur J Prev Cardiol*, 25(3):298-305. https://doi.org/10.1177/2047487317748506

Boaden K, Tomlinson A, Cortese S, et al., 2020. Antidepressants in children and adolescents: Meta-review of efficacy, tolerability and suicidality in acute treatment. *Front Psychiatry*, 11:717. https://doi.org/10.3389/fpsyt.2020.00717

Bryant RA, 2011. Acute stress disorder as a predictor of posttraumatic stress disorder: A systematic review. *J Clin Psychiatry*, 72(2):233-239. https://doi.org/10.4088/JCP.09r05072blu

Bryant RA, 2018. The current evidence for acute stress disorder. *Curr Psychiatry Rep*, 20(12):111. https://doi.org/10.1007/s11920-018-0976-x

Gaynes BN, Lloyd SW, Lux L, et al., 2014. Repetitive transcranial magnetic stimulation for treatment-resistant depression: A systematic review and meta-analysis. *J Clin Psychiatry*, 75(5):477-489; quiz 489. https://doi.org/10.4088/JCP.13r08815

George MS, Nahas Z, Molloy M, et al., 2000. A controlled trial of daily left prefrontal cortex tms for treating depression. *Biol Psychiatry*, 48(10):962-970. https://doi.org/10.1016/s0006-3223(00)01048-9

George MS, Lisanby SH, Avery D, et al., 2010. Daily left prefrontal transcranial magnetic stimulation therapy for major depressive disorder: A sham-controlled randomized trial. *Arch Gen Psychiatry*, 67(5):507-516. https://doi.org/10.1001/archgenpsychiatry.2010.46

Herringa RJ, 2017. Trauma, ptsd, and the developing brain. *Curr Psychiatry Rep*, 19(10):69. https://doi.org/10.1007/s11920-017-0825-3

Hoffman RE, Cavus I, 2002. Slow transcranial magnetic stimulation, long-term depotentiation, and brain hyperexcitability disorders. *Am J Psychiatry*, 159(7):1093-1102. https://doi.org/10.1176/appi.ajp.159.7.1093

Huang YZ, Edwards MJ, Bhatia KP, et al., 2004. One-hz repetitive transcranial magnetic stimulation of the premotor cortex alters reciprocal inhibition in dyt1 dystonia. *Mov Disord*, 19(1):54-59. https://doi.org/10.1002/mds.10627

Iglesias AH, 2020. Transcranial magnetic stimulation as treatment in multiple neurologic conditions. *Curr Neurol Neurosci Rep*, 20(1):1. https://doi.org/10.1007/s11910-020-1021-0

Isserles M, Tendler A, Roth Y, et al., 2021. Deep transcranial magnetic stimulation combined with brief exposure for posttraumatic stress disorder: A prospective multisite randomized trial. *Biol Psychiatry*, 90(10):721-728. https://doi.org/10.1016/j.biopsych.2021.04.019

Jiang C, Li Z, Wang J, et al., 2023. Effectiveness of repetitive transcranial magnetic stimulation combined with a brief exposure procedure for post-stroke posttraumatic stress disorder. *J Affect Disord*, 326:89-95. https://doi.org/10.1016/j.jad.2023.01.096

Kaczkurkin AN, Foa EB, 2015. Cognitive-behavioral therapy for anxiety disorders: An update on the empirical evidence. *Dialogues Clin Neurosci*, 17(3):337-346. https://doi.org/10.31887/DCNS.2015.17.3/akaczkurkin

Klomjai W, Katz R, Lackmy-Vallée A, 2015. Basic principles of transcranial magnetic stimulation (tms) and repetitive tms (rtms). *Ann Phys Rehabil Med*, 58(4):208-213. https://doi.org/10.1016/j.rehab.2015.05.005

Kozel FA, 2018. Clinical repetitive transcranial magnetic stimulation for posttraumatic stress disorder, generalized anxiety disorder, and bipolar disorder. *Psychiatr Clin North Am*, 41(3):433-446. https://doi.org/10.1016/j.psc.2018.04.007

Kozel FA, Van Trees K, Larson V, et al., 2019. One hertz versus ten hertz repetitive tms treatment of ptsd: A randomized clinical trial. *Psychiatry Res*, 273:153-162. https://doi.org/10.1016/j.psychres.2019.01.004

Locher C, Koechlin H, Zion SR, et al., 2017. Efficacy and safety of selective serotonin reuptake inhibitors, serotonin-norepinephrine reuptake inhibitors, and placebo for common psychiatric disorders among children and adolescents: A systematic review and meta-analysis. *JAMA Psychiatry*, 74(10):1011-1020. https://doi.org/10.1001/jamapsychiatry.2017.2432

March JS, 2003. Acute stress disorder in youth: A multivariate prediction model. *Biol Psychiatry*, 53(9):809-816. https://doi.org/10.1016/s0006-3223(02)01975-3

Mclean CP, Levy HC, Miller ML, et al., 2022a. Exposure therapy for ptsd: A meta-analysis. *Clinical Psychology Review*, 91 https://doi.org/10.1016/j.cpr.2021.102115

Mclean CP, Levy HC, Miller ML, et al., 2022b. Exposure therapy for ptsd: A meta-analysis. *Clin Psychol Rev*, 91:102115. https://doi.org/10.1016/j.cpr.2021.102115

Milad MR, Rauch SL, Pitman RK, et al., 2006. Fear extinction in rats: Implications for human brain imaging and anxiety disorders. *Biol Psychol*, 73(1):61-71. https://doi.org/10.1016/j.biopsycho.2006.01.008

O'neal MA, Baslet G, 2018. Treatment for patients with a functional neurological disorder (conversion disorder): An integrated approach. *Am J Psychiatry*, 175(4):307-314. https://doi.org/10.1176/appi.ajp.2017.17040450

Osuch EA, Benson BE, Luckenbaugh DA, et al., 2009. Repetitive tms combined with exposure therapy for ptsd: A preliminary study. *J Anxiety Disord*, 23(1):54-59. https://doi.org/10.1016/j.janxdis.2008.03.015

Pan MR, Huang F, Zhao MJ, et al., 2019. A comparison of efficacy between cognitive behavioral therapy (cbt) and cbt combined with medication in adults with attention-deficit/hyperactivity disorder (adhd). *Psychiatry Res*, 279:23-33. https://doi.org/10.1016/j.psychres.2019.06.040

Philip NS, Barredo J, Aiken E, et al., 2019. Theta-burst transcranial magnetic stimulation for posttraumatic stress disorder. *Am J Psychiatry*, 176(11):939-948. https://doi.org/10.1176/appi.ajp.2019.18101160

Robb AS, Cueva JE, Sporn J, et al., 2010. Sertraline treatment of children and adolescents with posttraumatic stress disorder: A double-blind, placebo-controlled trial. *J Child Adolesc Psychopharmacol*, 20(6):463-471. https://doi.org/10.1089/cap.2009.0115

Simmons A, Matthews SC, Stein MB, et al., 2004. Anticipation of emotionally aversive visual stimuli activates right insula. *Neuroreport*, 15(14):2261-2265. https://doi.org/10.1097/00001756-200410050-00024

Smith P, Perrin S, Dalgleish T, et al., 2013. Treatment of posttraumatic stress disorder in children and adolescents. *Curr Opin Psychiatry*, 26(1):66-72. https://doi.org/10.1097/YCO.0b013e32835b2c01

White LK, Makhoul W, Teferi M, et al., 2023. The role of dlpfc laterality in the expression and regulation of anxiety. *Neuropharmacology*, 224:109355. https://doi.org/10.1016/j.neuropharm.2022.109355

unedited