Journal of Zhejiang University-SCIENCE B (Biomedicine & Biotechnology) in press
www.jzus.zju.edu.cn; www.springer.com/journal/11585
E-mail: jzus_b@zju.edu.cn

Correspondence

https://doi.org/10.1631/jzus.B2400305

Residual hyperglycemia after successful treatment of a patient with severe copper sulfate poisoning

Ting LI[1,2], Yuanqiang LU[1,2]✉

[1]*Department of Emergency Medicine, The First Affiliated Hospital, School of Medicine, Zhejiang University, Hangzhou 310003, China*
[2]*Zhejiang Key Laboratory for Diagnosis and Treatment of Physic-chemical and Aging-related Injuries, Hangzhou 310003, China*

Copper sulfate is a frequently used copper compound in laboratory settings, with instances of poisoning being uncommon. A study conducted by the American Association of Poison Control Centers's National Poison Data System found that only 140 individuals were exposed to copper compounds over the course of a year, with 5 cases being intentional (Gummin et al., 2023). Severe poisoning from copper sulfate can result in isolated gastrointestinal injury (Galust et al., 2023), intravascular hemolysis (Adline et al., 2024), rhabdomyolysis (Richards et al., 2020), and other symptoms documented in the literature. However, there have been no reports of long-term uncontrolled hyperglycemia in patients with copper sulfate poisoning. This case study documents the treatment approach for a patient with unexplained, long-term, uncontrolled hyperglycemia, alongside multiple organ dysfunction resulting from intentional ingestion of a large dose of copper sulfate. This case report details the long-term complications in a patient's recovery from acute copper sulfate, highlighting the significance of ongoing monitoring and intervention.

A 17-year-old female drank 120 ml of a solution prepared with approximately 250g of copper sulfate at 9 p.m., resulting in abdominal pain, diarrhea, and vomiting of blue stomach contents. She was rushed to the hospital, where her creatinine level was 104 μmol/L before transfer to our health facility, and she received 2000 mL of 0.9% normal saline for gastric lavage. However, the gastric lavage was temporarily stopped because the patient began vomiting blood.

Upon arrival, the patient underwent blood tests to determine the metal levels in her system. There was a significantly elevated copper level of 294.3 μmol/L. Laboratory analysis further identified multiple abnormal indicators (Fig. 1). Concurrently, a CT scan identified edema and thickening of the antrum, pancreatic swelling, slight mesangial exudation, and minimal fluid accumulation in the pancreas and abdominal cavity (Fig. 2). Based on the clinical presentation and diagnostic findings, the patient received symptomatic supportive therapy, which included sodium thioglycolide detoxification, methylprednisolone for anti-inflammatory purposes, glutathione and glycyrrhizoate monoamine for hepatic protection, pantoprazole for gastric protection, and aggressive fluid resuscitation to maintain water and electrolyte balance.

unedited

✉ Yuanqiang LU, luyuanqiang@zju.edu.cn
Yuanqiang LU, https://orcid.org/0000-0002-9057-4344

Received June 11, 2024; Revision accepted Aug. 11, 2024;
Crosschecked xxx. xx, 20xx; Published online xxx. xx, 20xx

© Zhejiang University Press 2024

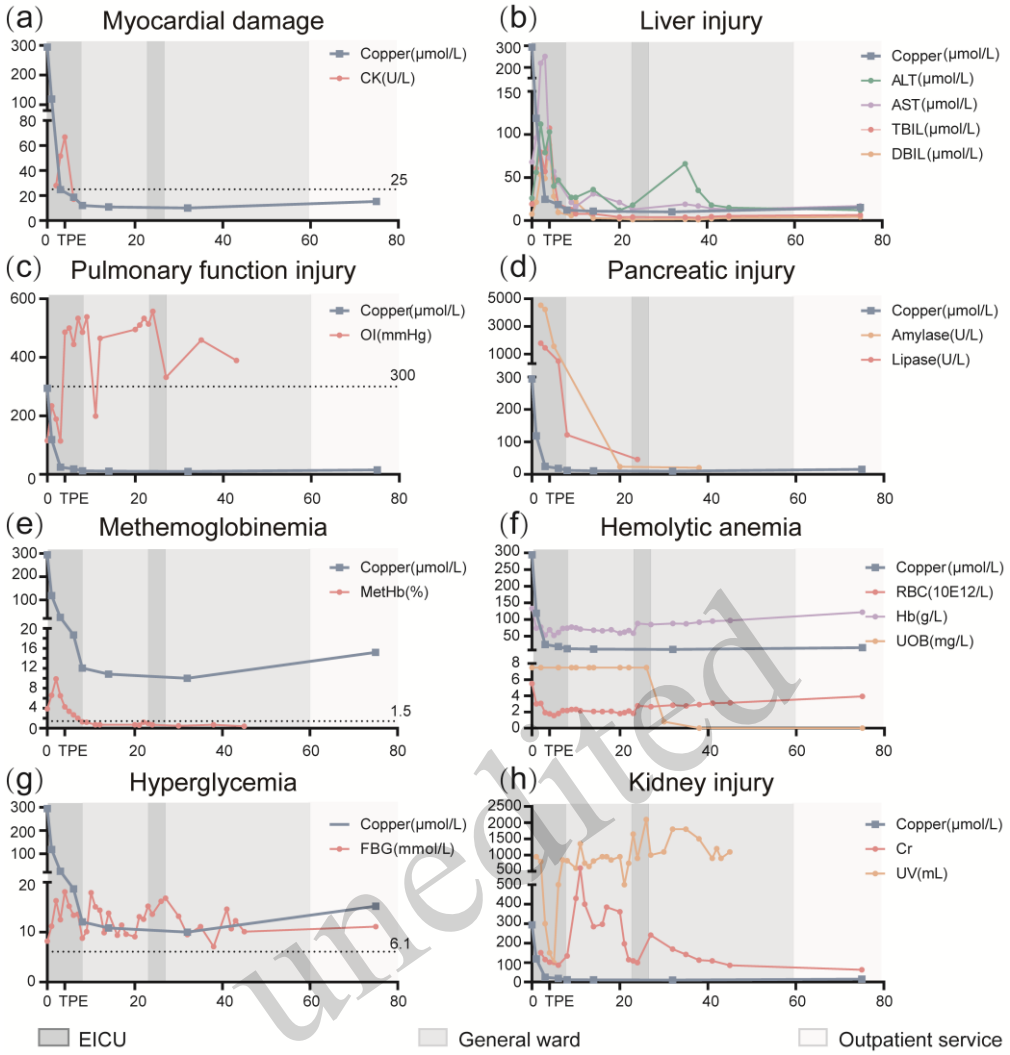

unedited

Fig. 1 Laboratory test results for the patient with acute copper sulfate poisoning. (a) Serum copper concentration. (b) Serum indicators related to liver injury: ALT concentration (green), TBIL concentration (red). (c) Oxygen index related to pulmonary function injury. (d) Serum indicators related to pancreatic injury: Amylase concentration (green), Lipase concentration (red). (e) Serum MetHb/Hb ratio. (f) Serum indicators related to hemolytic anemia: Retc/RBC ratio (green), RBC count (red), Hb concentration (yellow). (g) FBG concentration related to hyperglycemia. (h) Serum indicators related to kidney injury: GFR concentration (green), Cr (red). Ordinate is laboratory test results; abscissa is days. EICU, Emergency Intensive Care Unit; ALT, Alanine Aminotransferase; TBIL, Total Bilirubin; OI, Oxygen Index; MetHb, Methemoglobin; Hb, Hemoglobin; Ret, reticulocytes; FBG, FBG; Cr, Creatinine; GFR, glomerular filtration rate.

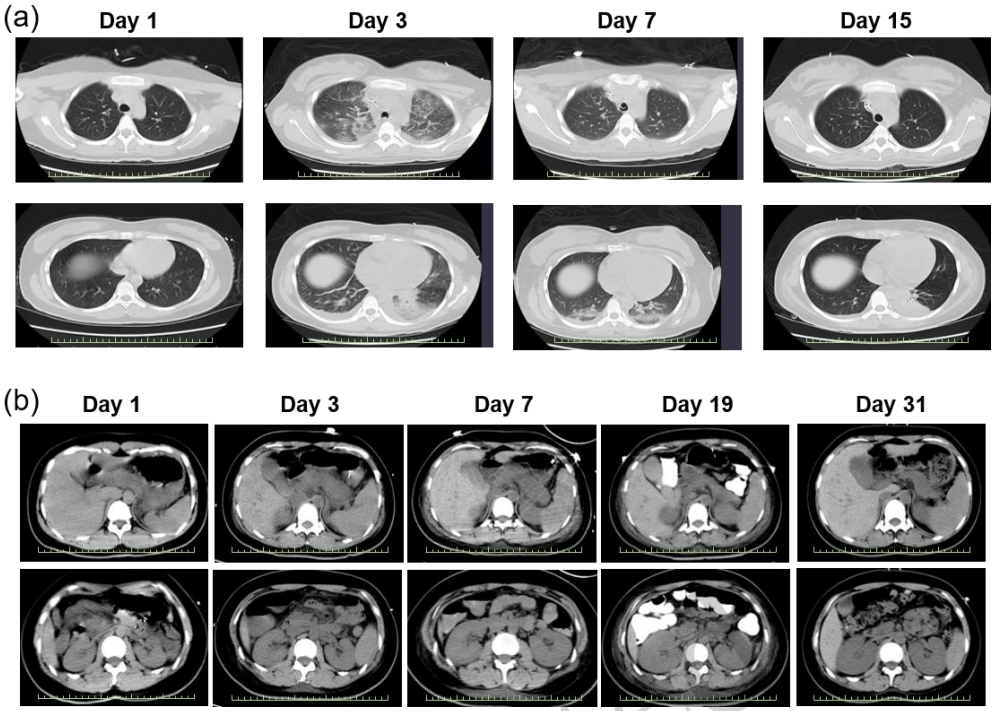

Fig. 2 Changes in the patient's brain and lung CT imaging. (a) CT lung scans on days 1, 3, 7, and 15. (b) Abdominal CT scans on days 1, 3, 7, 19, and 31.

Seven hours post admission, the patient was transferred to the emergency intensive care unit and plasmapheresis and continuous renal replacement therapy (CRRT) were initiated. The plasmapheresis was performed over 4 days with a total volume of 5,940 ml, while the CRRT treatment was conducted for 8 days (Fig. 3). On day 2, the patient developed cyanosis of the lips and cold extremities. Despite a high oxygen flow rate (37%/40L/min), there was no clinical improvement, with blood gas oxygen saturation at 99.5%, but percutaneous oxygen saturation was approximately 80%-85%. Consequently, the patient received leukocyte-depleted red cell suspension and methylene blue to address hypoxia, terlipressin to improve microcirculation, and prothrombin complex concentrate to promote coagulation. The patient was transferred to the toxicology observation unit on day 8 and underwent alternate-day hemodialysis to enhance renal function. By day 20, the patient exhibited severe non-pitting edema, mainly in the lower extremities, and renal function tests showed a progressive increase in serum creatinine levels, necessitating CRRT in the emergency care unit. Notably, she developed hyperglycemia post poisoning, as detailed in Figure 1. Initial treatment with conventional insulin was ineffective, prompting the addition of neutral protamine hagedorn insulin. On day 42, the patient’s poorly controlled hyperglycemia required an adjustment in the glycemic management strategy to short-acting insulin before meals and long-acting insulin before bedtime. She was discharged on day 45.

unedited

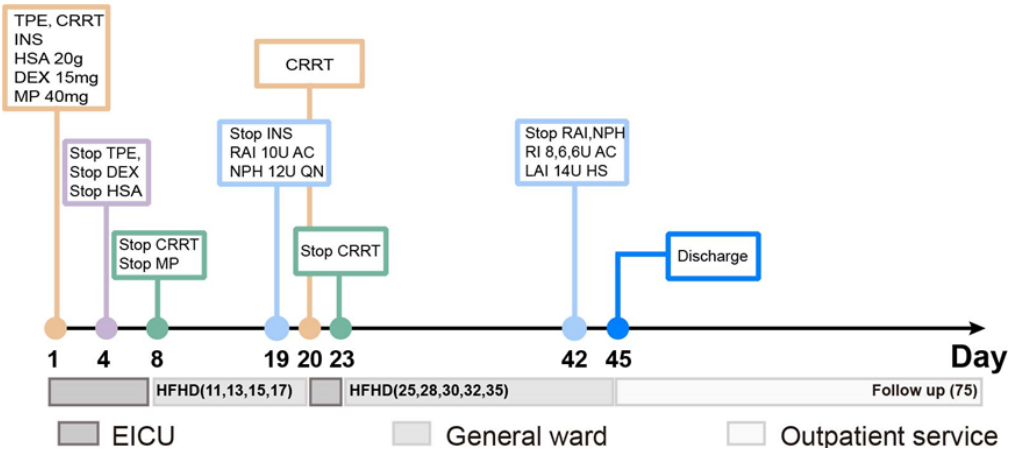

Fig. 3 Timeline of the main treatment regimens received by the patient with acute copper sulfate poisoning. TPE, Therapeutic Plasmapheresis; CRRT, Continuous Renal Replacement Therapy; HSA, Human Serum Albumin; INS, Insulin; DEX, Dexamethasone; MP, Methylprednisolone; RAI, Regular Insulin; AC, Before Meals; NPH, Neutral Protamine Hagedorn; QN, Every Night; LAI, Long-Acting Insulin; HS, At Bedtime.

A telephone follow-up one month post discharge revealed a fasting blood glucose level of 210.6 mg/dL while on insulin therapy. By the three-month post-discharge mark, the fasting blood glucose level decreased to 122.76 mg/dL with continued insulin therapy, providing valuable insights into the long-term implications of copper sulfate poisoning.

Copper sulfate is a potent oxidizing agent known to cause severe hemolysis, methemoglobinemia, liver and kidney damage, and significantly higher mortality rates than other poisonous heavy metals (Naha et al., 2012; Wang et al., 2016). The adverse effects of these heavy metals on tissues and organs are frequently associated with oxidative stress and mitochondrial dysfunction(Zhang et al., 2023a; Zhang et al., 2023b; Jiang et al., 2024). In erythrocytes, renal tubular epithelial cells and hepatocytes, copper sulfate also induces oxidative stress, mitochondrial autophagy, and endoplasmic reticulum stress(Wu et al., 2020; Tao et al., 2021; Bai et al., 2023), which may collectively contribute to kidney injury and intravascular hemolysis in patients.

Rapid removal of copper ions from circulating plasma by means of plasmapheresis can mitigate damage to the blood system and kidneys (Du and Mou, 2019; Banerjee et al., 2023; Shankar et al., 2023). The early detection, diagnosis, and intervention are of paramount importance, not only for immediate recovery but also to forestall long-term complications (Qin et al., 2023; Wang et al., 2023). In this case, the patient's condition improved following blood dialysis, suggesting that early and continuous blood-purification therapy may be beneficial for severely poisoned patients to optimize treatment outcomes. Timely blood dialysis is equally essential for mitigating long-term complications such as kidney damage. For ongoing management, ongoing monitoring and treatment of potential long-term complications are needed even after controlling the acute poisoning event.

The patient's elevated blood-glucose levels may have been influenced by the stress response induced by the poisoning(Daryagasht et al., 2023). The enlargement of the pancreas we observed in association with the copper sulfate exposure implies potential pancreatic damage and subsequent impairment of insulin secretion. Population-based observational studies have indicated a correlation between dietary copper exposure and the onset of type 2 diabetes(Zhao et al., 2023). Copper exposure disrupts metabolic pathways, impairs glucose metabolism, and induces autophagy through AMP-activated protein kinase and mammalian target of rapamycin axis, potentially leading to hyperglycemia(Chen et al.). In pancreatic beta cells, copper compounds produce high-molecular-weight covalently linked aggregates that contain the autoantigen glutamic acid decarboxylase, leading to cellular damage(Trigwell et al., 2001). The mechanism of uncontrolled hyperglycemia caused by

unedited

copper poisoning merits further investigation.

In summary, timely identification and treatment of acute copper sulfate poisoning are crucial for improving patient prognosis. Future research should focus on determining the optimal timing and methods for blood purification, as well as the early identification and management of post-poisoning complications. Additionally, effective strategies for managing long-term complications should be developed to further enhance patient prognosis.

Data availability statement

The data that support the findings of this study are not publicly available due to privacy concerns, but are available from the authors upon request and with the appropriate permissions.

Acknowledgments

This work was supported by the National Key Research and Development Program of China (2023YFC3603100 and 2023YFC3603105) and "Leading Goose" R&D Program of Zhejiang (2022C03076-4).

Author contributions

Ting LI performed the experimental research and data analysis, wrote and edited the manuscript. Yuan-Qiang LU contributed to the study design, supervision, and funding acquisition of the manuscript. All authors read and approved the final manuscript and, therefore, had full access to all the data in the study and take responsibility for the integrity and security of the data.

Compliance with ethics guidelines

Ting LI, and Yuan-Qiang LU declare that they have no conflict of interest.

Study has been granted an exemption by Clinical Research Ethics Committee of the First Affiliated Hospital, Zhejiang University School of Medicine (2023-1033). All procedures followed were in accordance with the ethical standards of the responsible committee on human experimentation (institutional and national) and with the Helsinki Declaration of 1975, as revised in 2008 (5). Informed consent was obtained from all patients for being included in the study. Additional informed consent was obtained from all patients for whom identifying information is included in this article.

unedited

References

Adline FA, Shanthi R, Sivakumar MR, et al., 2024. In vitro immune analysis of serum from the hemolymph of the anomuran crab albunea symmysta (linnaeus, 1758) displayed diversified reactions. *Journal of Invertebrate Pathology*, 204:108098. https://doi.org/10.1016/j.jip.2024.108098

Bai H, Fang Y, Cao H, et al., 2023. Inhibition of the bnip3/nix-dependent mitophagy aggravates copper-induced mitochondrial dysfunction in duck renal tubular epithelial cells. *Environmental Toxicology*, 38(3):579-590. https://doi.org/10.1002/tox.23704

Banerjee P, Mohan AK, Baid H, et al., 2023. Off with the blues: Therapeutic plasma exchange in a case of copper sulphate poisoning. *Transfusion and Apheresis Science : Official Journal of the World Apheresis Association : Official Journal of the European Society For Haemapheresis*, 62(6):103811. https://doi.org/10.1016/j.transci.2023.103811

Chen J, Liao J, Yu W, et al., Copper toxicity in the liver of broiler chicken: Insights from metabolomics and ampk-mtor mediated autophagy perspective. (1525-3171 (Electronic))

Daryagasht M, Moosavi M, Khorsandi L, et al., 2023. Hepatoprotective and anti-hyperglycemic effects of ferulic acid in arsenic-exposed mice. *Food and Chemical Toxicology : an International Journal Published For the British Industrial Biological Research Association*, 178:113924. https://doi.org/10.1016/j.fct.2023.113924

Du Y, Mou Y, 2019. The role of plasmapheresis in treating lethal cupric sulfate poisoning. *The American Journal of the Medical Sciences*, 357(4):338-342. https://doi.org/10.1016/j.amjms.2018.11.014

Galust H, Seltzer JA, Hardin JR, et al., 2023. "Campfire corrosive: Isolated gastrointestinal injury following ingestion of copper salts". *The American Journal of Emergency Medicine*, 70:210.e215-210.e218. https://doi.org/10.1016/j.ajem.2023.05.021

Gummin DD, Mowry JB, Beuhler MC, et al., 2023. 2022 annual report of the national poison data systemÂ® (npds) from america's poison centersÂ®: 40th annual report. *Clinical Toxicology (Philadelphia, Pa)*, 61(10):717-939. https://doi.org/10.1080/15563650.2023.2268981

Jiang L, Yang F, Liao H, et al., 2024. Molybdenum and cadmium cause blood-testis barrier dysfunction through ros-mediated nlrp3 inflammasome activation in sheep. *The Science of the Total Environment*, 906:167267. https://doi.org/10.1016/j.scitotenv.2023.167267

Naha K, Saravu K, Shastry BA, 2012. Blue vitriol poisoning: A 10-year experience in a tertiary care hospital. *Clinical Toxicology (Philadelphia, Pa)*, 50(3):197-201. https://doi.org/10.3109/15563650.2012.660572

Qin C, Yang Y, Lu Y, 2023. Perforation of the esophagus: An overlooked cause of chest pain as a complication of esophageal foreign bodies. *Journal of Zhejiang University Science B*, 24(5):455-457. https://doi.org/10.1631/jzus.B2300026

Richards JR, Scheerlinck PH, Owen KP, et al., 2020. Bodybuilding supplements leading to copper toxicity, encephalopathy, fulminant hepatic failure and rhabdomyolysis. *The American Journal of Emergency Medicine*, 38(11):2487.e2481-2487.e2485. https://doi.org/10.1016/j.ajem.2020.05.096

Shankar JA, Kaur A, Tyagi L, et al., 2023. Severe copper sulphate poisoning: A case rescued with plasmapheresis. *Tropical Doctor*, 53(2):327-328. https://doi.org/10.1177/00494755231151256

Tao D, Wang Y, Liu J, et al., 2021. Mechanism of cuso4 cytotoxicity in goat erythrocytes after high-level in vitro exposure to isotonic media. *Ecotoxicology and Environmental Safety*, 208:111730. https://doi.org/10.1016/j.ecoenv.2020.111730

Trigwell SM, Radford PM, Page SR, et al., 2001. Islet glutamic acid decarboxylase modified by reactive oxygen species is recognized by antibodies from patients with type 1 diabetes mellitus. *Clinical and Experimental Immunology*, 126(2):242-249.

Wang T, Chen X, Long X, et al., 2016. Copper nanoparticles and copper sulphate induced cytotoxicity in hepatocyte primary cultures of epinephelus coioides. *PloS One*, 11(2):e0149484. https://doi.org/10.1371/journal.pone.0149484

Wang Z, Lu X, Yang Y, et al., 2023. Inflammatory granuloma of the trachea: A rare case with epstin-barr virus infection. *Journal of Zhejiang University Science B*, 24(6):539-543. https://doi.org/10.1631/jzus.B2300024

Wu H, Guo H, Liu H, et al., 2020. Copper sulfate-induced endoplasmic reticulum stress promotes hepatic apoptosis by activating chop, jnk and caspase-12 signaling pathways. *Ecotoxicology and Environmental Safety*, 191:110236. https://doi.org/10.1016/j.ecoenv.2020.110236

Zhang T, Yang F, Dai X, et al., 2023a. Role of caveolin-1 on the molybdenum and cadmium exposure induces pulmonary ferroptosis and fibrosis in the sheep. *Environmental Pollution (Barking, Essex : 1987)*, 334:122207. https://doi.org/10.1016/j.envpol.2023.122207

Zhang Y, Li G, Zhao Y, et al., 2023b. Inhibition of calcium imbalance protects hepatocytes from vanadium exposure-induced inflammation by mediating mitochondrial-associated endoplasmic reticulum membranes in ducks. *Poultry Science*, 102(12):103013. https://doi.org/10.1016/j.psj.2023.103013

Zhao M, Wan J, Qin W, et al., 2023. A machine learning-based diagnosis modelling of type 2 diabetes mellitus with environmental metal exposure. *Computer Methods and Programs In Biomedicine*, 235:107537. https://doi.org/10.1016/j.cmpb.2023.107537

unedited