Journal of Zhejiang University-SCIENCE B (Biomedicine & Biotechnology) in press
www.jzus.zju.edu.cn; www.springer.com/journal/11585
E-mail: jzus_b@zju.edu.cn

Research Article

https://doi.org/10.1631/jzus.B2500270

Management of exogenous lipoid pneumonia after fuel aspiration: a single-center experience

Congying SONG[1,2], Ping WANG[1,2], Yuanqiang LU[1,2]✉

[1]*Department of Emergency Medicine, the First Affiliated Hospital of Zhejiang University School of Medicine, Hangzhou 310003, China*
[2]*Zhejiang Key Laboratory for Diagnosis and Treatment of Physic-chemical and Aging-related Injuries, Hangzhou 310003, China*

Abstract: Exogenous lipoid pneumonia following hydrocarbon aspiration is an unusual but severe condition. This study aimed to summarize the cases of pneumonitis following fuel aspiration from a single center to serve as a useful reference for clinicians in the future. The clinical courses and outcomes of 11 patients with pneumonitis following fuel aspiration were collected and presented. Among them, 4 representative cases were described in detail to summarize the management experience of this disease, and these cases were analyzed to better understand the clinical features and management strategies of hydrocarbon pneumonitis following fuel aspiration. Almost all patients were found to present with cough and dyspnea, and the most common symptoms were dyspnea and chest pain. A high proportion (90.9%) of patients presented with bilateral lower pulmonary field involvement, and half of the patients showed pneumonic consolidation. One patient with irreversible lung injury received extracorporeal membrane oxygenation (ECMO) and a lung transplant. The other patients received oxygen support, antibiotics, steroids, and other supportive care. Antibiotics and steroids were the most commonly used treatments. While bronchoalveolar lavage (BAL) was beneficial for removing irritants, its utility could also be reduced due to significant risks. Finally, all patients had favorable outcomes. In conclusion, ELP was definitely harmful to patients' health, and hypoxemia was common among these patients. Supportive care, including antibiotics, steroids and respiratory support, was the main treatment modality. It is recommended that the decision to employ BAL is made selectively. ECMO serves as a critical bridge to recovery or transplantation, and patients with timely and efficient treatment usually had a positive outcome.

Key words: Exogenous lipoid pneumonia; Hydrocarbon pneumonitis; Fuel; Bronchoalveolar lavage; Lung transplantation

Unedited

1 Introduction

Exogenous lipoid pneumonia (ELP), resulting from the aspiration of hydrocarbon-based compounds, represents a rare but potentially devastating form of chemical lung injury (Harris et al., 2011). Hydrocarbon pneumonitis following the aspiration of diesel fuel, engine oil, and similar petroleum-derived substances is one form of ELP, which occurs when people try siphoning fuel to fill their tanks (Shrivastava et al., 2011). These substances are a mixture of long-chain saturated hydrocarbons obtained from petroleum. After inhalation into the lungs, these chemicals directly damage the mucosa of the respiratory tract, causing congestion, edema, and inflammatory cell infiltration, eventually leading to pulmonary inflammation and fibrosis (Marangu et al., 2020; Abd-Elmawla et al., 2023). Fuel siphonage involves the forceful suction from a hose and a large amount of aspiration, which can commonly result in an accelerated clinical manifestation (Leong and Cheong, 2017; Xie et

✉ Yuanqiang LU, luyuanqiang@zju.edu.cn
Yuanqiang LU, https://orcid.org/0000-0002-9057-4344
Congying SONG, https://orcid.org/0000-0003-0822-0289
Ping WANG, https://orcid.org/0009-0008-5860-0072

Received June 5, 2025; Revision accepted Oct. 16, 2025;
Crosschecked xxx. xx, 20xx; Published online xxx. xx, 20xx

© Zhejiang University Press 2025

al., 2024). Despite its recognized severity, hydrocarbon pneumonitis remains largely characterized by sporadic case reports and small case series, creating significant gaps in our understanding of optimal disease management. A critical unknown factor is the formal risk-benefit profile of bronchoalveolar lavage (BAL). While BAL is theoretically beneficial for evacuating irritants, its utility is counterbalanced by procedural risks such as barotrauma and hypoxemia, with no consensus on the indications, timing or technical execution in this specific context (Venkatnarayan et al., 2014; Chen et al., 2019). Furthermore, while corticosteroids are commonly employed to mitigate inflammation, and antibiotics are administered to prevent secondary infection, the use of these drugs is based on limited evidence rather than robust guidelines.

For the most severe cases progressing to irreversible refractory respiratory failure, advanced life support strategies such as extracorporeal membrane oxygenation (ECMO) and lung transplantation emerge as last-resort options. ECMO can serve as a bridge to recovery or transplantation, while lung transplantation remains the definitive life-saving therapy for end-stage lung damage (Feng and Lu, 2021; Li et al., 2024; Gregorio et al., 2025; Kawashima et al., 2025). However, data on the application of these methods for treating hydrocarbon-induced lung injury is exceedingly scarce, limited to case reports with unclear patient selection criteria and intervention timing.

The awareness and understanding of lipoid pneumonia are essential in improving diagnostic interpretation and appropriate patient management. Therefore, this study aims to address this need by presenting a detailed case series of hydrocarbon pneumonitis and synthesizing our clinical experience. We focus particularly on the roles of BAL, corticosteroids, and the pathway to ECMO and transplantation, seeking to translate our findings into pragmatic clinical recommendations that can inform management until more definitive evidence becomes available.

Unedited

2 Materials and methods

In this retrospective cohort study, we initially screened all consecutive patients admitted to the Emergency Department of the First Affiliated Hospital of Zhejiang University, School of Medicine from January 1st, 2017 to January 1st, 2025, whose electronic medical records contained diagnostic codes related to pneumonia, aspiration or poisoning. The inclusion criterion was a definitive diagnosis of ELP secondary to hydrocarbon aspiration, as confirmed by a consistent history of hydrocarbon exposure (e.g., diesel, gasoline, or engine oil) coupled with compatible clinical symptoms and radiological findings on chest CT scans. The exclusion criteria were as follows: (1) patients aged ⩽ 18 years; (2) patients who had received mechanical ventilation, ECMO, lung transplant, or other advanced life support in other hospitals upon admission; (3) patients with coexisting other lung diseases, such as malignant tumors, chronic infections, interstitial lung diseases, and autoimmune diseases; (4) patients who were hospitalized for less than 24 hours; (5) patients characterized by missing important information. All data were collected from the electronic medical record system and included demographics data, therapeutic information, surgical details, radiological data, pathological data, and follow-up data.

To elucidate and compare disease-specific management strategies, we selected four illustrative cases spanning the severity spectrum: (1) critical respiratory failure requiring ECMO bridging to lung transplantation; (2) severe patients managed with BAL; (3) mild to moderate patients treated with BAL; (4) mild to moderate patients receiving conservative therapy without BAL. A comparative outcome analysis was performed across the four archetypal management strategies. This framework enables an evidence-based synthesis of risk-benefit profiles to develop optimal clinical pathways.

This study was performed in accordance with the principles of the Declaration of Helsinki, approval was granted by the Ethics Committee of the First Affiliated Hospital, School of Medicine, Zhejiang University (No.20240282), and written informed consent was obtained individually from all enrolled participants.

3 Results

3.1 Clinical characteristics of patients with ELP

We conducted a retrospective analysis of 11 cases of ELP resulting from hydrocarbon aspiration (Table 1, 2). The cohort predominantly consisted of male patients, with a median age of 47 years (interquartile range [IQR] 41-62). Clinically, respiratory symptoms were prevalent, with dyspnea observed in 90.9% of patients, cough in 72.7%, and expectoration in 54.5%. The less frequent symptoms included pharyngalgia, chest pain, and disturbances in consciousness, each occurring in 18.2% of cases. Laboratory investigations indicated systemic inflammation, as evidenced by elevated C-reactive protein (CRP) levels (median 87.3 mg/L [IQR 15.1-186.3]), leukocytosis (median white blood cell count 14.8×10^9/L [IQR 10.7-17.0]), and neutrophilia (median neutrophil count 13.9×10^9/L [IQR 8.8-15.5]). Chest computed tomography (CT) scans revealed bilateral lung involvement in 90.9% of patients, characterized primarily by patchy shadows (90.9%) and consolidative opacities (54.5%). Respiratory failure occurred in 63.6% of patients, necessitating advanced respiratory support, including mechanical ventilation in 36.4% of cases and high-flow oxygen therapy in 18.2% of cases. All patients received antibiotics and systemic corticosteroids on an empirical basis, and BAL was performed in 36.4% of cases. The median duration of hospitalization was 19 days (IQR 9-29), and all patients survived.

Table 1 Clinical characteristics of the patients with hydrocarbon pneumonitis

Clinical characteristics	Patients (n=11)
Age (years)	47.0 (41.0, 62.0)
Sex	
Male	10 (90.9%)
Female	1 (9.1%)
Symptoms	
Fever	6 (54.5%)
Cough	8 (72.7%)
Expectoration	6 (54.5%)
Pharyngalgia	2 (18.2%)
Dyspnea	10 (90.9%)
Chest pain	2 (18.2%)
Disturbance of consciousness	2 (18.2%)
Laboratory findings	
WBC (10^9/L)	14.8 (10.7, 17.0)
NEUT (10^9/L)	13.9 (8.8, 15.5)
LYMPH (10^9/L)	1.0 (0.8, 1.4)
CRP (mg/L)	87.3 (15.1, 186.3)
Chest CT scan findings	
Ground-glass opacities	1 (9.1%)
Patchy shadows	10 (90.9%)
Consolidative opacities	6 (54.5%)
Interstitial change	1 (9.1%)
Pleural effusion	3 (27.3%)
Distribution of CT scan findings	
Bilateral	10 (90.9%)
Single lobe	1 (9.1%)
Respiratory failure	7 (63.6%)
Oxygen therapy	
Oxygen by nasal cannula	4 (36.4%)
Oxygen by face mask	3 (27.3%)
Nasal high flow oxygen inhalation	2 (18.2%)
Tracheal intubation with mechanical ventilation	4 (36.4%)
BAL	4 (36.4%)
Antibiotics	11 (100%)
Steroids	11 (100%)
Length of hospital stay (days)	19.0 (9.0, 29.0)
Outcomes	
Survival	11 (100%)
Death	0 (0%)

WBC: white blood cell; NEUT: neutrophil; LYMPH: lymphocyte; CRP: C-reactive protein; BAL: bronchoalveolar lavage

Unedited

Table 2 The clinical characteristics, management, and outcomes and of patients with hydrocarbon pneumonitis

	Age/sex	Symptoms	Onset of symptoms	Involved lung lobes	SaO_2/PaO_2 at admission	Pulmonary failure	Respiratory support	BAL	Treatment	Length of hospital stay	Outcome
Case 1	71/male	Dyspnea, vomit	Within 24h	LUL, LLL, RUL, RML, RLL	53mmHg	Yes	ECMO, Intubation with mechanical ventilation	Yes	Antibiotics, steroids	44 days	survive
Case 2	44/male	Fever, cough, sputum, dyspnea, abdominal pain	Within 24h	LLL, RML, RLL	58mmHg	Yes	Tracheal intubation with mechanical ventilation, Venturi mask	Yes	Antibiotics, steroids	20 days	survive
Case 3	62/male	Cough, dyspnea	Within 24h	LLL, RLL	69.1mmHg	No	Nasal catheter oxygen inhalation	Yes	Antibiotics, steroids	19 days	survive
Case 4	57/male	Fever, chest pain	Within 24h	LLL, RML, RLL	57.7 mmHg	Yes	Oxygen therapy via Venturi mask	No	Antibiotics, steroids	29 days	survive
Case 5	21/female	Fever, pharyngalgia, dyspnea, chest pain	Within 24h	LML	96%	No	Nasal catheter oxygen inhalation	No	Antibiotics, steroids	14 days	survive
Case 6	35/male	Cough, dyspnea	Within 24h	LUL, LML, RUL, RML	98%	No	Nasal catheter oxygen inhalation	No	Antibiotics, steroids	6 days	survive
Case 7	60/male	Fever, cough, sputum, dyspnea	Within 24h	LML, LLL, RUL, RML, RLL	62mmHg	Yes	High-flow oxygen inhalation; tracheal intubation with mechanical ventilation	Yes	Antibiotics, steroids	34 days	survive
Case 8	47/male	Cough, sputum, dyspnea	Within 24h	LML, LLL, RML, RLL	71.5mmHg	Yes	High-flow oxygen inhalation	No	Antibiotics, steroids	7 days	survive
Case 9	42/male	Fever, cough, sputum, pharyngalgia, dyspnea	Within 24h	LML, LLL, RML, RLL	88.5mmHg	Yes	Tracheal intubation with mechanical ventilation	No	Antibiotics, steroids	29 days	survive
Case 10	41/male	Fever, cough, sputum, dyspnea	Within 24h	LML, LLL, RML, RLL	90.0mmHg	No	Nasal catheter oxygen inhalation	No	Antibiotics, steroids	9 days	survive
Case 11	69/male	Cough, sputum, dyspnea	Within 24h	LUL, LML, LLL, RUL, RML, RLL	63.2mmHg	Yes	Oxygen therapy via Venturi mask	No	Antibiotics, steroids	12 days	survive

LUL: Left upper lobe; LML: Left middle lobe; LLL: Left lower lobe; RUL: Right upper lobe; RML: Right middle lobe; RLL: Right lower lobe; SaO_2: oxygen saturation; PaO_2: arterial oxygen tension

Unedited

3.2 Case-based therapeutic profiling: management experience from four archetypal scenarios

3.2.1 Representative case 1: patient with critical respiratory failure requiring ECMO transitioning to lung transplantation

3.2.1.1 Case presentation and clinical course

A 71-year-old male was transferred to our emergency department due to progressive dyspnea and chest tightness that had worsened over four days after accidentally ingesting and aspirating diesel fuel. The incident was immediately followed by nausea and vomiting, prompting gastric lavage at a local hospital. Despite receiving initial supportive care, including high-flow oxygen therapy, the respiratory condition of the patient deteriorated rapidly, necessitating transfer to our tertiary care center for advanced management. A detailed timeline of his clinical course is provided in Fig. 1a.

3.2.1.2 Laboratory and radiological findings

Upon admission, arterial blood gas analysis revealed severe hypoxemia. Serial monitoring demonstrated a progressively declining PaO_2/FiO_2 ratio (Fig. 3a). Chest CT revealed extensive bilateral pulmonary involvement, featuring multiple large, patchy and cord-like high-density opacities with areas of consolidation, predominantly in the lower lobes (Fig. 1b, c). These findings were consistent with severe chemical pneumonitis and evolving lung injury.

3.2.1.3 Therapeutic interventions

The patient was placed on broad-spectrum antibiotics (piperacillin/tazobactam 4.5 g intravenously every 8 hours) and systemic corticosteroids (methylprednisolone 80 mg intravenously every 8 hours) to mitigate inflammation and prevent secondary infection. Due to refractory hypoxemia indicative of irreversible lung damage, the patient was evaluated and listed for lung transplantation. Veno-venous extracorporeal membrane oxygenation (VV-ECMO) was initiated on hospital day 4 as a bridge to transplant. A successful single-lung transplantation was performed on day 6. The explanted native lung exhibited extensive consolidation, atelectasis and suppurative necrosis on gross inspection. Histopathological examination confirmed massive neutrophil infiltration, alveolar epithelial damage, and early interstitial fibrosis (Fig. 1e). Postoperatively, immunosuppressive therapy (tacrolimus, mycophenolate mofetil, and prednisone) and antimicrobial prophylaxis were administered.

3.2.1.4 Outcome and follow-up

The patient's respiratory function improved markedly following the procedure. Post-operative CT scans showed significant resolution of the prior consolidative opacities (Figure 1d). Inflammatory markers such as CRP normalized, though leukocytosis persisted, potentially related to the post-transplant immunosuppressive state (Fig. 3b, c). After 36 days of hospitalization, the patient was discharged in a stable condition. He remained alive with a good functional status at the one-year follow-up assessment.

Unedited

3.2.2 Representative case 2: severe patient managed with BAL

3.2.2.1 Case presentation and clinical course

A 44-year-old male was transferred to our emergency department due to aggravated chest tightness and shortness of breath. Five days prior to admission, he had accidentally aspirated a mouthful of engine oil, which was immediately followed by vomiting and severe coughing. He initially received supportive care at a local hospital, but his respiratory symptoms worsened, necessitating referral to our facility for advanced management.

3.2.2.2 Laboratory and radiological findings

Upon admission, laboratory tests revealed significant leukocytosis and an elevated CRP level. Arterial blood gas analysis indicated hypoxemia. A chest CT scan demonstrated multiple bilateral lesions with the predominant involvement of the lower lungs (Fig. 2b). Following BAL, a CT scan revealed a new-onset right-sided pneumothorax (Fig. 2c). The PaO_2/FiO_2 ratio of the patient reached its nadir on day 2, coinciding with the BAL procedure, then subsequently improved (Fig. 3d). Similarly, the CRP level peaked on day 2 and then gradually declined (Fig. 3f).

3.2.2.3 Therapeutic interventions

Initial supportive management included antibiotic therapy (cefoperazone/sulbactam 2 g intravenously every 6 hours), systemic corticosteroids (methylprednisolone 40 mg intravenously every 8 hours), and oxygen supplementation via a Venturi mask. Given the concern for ongoing pulmonary damage from the non-metabolized oil, therapeutic fiberoptic bronchoscopy with BAL was performed on hospital day 2 under mechanical ventilatory support. The procedure revealed copious purulent secretions. Immediately post-lavage, the patient developed acute hypoxemia (SpO2 dropped to 80%) and hypertension. Emergency management included intravenous furosemide (20 mg) and methylprednisolone (80 mg) bolus administration, alongside ventilation with a high-frequency oscillatory ventilator. The subsequent diagnosis of pneumothorax required immediate closed thoracic drainage. The patient was maintained on mechanical ventilation and continued to receive antibiotics and corticosteroids.

3.2.2.4 Outcome and follow-up

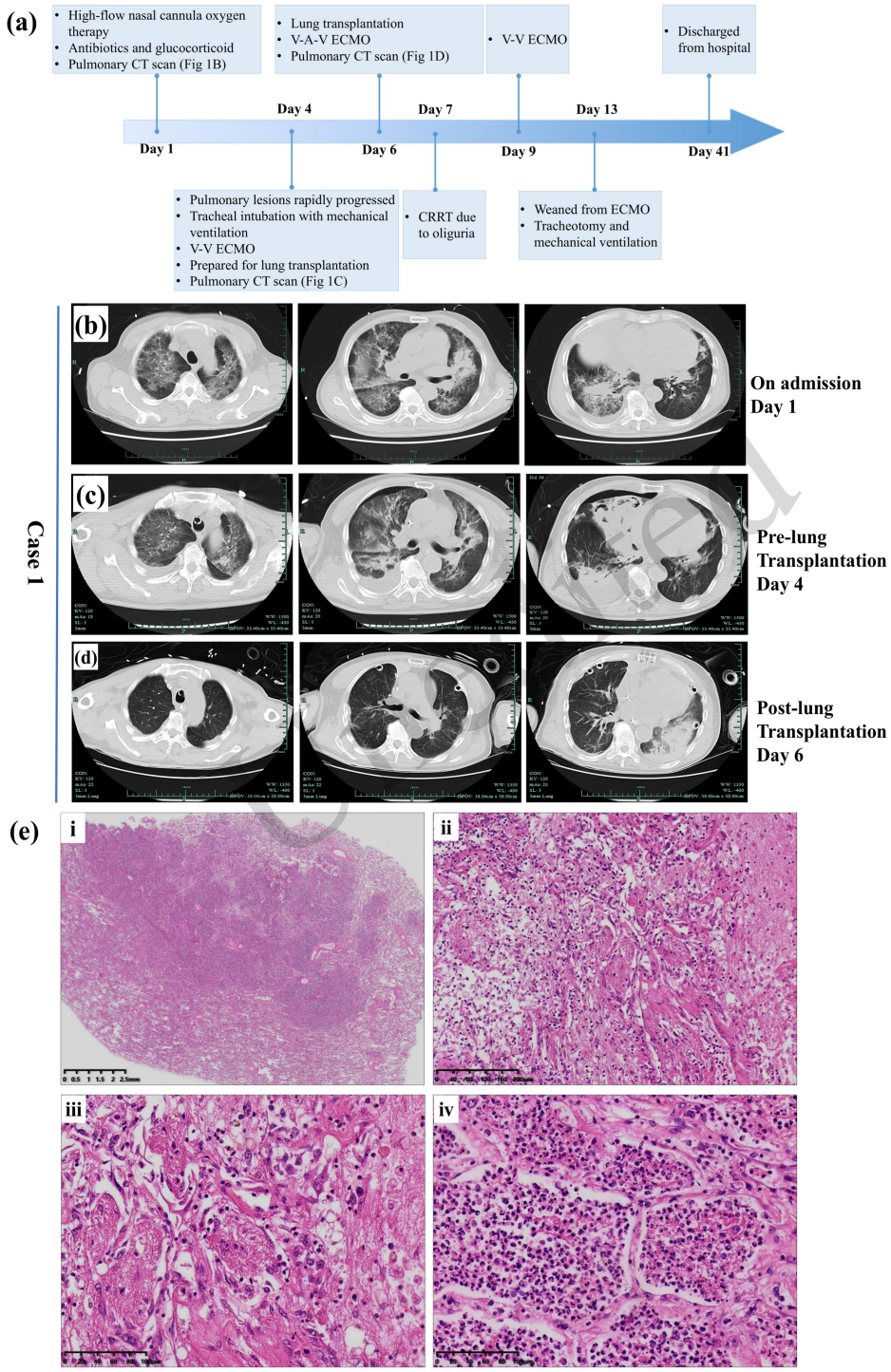

Fig. 1 Illustration of the clinical course and features of case 1

(a) Clinical course of Case 1; (b) Lung CT images of Case 1 on admission; (c) Lung CT images of Case 1 before lung transplantation; (d) Lung CT images of Case 1 after lung transplantation; (e) Surgical resection of pathological specimens. i: 10X, ii: 50X, iii: 100X, iv: 100X. ECMO: extracorporeal membrane oxygenation; CRRT: continuous renal replacement therapy.

The patient's hypoxemia gradually improved with comprehensive supportive care and he was discharged after 20 days of hospitalization. A follow-up CT scan prior to discharge showed residual pulmonary lesions and enlarged cavities in the right lung (Fig. 2d), but the patient was clinically stable. The disease timeline is summarized in Fig. 2a.

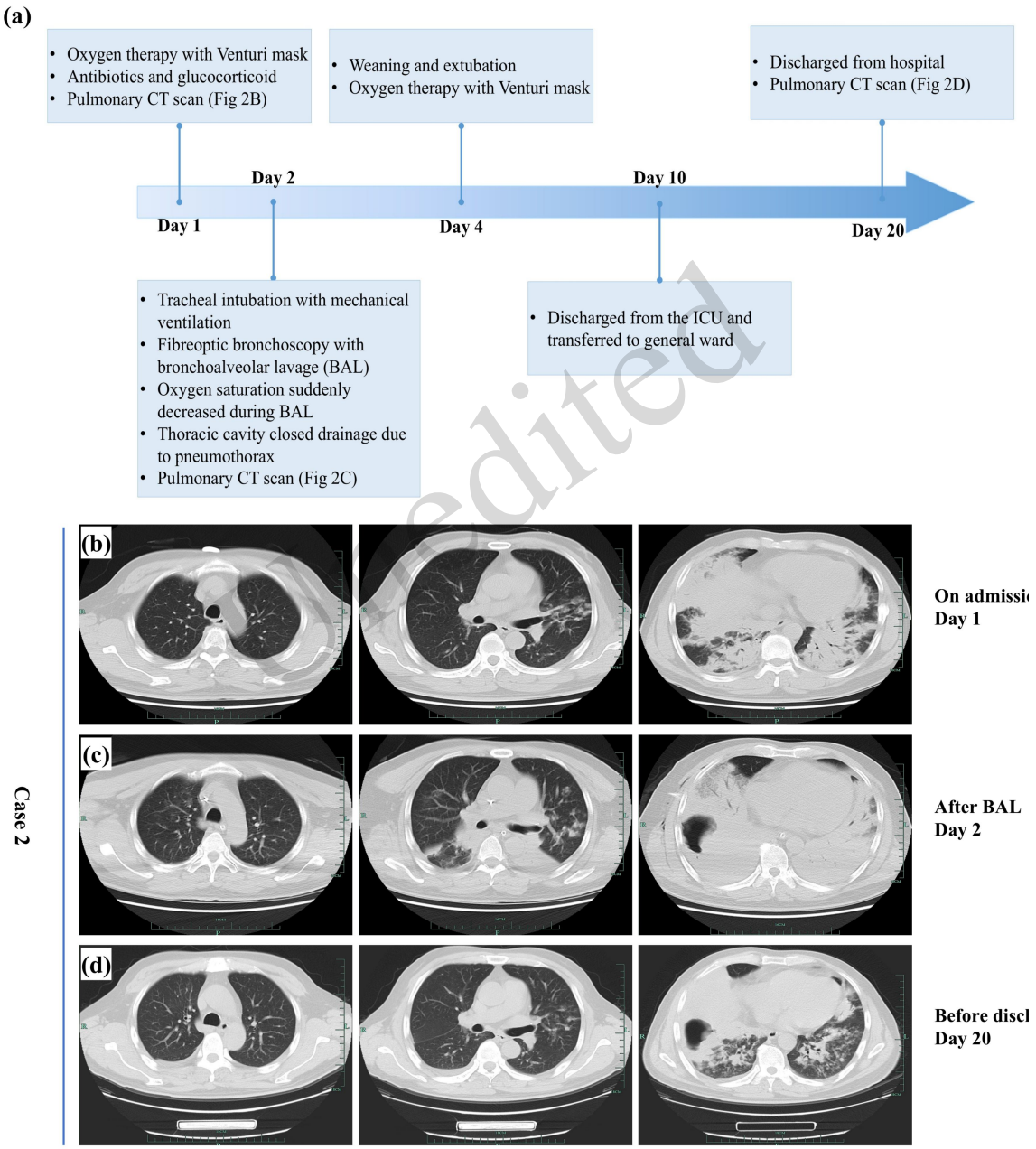

Fig. 2 Illustration of the clinical course and features of case 2

(a) Clinical course of Case 2; (b) Lung CT images of Case 2 on admission; (c) Lung CT images of Case 2 after BAL; (d) Lung CT images of Case 2 before discharge. ECMO: extracorporeal membrane oxygenation; BAL: bronchoalveolar lavage.

Unedited

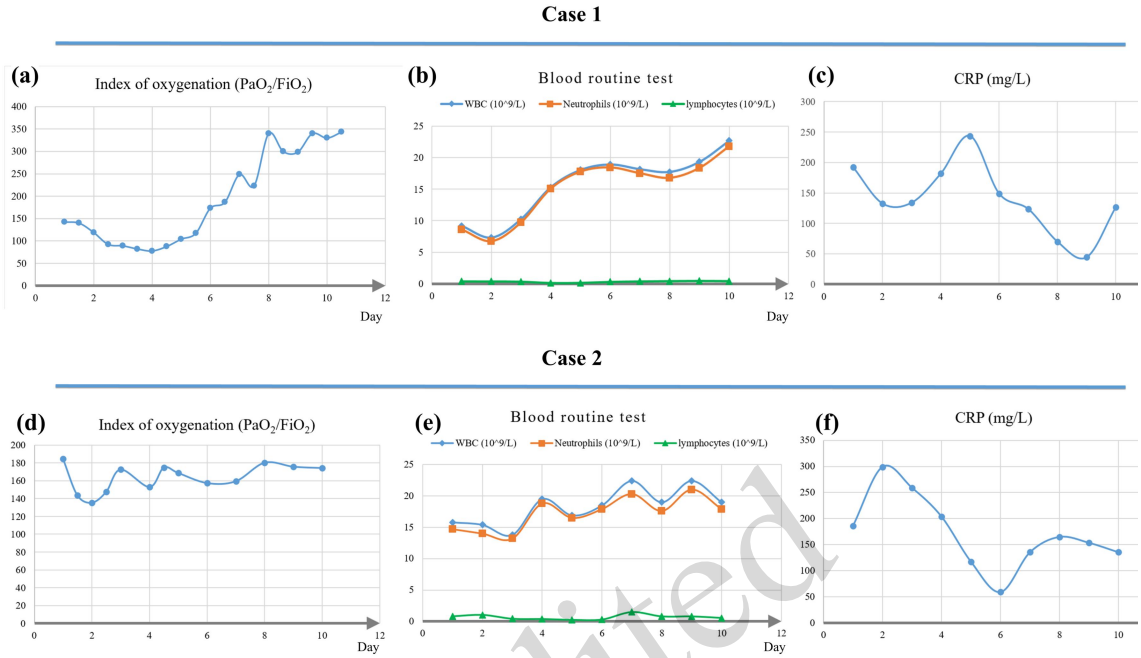

Fig. 3 Laboratory findings of Case 1 and Case 2

(a) Index of oxygenation in Case 1; (b) Results of blood routine test in Case 1; (c) Results of CRP in Case 1; (d) Index of oxygenation in Case 2; (e) Results of blood routine test in Case 2; (f) Results of CRP in Case 2. PaO_2: arterial oxygen tension; FiO_2: inspired oxygen fraction; CRP: C-reactive protein.

Unedited

3.2.3 Representative case 3: patient in mild to moderate condition treated with BAL

3.2.3.1 Case presentation and clinical course

A 62-year-old male was referred to our emergency department from a local hospital with a diagnosis of aspiration pneumonia and persistent hypoxemia. The patient had aspirated diesel fuel while attempting to siphon it from a tank, which immediately provoked intense coughing and chest tightness. He was admitted to the local hospital one day post-aspiration due to increasing weakness.

3.2.3.2 Laboratory and radiological findings

Chest CT imaging upon transfer to our institution revealed patchy hyperdense opacities scattered throughout both lungs and multiple clumpy hyperdense opacities in the right lung (Fig. 4a). The admission laboratory results showed leukocytosis (WBC count 12×10^9/L with 80% neutrophils) and a markedly elevated CRP level of 93.5 mg/L. Arterial blood gas analysis on supplemental oxygen showed a pH of 7.51, a PaCO2 of 33.3 mmHg, and a PaO_2 of 69.1 mmHg (PaO_2/FiO_2 ratio=238.3).

3.2.3.3 Therapeutic interventions

The patient underwent fiberoptic bronchoscopy with BAL on the 4th day after the aspiration event at the local hospital. Upon transfer of the patient to our care, our management strategy focused on comprehensive medical therapy and close monitoring. We initiated broad-spectrum intravenous antibiotic coverage with meropenem for potential Gram-negative and anaerobic pathogens and supplemented it with cefoperazone-sulbactam for broader coverage. Intravenous corticosteroid therapy was administered (methylprednisolone 40 mg twice daily) to mitigate the intense chemical pneumonitis and inflammatory response. The patient was maintained on supplemental oxygen via nasal cannula to a target SpO2 > 95%.

3.2.3.4 Outcome and follow-up

The patient's clinical course demonstrated gradual but consistent improvement: serial laboratory monitoring showed a resolving inflammatory response. With the instituted regimen, the patient's hypoxemia resolved. A follow-up CT scan showed progression to enlarged cavities in the right lung (Fig. 4b). After a total hospital stay of 19 days, he was discharged in a stable condition.

3.2.4 Representative case 4: patient in mild to moderate condition receiving conservative therapy without BAL

3.2.4.1 Case presentation and clinical course

A 51-year-old male presented to the local hospital with chest tightness, which developed shortly after aspirating diesel fuel and was followed by chest pain and a high-grade fever (up to 39.1℃). After one week of supportive treatment at the local hospital and showing no significant clinical improvement, he was transferred to our emergency department for further management.

3.2.4.2 Laboratory and radiological findings

On admission to our unit, the patient was tachycardic (heat rate 110 beats/min) and tachypneic (22 breaths/min), with an oxygen saturation of 89% on room air, which improved to 96% on a 40% Venturi mask. An arterial blood gas analysis performed on room air revealed significant hypoxemia (PaO_2 57.7 mmHg) and alkalosis (pH 7.51). Laboratory investigations revealed a pronounced acute inflammatory response with a WBC count of 18.1×10^9/L, 92.8% of neutrophils, and an elevated CRP level of 77.8 mg/L. Initial CT imaging at the local hospital demonstrated bilateral lower zone pneumonitis (Fig. 4c). A subsequent CT scan showed enlarged cavities in the right lung (Fig. 4d).

3.2.4.3 Therapeutic interventions

Given the clinical and radiographic progression despite the prior administration of antibiotics, we broadened our antimicrobial coverage significantly, initiating with intravenous piperacillin-tazobactam (4.5 g every 8 hours) for broad-spectrum bacterial coverage. Due to the cavitary lesions and prolonged course, we empirically added voriconazole intravenously (6 mg/kg every 12 hours for two loading doses, then 4 mg/kg every 12 hours) for the coverage of angioinvasive fungi. To address the severe inflammatory component of hydrocarbon pneumonitis, we administered high-dose intravenous corticosteroids (methylprednisolone 80 mg every 12 hours). Respiratory support was provided via a 40% Venturi mask to maintain adequate oxygenation.

3.2.4.4 Outcome and follow-up

The patient's response to the intensified regimen was favorable. His oxygen requirements decreased steadily, and he was weaned to a nasal cannula by day 7 of hospital stay at our facility and maintained an SpO2 > 95%. He was discharged after 29 days of hospitalization with a favorable outcome.

4 Discussion

Fuel is a mixed hydrocarbon that, after being inhaled into the lungs, directly damages the mucosa of the respiratory tract, causing congestion, edema, and inflammatory cell infiltration. Due to the low surface tension of diesel, it easily spreads to the entire lobes of the lungs, destroying the surfactant of the lungs, causing increased alveolar capillary permeability and respiratory failure. Meanwhile, the accumulation of oily substances in the alveoli can lead to pulmonary interstitial involvement and later can destroy lung tissue structure, resulting in pulmonary fibrosis (Leong and Cheong, 2017; Abd-Elmawla, et al., 2023). Animal models of hydrocarbon pneumonitis have suggested that the lung interstitium is the predominant site of damage, and the triggering of the inflammatory response is more significant than the direct damage of the aspirated hydrocarbon compounds (Grossi et al., 2006).

Unedited

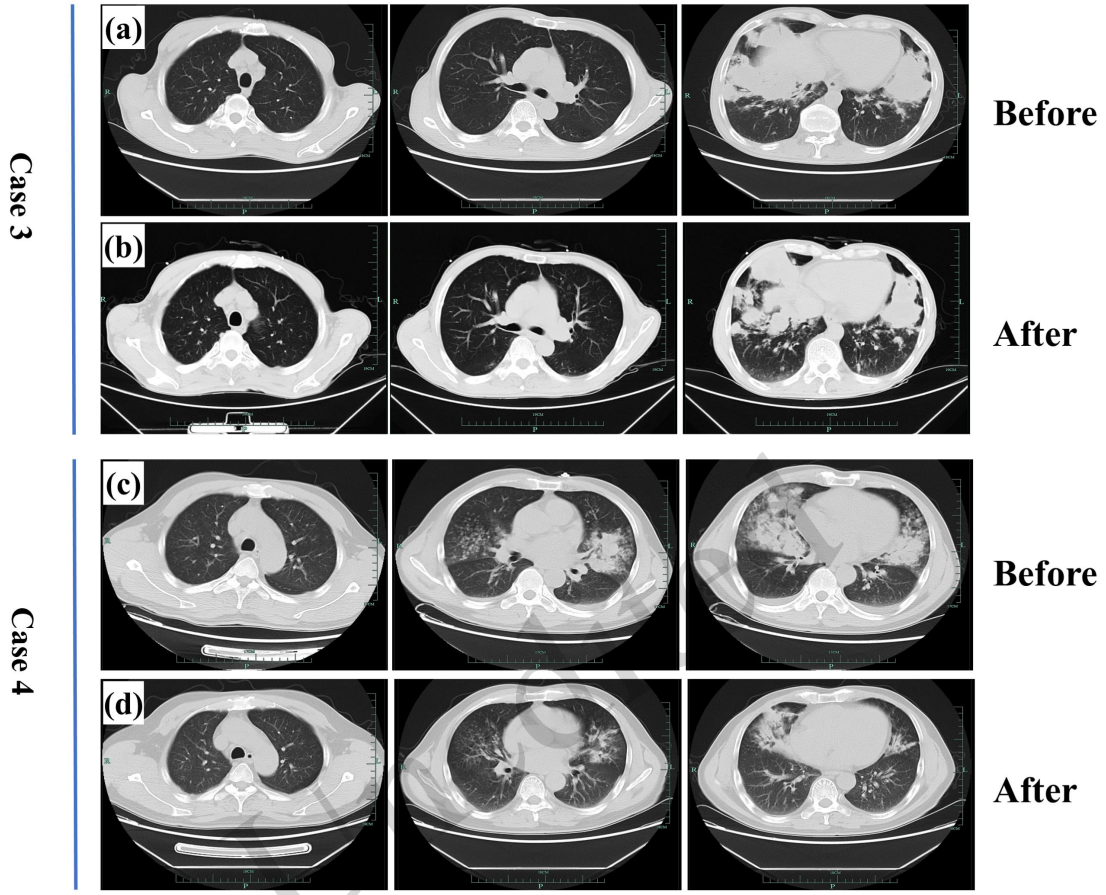

Fig. 4 CT images of Case 3 and Case 4

(a) Lung CT images of Case 3 before treatment; (b) Lung CT images of Case 3 after treatment; (c) Lung CT images of Case 4 before treatment; (d) Lung CT images of Case 4 after treatment.

The right middle lobe was reported to be the most commonly involved lung zone, since accidents usually occurred when the patient was bending forward to siphon the fuel (Yi et al., 2009). Meanwhile, according to the analysis of reported cases, the bilateral lower lobes were involved to a greater extent (Khanna et al., 2004; Hadda et al., 2009; Shrivastava, et al., 2011; Haciomeroglu et al., 2014; Jaybhaye and Shilawant, 2014; Venkatnarayan, et al., 2014; Chen, et al., 2019; Shrestha et al., 2021). We thought that this might be related to the amount and speed of inhalation, as well as the posture of the patient during siphoning. Some investigators reported that most patients with hydrocarbon pneumonitis present with multiple pneumatoceles or cavitary nodules on CT scans (Franquet et al., 2000), consistent with our findings in the reported cases. Since the lower lobes of the lungs were most commonly involved, postural drainage and the utilization of gravity to drain secretions from the lungs might be useful. While this strategy has not yet been proven to be effective, we need further investigations on this matter through future clinical research.

Recently, no detailed uniform criteria have been derived for treating hydrocarbon pneumonia, with existing experience limited to case reports. Based on our clinical experience and other studies, the management of severe hydrocarbon pneumonitis hinges on rapid supportive care and timely escalation based on the trajectory of respiratory failure. The primary therapeutic challenges lie in the controversial role of BAL and the identification of patients who might require advanced life support, such as ECMO and lung transplantation.

Due to the lack of evidence on risk-benefit balance, the role of BAL remains controversial. Some case reports have shown that BAL could bring dramatic improvements in patients with hydrocarbon pneumonitis

(Chang et al., 1993; Chen, et al., 2019). However, the specialists in our hospital believed that as the fuel is not water-soluble, it would be difficult to remove by BAL, which would also increase the risk of alveolar damage, leading to respiratory failure. Our experience underscores that BAL is a double-edged sword: while it is theoretically beneficial for removing irritants (Khanna, et al., 2004; Hadda, et al., 2009; Venkatnarayan, et al., 2014; Chen, et al., 2019), its utility is counterbalanced by significant risks, as evidenced by the pneumothorax in our Case 2. Therefore, we posit that BAL may be considered for mild to moderate cases with a limited volume of aspiration, where the intent is to prevent the spread of hydrocarbons and mitigate ongoing inflammation. If performed in these selected cases, it should be done early (within 24-48 hours) by an experienced bronchoscopist under controlled settings with lung-protective ventilation strategies. Conversely, our data suggest that BAL is contraindicated or is of limited value in severe cases with extensive bilateral consolidation and acute respiratory distress syndrome (ARDS), as seen in Case 1 prior to transfer. Here, the parenchyma was extensively damaged and fragile, making it highly susceptible to barotrauma and volutrauma during the procedure; aggravating ARDS with BAL in such a scenario can precipitate a catastrophic decline. Instead, management should focus on advanced lung-protective mechanical ventilation and other supportive measures. In our study, most patients with hydrocarbon pneumonitis received antibiotics treatment to reduce secondary infection. It was impossible to distinguish between hydrocarbon pneumonitis and a secondary pulmonary infection using radiology. Elevated white blood cell counts were typically observed in individuals with hydrocarbon pneumonitis, similar to what is seen in pneumonia. The decision to administer corticosteroids should be individualized but prompt. Given that the primary injury is an intense chemical pneumonitis followed by a potentially destructive inflammatory response, we support the early initiation of systemic corticosteroids (e.g., methylprednisolone 1-2 mg/kg/day or equivalent) in patients with significant hypoxemia or radiographic progression, as this was done in all our cases. This strategy aims to dampen the inflammatory cascade and potentially limit progression to fibrosis (Chang, et al., 1993; Sen et al., 2013). Therapy can typically be tapered over 1-2 weeks based on clinical and radiographic improvement.

For the minority of patients who develop refractory hypoxemia despite maximal medical management, ECMO serves as a vital bridge. As demonstrated in Case 1, ECMO could stabilize gas exchange, allowing time for lung recovery. However, when lung injury is irreversible, characterized by progressive fibrosis and profoundly requires a sustained ventilatory support without signs of improvement, an urgent assessment for lung transplantation must be initiated. Our case exemplifies how transplantation could be a life-saving intervention for end-stage lung damage from hydrocarbon aspiration, though this is fraught with challenges of donor availability and lifelong immunosuppression. With the improvement of relevant regulations and clinical technology, more patients are expected to benefit from this approach. To translate these insights into practice, we propose a structured management algorithm based on disease severity (Fig. 5). This framework was designed to guide clinical decision-making at critical junctures. For mild disease ($PaO_2/FiO_2 > 300$), supportive care (oxygen), antibiotics for suspected secondary infection and the consideration of early BAL are recommended. Moderate disease (PaO_2/FiO_2 200-300) needs aggressive supportive care, intravenous corticosteroids and antibiotics, and BAL should be undertaken with extreme caution and only if deemed necessary by an experienced team. Severe disease ($PaO_2/FiO_2 < 200$) should be supported by lung-protective mechanical ventilation, corticosteroids and antibiotics, with BAL being an unfavored option. As for refractory severe disease, the immediate evaluation for VV-ECMO as a bridge to recovery or, in cases of unequivocal irreversible lung injury, as a bridge to lung transplantation is recommended.

Certainly, the most important prevention method for hydrocarbon pneumonia is to avoid exposure to the offending agent. Changing unhealthy work and lifestyle, as well as strengthening health education, are crucial to preventing hydrocarbon pneumonia caused by accidents.

Our study has some inherent limitations. First, this was a single-center study with a small sample size, and the clinical characteristics of hydrocarbon pneumonitis following fuel aspiration might not be able to present the all aspects of the disease. Furthermore, while our analysis focused on acute hospital survival and short-term radiological resolution, we lack long-term functional outcome data, such as those on pulmonary function testing

Unedited

and quality of life. Thus, long-term follow-up data should be collected at regular intervals using a standardized protocol. Finally, due to the retrospective, observational nature of this study, a causal relationship between the intervention and outcomes could not be established. In the future, more extensive prospective data collection and a study with a prospective design will allow for a better investigation of the topic. Despite its limitations, our research is a novel systematic analysis that summarizes the characteristics of the disease and shares

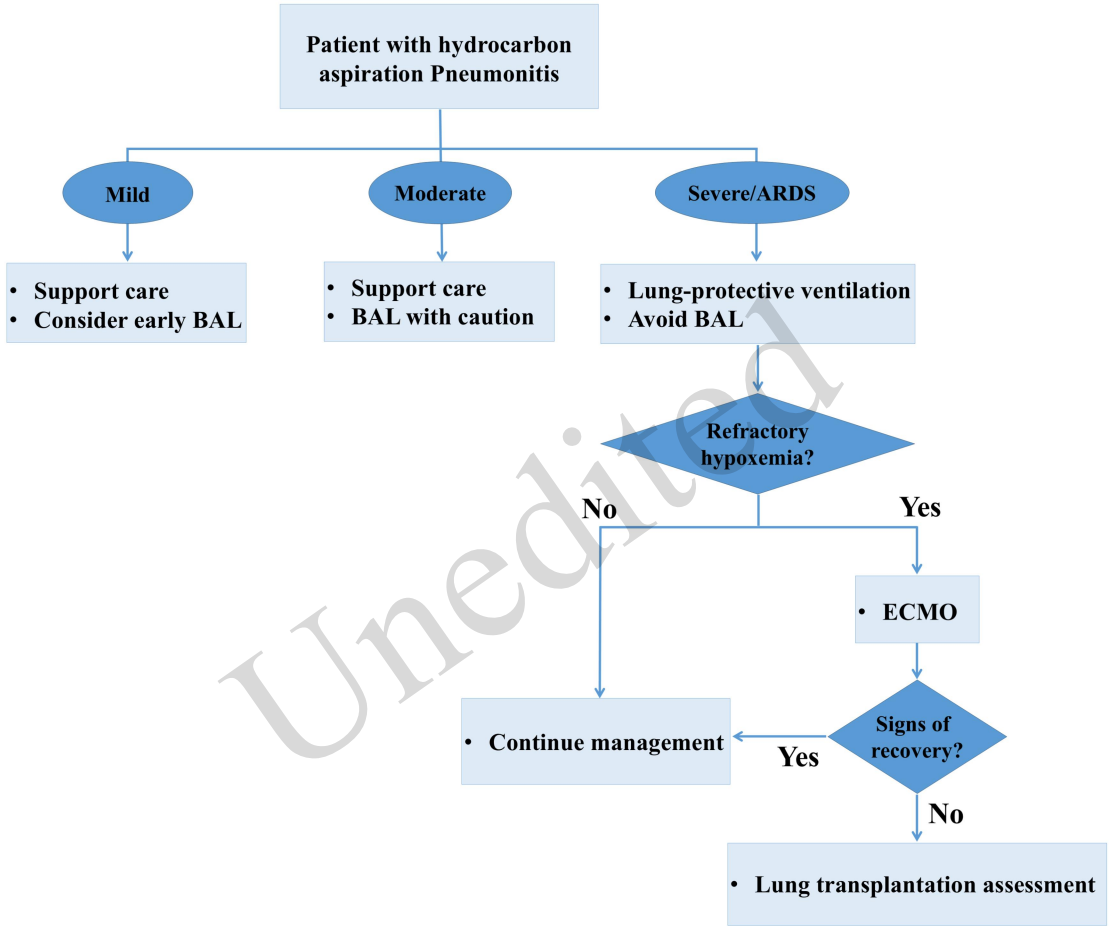

Unedited

Fig. 5 Proposed management for hydrocarbon aspiration pneumonitis based on disease severity
BAL: bronchoalveolar lavage; ECMO: extracorporeal membrane oxygenation

successful experiences in disease management.

5 Conclusions

The management of hydrocarbon aspiration pneumonitis requires a nuanced, severity-based approach. Our experience based on selected cases confirms that corticosteroids and empiric antibiotics form the cornerstone of medical therapy to mitigate inflammatory lung injury and prevent secondary infection. The decision to employ BAL must be highly selective; it may be considered in mild, early-presenting cases to evacuate irritants, while it is likely contraindicated in severe cases with extensive consolidation due to a significant risk of procedural complications. For patients progressing to irreversible respiratory failure despite maximal support, ECMO serves as a critical bridge to recovery or transplantation, remaining the definitive life-saving therapeutic option for end-stage lung damage. Ultimately, the timely recognition and structured escalation of care, guided by individualized patient assessment, are paramount to achieving favorable outcomes.

Data availability statement

The datasets used or analyzed during the current study are available from the corresponding author on reasonable request.

Acknowledgments

This work is supported by the National Key Research and Development Program of China (2023YFC3603100 and 2023YFC3603105), and the Project of Zhejiang Provincial Department of Education (No.Y202353933). We thank Wen Fang (the First Affiliated Hospital, School of Medicine, Zhejiang University, Hangzhou, China) for assisting with language editing.

Author contributions

Yuanqiang LU conceived and designed the study. Congying SONG and Ping WANG was responsible for the data collection and analysis. Congying SONG wrote the first draft of the manuscript. Yuanqiang LU and Ping WANG revised the manuscript. All authors have read and approved the final manuscript, and therefore, have full access to all the data in the study and take responsibility for the integrity and security of the data.

Compliance with ethics guidelines

Congying SONG, Ping WANG, and Yuanqiang LU declare that they have no conflict of interest.

All procedures followed were in accordance with the ethical standards of the responsible committee on human experimentation (institutional and national) and with the Helsinki Declaration of 1975, as revised in 2008. Informed consent was obtained from all patients for being included in the study. Approval was granted by the Ethics Committee of the First Affiliated Hospital of Zhejiang University School of Medicine (Approval No. 20240282).

Unedited

References

Abd-Elmawla MA, Ghaiad HR, Gad ES, et al., 2023. Suppression of nlrp3 inflammasome by ivermectin ameliorates bleomycin-induced pulmonary fibrosis. J Zhejiang Univ Sci B, 24(8):723-733. https://doi.org/10.1631/jzus.B2200385

Chang HY, Chen CW, Chen CY, et al., 1993. Successful treatment of diffuse lipoid pneumonitis with whole lung lavage. Thorax, 48(9):947-948. https://doi.org/10.1136/thx.48.9.947

Chen YJ, Hsu CC, Chen KT, 2019. Hydrocarbon pneumonitis following fuel siphonage: A case report and literature review. World J Emerg Med, 10(2):69-74. https://doi.org/10.5847/wjem.j.1920-8642.2019.02.001

Feng MX, Lu YQ, 2021. Performance of extracorporeal membrane oxygenation in patients with fatal paraquat poisoning: Grasp for straws? World J Emerg Med, 12(3):232-234. https://doi.org/10.5847/wjem.j.1920-8642.2021.03.013

Franquet T, Gomez-Santos D, Gimenez A, et al., 2000. Fire eater's pneumonia: Radiographic and ct findings. J Comput Assist Tomogr, 24(3):448-450. https://doi.org/10.1097/00004728-200005000-00017

Gregorio PHP, Toubat O, Crespo M, et al., 2025. Successful use of venopulmonary extracorporeal membrane oxygenation as a bridge to lung transplantation in a patient with idiopathic pulmonary arterial hypertension. J Cardiothorac Vasc Anesth, https://doi.org/10.1053/j.jvca.2025.07.004

Grossi E, Crisanti E, Poletti G, et al., 2006. Fire-eater's pneumonitis. Monaldi Arch Chest Dis, 65(1):59-61. https://doi.org/10.4081/monaldi.2006.590

Haciomeroglu O, Ekinci GH, Ongel EA, et al., 2014. Pneumonia caused by diesel fuel aspiration. J Coll Physicians Surg Pak, 24 Suppl 3:S272-274.

Hadda V, Khilnani GC, Bhalla AS, et al., 2009. Lipoid pneumonia presenting as non resolving community acquired pneumonia: A case report. Cases J, 2:9332. https://doi.org/10.1186/1757-1626-2-9332

Harris K, Chalhoub M, Maroun R, et al., 2011. Lipoid pneumonia: A challenging diagnosis. Heart Lung, 40(6):580-584. https://doi.org/10.1016/j.hrtlng.2010.12.003

Jaybhaye PL, Shilawant SS, 2014. Fatal case of hydrocarbon aspiration and use of lipoid cells as corroborative finding for rapid autopsy diagnosis in cases of delayed death. Toxicol Int, 21(3):316-318. https://doi.org/10.4103/0971-6580.155381

Kawashima M, Ijiri N, Konoeda C, et al., 2025. Extended use of central veno-arterial extracorporeal membrane oxygenation in lung transplantation for patients with pulmonary arterial hypertension. Eur J Cardiothorac Surg, 67(8) https://doi.org/10.1093/ejcts/ezaf256

Khanna P, Devgan SC, Arora VK, et al., 2004. Hydrocarbon pneumonitis following diesel siphonage. Indian J Chest Dis Allied Sci, 46(2):129-132.

Leong WC, Cheong BM, 2017. Siphoning diesel: A fatal mistake. Med J Malaysia, 72(5):314-315.

Li D, Wang P, Lu Y, 2024. Successful extracorporeal membrane oxygenation-assisted treatment for a kidney transplant recipient infected with severe covid-19. World J Emerg Med, 15(5):416-418.
https://doi.org/10.5847/wjem.j.1920-8642.2024.079

Marangu D, Gray D, Vanker A, et al., 2020. Exogenous lipoid pneumonia in children: A systematic review. Paediatr Respir Rev, 33:45-51.
https://doi.org/10.1016/j.prrv.2019.01.001

Sen V, Kelekci S, Selimoglu Sen H, et al., 2013. An evaluation of cases of pneumonia that occurred secondary to hydrocarbon exposure in children. Eur Rev Med Pharmacol Sci, 17 Suppl 1:9-12.

Shrestha TM, Bhatta S, Balayar R, et al., 2021. Diesel siphoner's lung: An unusual cause of hydrocarbon pneumonitis. Clin Case Rep, 9(1):416-419.
https://doi.org/10.1002/ccr3.3545

Shrivastava MS, Palkar AV, Karnik ND, 2011. Hydrocarbon pneumonitis masquerading as acute lung injury. BMJ Case Rep, 2011
https://doi.org/10.1136/bcr.03.2011.4017

Venkatnarayan K, Madan K, Walia R, et al., 2014. "Diesel siphoner's lung": Exogenous lipoid pneumonia following hydrocarbon aspiration. Lung India, 31(1):63-66.
https://doi.org/10.4103/0970-2113.125986

Xie W, Liu W, Wang L, et al., 2024. Roles of them4 in the akt pathway: A double-edged sword. J Zhejiang Univ Sci B, 25(7):541-556.
https://doi.org/10.1631/jzus.B2300457

Yi MS, Kim KI, Jeong YJ, et al., 2009. Ct findings in hydrocarbon pneumonitis after diesel fuel siphonage. AJR Am J Roentgenol, 193(4):1118-1121.
https://doi.org/10.2214/AJR.09.2471

Unedited