Journal of Zhejiang University-SCIENCE B (Biomedicine & Biotechnology) in press
www.jzus.zju.edu.cn; www.springer.com/journal/11585
E-mail: jzus_b@zju.edu.cn

Correspondence

https://doi.org/10.1631/jzus.B2500307

Sporadic Alzheimer's disease with bipolar-like features: a case report and a brief review of current research status

Lingzhuo KONG[1*], Yan YANG[1*], Weihua ZHOU[1], Shaohua HU[1,2,3,4,5,6,7]✉

[1]*Department of Psychiatry, the First Affiliated Hospital, Zhejiang University School of Medicine, Hangzhou, 310003, China*
[2]*Nanhu Brain-Computer Interface Institute, Hangzhou 310003, China*
[3]*The Zhejiang Key Laboratory of Precision Psychiatry, Hangzhou 310003, China*
[4]*MOE Frontier Science Center for Brain Science and Brain-Machine Integration, Zhejiang University School of Medicine, Hangzhou 310003, China*
[5]*Brain Research Institute of Zhejiang University, Hangzhou 310003, China*
[6]*Department of Psychology and Behavioral Sciences，Zhejiang University, Hangzhou 310003, China*
[7]*Zhejiang Engineering Center for Mathematical Mental Health, Hangzhou, 310003, China*

Unedited

Alzheimer's disease (AD) is among the main causes of cognitive impairment, memory loss and dementia, particularly in old adults. It has been listed as one the most expensive, lethal and burdening diseases of the 21st century, which develops with the process of aging worldwide (Scheltens et al., 2021). Currently, it is widely acknowledged that the typical pathogenesis of AD involves the deposition of amyloid-β (Aβ) and Tau protein in the cerebral parenchyma and vasculature, intraneuronal neurofibrillary tangles, and the gradual degeneration of synapses (Scheltens et al., 2016; Rostagno, 2022). According to several hypotheses, the abnormalities and dysfunctions of vascular structure, mitochondrail metabolism, oxidative stress, glucose utilization, and neuroinflammation are considered as fundamental for AD pathology (Scheltens, et al., 2016).

Affective disorders, mainly including depression and bipolar disorder (BD), mainly affect adolescents and young adults and can lead to adverse prognosis if not treated timely and systematically. Of note, for a definitive diagnosis of BD, according to The diagnostic and statistical manual of mental disorders, Fifth Edition, a single episode of mania (hypomania) should last for at least four days, with depression for at least two weeks. The pharmacotherapy of affective disorders mainly encompasses antidepressants, atypical antipsychotics and mood stabilizers, with the latter commonly applied among individuals with first onset of BD and blank medical history of psychiatric interventions (Bowden, 2005).

Patients with long-term affective disorders may present with cognitive deficits (O'brien, 2005; Sole et al., 2017). While emotional dysregulation also makes up part of the dementia syndrome (Huang et al., 2024), AD and affective disorders can nonetheless be usually distinguished with reference to demographic features, the regularity of emotional changes, imaging examinations, and drug effects. However, in some atypical cases, the clinical manifestations can be confusing, leading to delayed diagnosis and therapeutics, worsening the prognosis and resulting in a heavier disease burden.

Herein, we report the case of an AD patient with clinical manifestations similar to BD, who went through several therapeutic attempts before the disease approached stable status. This paper aims to summarize the

✉ Shaohua HU, dorhushaohua@zju.edu.cn
Shaohua HU, https://orcid.org/0000-0003-0570-670X

Received June 7, 2025; Revision accepted June 9, 2025;
Crosschecked xxx. xx, 20xx; Published online xxx. xx, 20xx

© Zhejiang University Press 2025

easy-to-misjudge symptoms, common underlying mechanisms, and possible therapeutic regimens to enhance current knowledge and clinical practice in this field.

A 75-year-old woman with primary education and living in the countryside visited the psychiatry department at the First Affiliated Hospital of Zhejiang University School of Medicine on July 15th, 2024, accompanied by family members living with her. She reported completely different mood states and behaviors between any two successive days: on the first day, she would be in extremely high spirit, laughing and talking endlessly of exaggerated content and doing extra farming or needlework, without much need for sleep (three to four hours in average). The next day her mood would turn down and she would lay in bed all day crying, sometimes with suicidal thoughts. On the third day, a high spirit similar to the first day would return. Her family members reported that such circulation had been happening for the past two years, with gradual loss of short-term memories, while distant memories were kept. Six months ago, the patient visited the neurology department and was diagnosed with suspected AD. She received donepezil (5 mg per night), memantine (10 mg per day), quetiapine (25 mg per night), and mecobalamin (0.5 mg three times a day), however, the emotional and behavioral abnormalities changes little. No personal or family history of affective disorders, dementia, stroke, brain injury, cardiovascular diseases, hypertension, metabolic diseases, or syphilis was present.

After signing in at the inpatient ward, the patient went through several examinations, all of which were done on the day the patient was in high spirit. The score of Mini-mental State Examination (MMSE) scale was 25 and Montreal Cognitive Assessment (MoCA) was 27, indicating normal cognitive functions. The score of Hamilton Anxiety Scale (HAMA) was 7, Hamilton Depression Scale (HAMD) was 5, and Young mania Rating Scale (YMRS) was 15, suggesting observed hypomania. A structured diagnostic interview was not carried out on the first day since the patient could not answer each question accurately. Physical examinations showed no peculiarities. Laboratory tests were performed, including blood routine examination, metabolism, coagulation function, thyroid profiles, infection, basic inflammatory state, and tumor indexes, and a few indexes were beyond normal (Table 1). Two indexes related to inflammation were elevated (Table 2). However, the patient refused to receive lumbar puncture, so we could not test the chemicals in the cerebrospinal fluid (CSF).

Unedited

Table 1 Results of laboratory tests beyond normal range (all tested in serum) examined during this time of hospitalization in psychiatric department

Indexes	Tested value	Normal range*
Urinary leukocyte	26.90 cells/μL	0.0-16.9 cells/μL
Ferritin	406.1 ng/mL	7.0-323.0 ng/mL
Albumin	39.9 g/L	40.0-55.0 g/L
Glutamyltranspeptidase	58 U/L	7-45 U/L
Uric acid	418 μmol/L	155-357 μmol/L
Very low-density lipoprotein-C	0.13 mmol/L	0.31-1.25 mmol/L
Creatine phosphokinase	237 U/L	40-200 U/L
Lactic dehydrogenase	284 U/L	120-250 U/L
Hydroxybutyrate dehydrogenase	215 U/L	72-182 U/L
D-dimer	920 μg/L FEU	0-700 μg/L FEU

*These are the reference ranges decided by the kits for laboratory examinations used in the First Affiliated Hospital of Zhejiang University School of Medicine. FEU: fibrinogen equivalent unit

Table 2 Results of laboratory tests directly or indirectly related to inflammation (all tested in serum) examined during this time of hospitalization in psychiatric department.

Indexes	Tested value	Normal range*
C-reactive protein	0.43 mg/L	0.00-8.00 mg/L
Lactic dehydrogenase (elevated)	284 U/L	120-250 U/L
Hydroxybutyrate dehydrogenase	215 U/L	72-182 U/L

(elevated)		
IL-1β	0.23 pg/mL	0-12.40 pg/mL
IL-2	0.84 pg/mL	0-5.71 pg/mL
IL-4	0.91 pg/mL	0-3.00 pg/mL
IL-5	0.54 pg/mL	0-3.10 pg/mL
IL-6	2.24 pg/mL	0-5.30 pg/mL
IL-8	7.40 pg/mL	0-20.6 pg/mL
IL-10	1.80 pg/mL	0-4.91 pg/mL
IL-17A	19.98 pg/mL	0-20.6 pg/mL
IL-12P70	1.03 pg/mL	0-3.40 pg/mL
IFN-α	0.90 pg/mL	0-8.50 pg/mL
IFN-γ	4.71 pg/mL	0-7.42 pg/mL
TNF-α	0.74 pg/mL	0-4.60 pg/mL

*These are the reference ranges decided by the kits for laboratory examinations used in the First Affiliated Hospital of Zhejiang University School of Medicine. IL: interleukin; IFN: interferon; TNF: tumor necrosis factor.

Unedited

The resting-state electroencephalogram showed a slightly slow background electrical rhythm and deficits in amplitude modulation. Besides, multiple thyroid nodules (one in the right lobe was TI-RADS type IV-a, the rest were all TI-RADS type III) were also detected via ultrasound. Brain magnetic resonance imaging (MRI) of AD sequence (1.5 T) routine scan revealed mild sclerosis of the bilateral hippocampus (MTA-1) and scattered high signals distributed in the frontal parietal cortex and white matter around the lateral ventricles (Fazekas-1), while no atrophy in other regions was reported (Fig. 1). The patient did not receive any other examinations during the hospitalization.

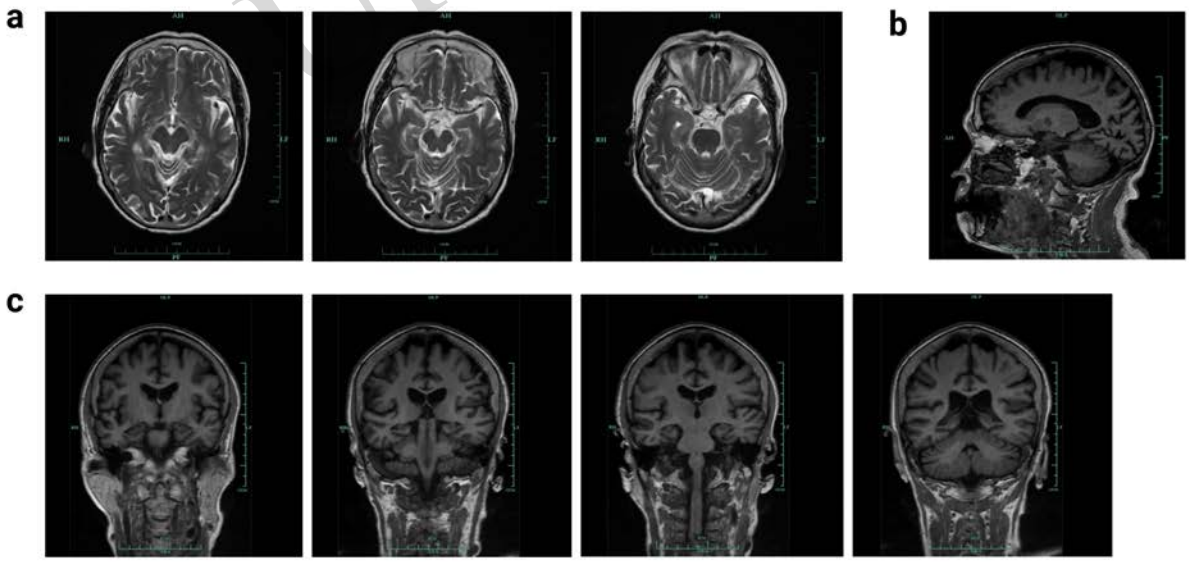

Fig. 1 Brain MRI results (mainly of the hippocampus levels). Plot a shows the T2 weighted images, cross-section. Plot b shows the T1 weighted image, vertical section. Plot c shows the T1 weighted images, cross-section.

After admission, the patient was treated with 150 mg manna capsule three times a day, 10 mg donepezil every night, 50 mg quetiapine every night, and 10 mg memantine every day. On the second day, 250 mg valproate at night was initiated to help stabilize her mood, and a structured diagnostic interview was carried out. Notably, the patient reported slight anxiety about her changeable mood states, which was mainly due to her worry of possible

secondary brain diseases such as cerebrovascular diseases and dementia. We failed to find any self-reported accompanied depressive symptoms closely correlated to the changing mood itself. However, the regularity of emotional and behavioral changes did not change much after four days. Then, quetiapine was gradually raised to 200 mg per night, while valproate was raised to 500 mg per night. On the tenth day after signing in, the patient reported the period of high spirit to decline to a few hours, while that of low mood to last for half a day. During the rest time, the mood stayed generally stable with normal sleep requirement (around 7 hours). Subsequently, an additional 250 mg of valproate was added during the daytime. The patient signed out from the inpatient ward 14 days after signing in, by which time her emotional and behavioral abnormalities had mostly disappeared and she was able for daily housework and social interactions. On the day of signing out, the score of MMSE was 26, MoCA was 27, HAMA was 3, HAMD was 4, and YMRS was 6.

At the one-month follow-up, the pharmacological regimens were kept after detailed estimation, and the disease stayed generally stable. The scores of MMSE and MoCA were both 26, HAMA was 2, HAMD remained 4, and YMRS remained 6. The patient also went through examinations of brain 18F-AV45 positron emission tomography-computed tomography (PET-CT) and MR enhanced T2 weighted angiography (ESWAN) with T2 fluid attenuated inversion recovery (FLAIR) (1.5T) imaging, and this examination was repeatedly tested two months later when she visited the outpatient section of the neurological department. The results showed significantly increased uptake of 18F-AV45 in the bilateral facial lobe, parietal lobe, temporal lobe, occipital lobe, cingulate gyrus, indicating elevated Aβ deposition. A microhemorrhagic focus was also noticed in the right front temporal lobe, while low signal foci of ESWAN were also observed to be distributed within the margin of the left ventricle (Fig. 2). Besides, no atrophy in other regions was reported. In addition, during the visit to the neurological department, the patient was tested for MMSE and MoCA once again, which reported values of 27 and 26, respectively. Accordingly, the final diagnosis was decided to be “AD with bipolar-like features”.

Unedited

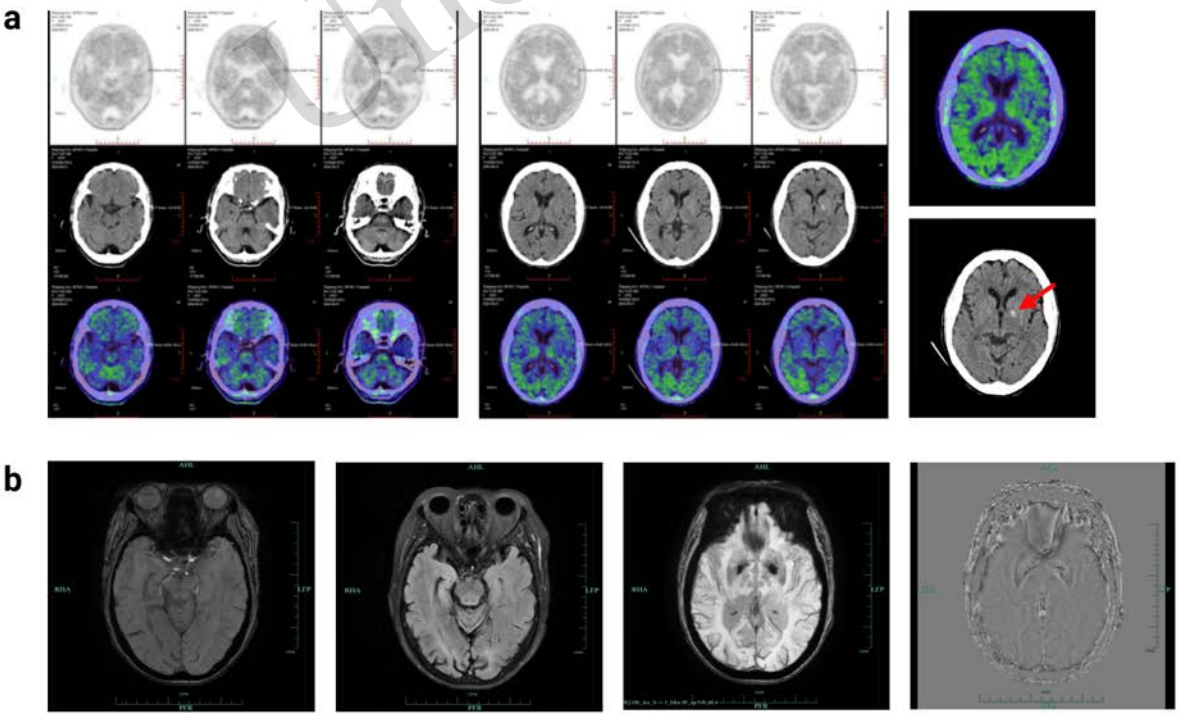

Fig. 2 Results of 18F-AV45 PET-CT (a) and MR ESWAN with T2 FLAIR (1.5T) imaging (b) (mainly of the hippocampus levels). The red arrow shows the microhemorrhagic focus in the right front temporal lobe. The patient went through another session of MR ESWAN with T2 FLAIR (1.5T) imaging examination two months later (in total, three months after hospitalization), and the images and reports were mostly in accordance with the previous one. Plot b shows the first instance of MR ESWAN with T2 FLAIR (1.5T) imaging.

In this case report, we characterized a 75-year-old woman with memory loss and changeable mood states and behaviors, who was diagnosed with AD after months of examinations and therapeutic attempts. With the aid of both anti-neurodegenerative and mood stabilizing pharmacotherapies, the disease approached generally stable status, with a partial recovery of social functions.

As is known, the typical process of AD is mainly divided into three stages: 1) Early stage: mainly presenting difficulties in declarative memory, with common accompanying depressive symptoms; 2) Processing stage: the cognitive function gradually and generally worsens, and disorders of thought, perception, affectivity, and behaviors also occur; 3) Late stage: neurological disturbances frequently occur, and self-care ability is lost completely (Forstl and Kurz, 1999). However, in this case, the patient did not show significant cognitive impairment, while the psychiatric manifestations (emotional changes, total duration since the onset, and, especially, the regularity of emotional changes) were obviously more severe and fluctuating compared to the reported common AD process. The possible diagnosis of somatic disease-induced dementia (e.g., stroke, hyperthyroidism and tertiary syphilis) could be easily excluded after examinations, leaving affective disorders (mainly BD) and frontotemporal dementia (FTD) for further differential diagnoses. As is known, a priority principle exists in the psychiatric diagnostic system, namely, if clinical and experimental evidence of dementia is detected, the main diagnosis should be considered as cognitive impairment, even though affective symptoms are also observed (Sachdev et al., 2014). In our case, the existence of manic symptoms was observed, so a diagnosis of unipolar depression was excluded. In addition, even though the woman presented with bipolar-like manifestations, deposition of Aβ plaques and hippocampus sclerosis—the "gold standard" of AD—were found, indicating the diagnosis of neurodegeneration to be superior. Also, both depressive and manic states lasted for less than two days, which was discordant with the acknowledged diagnostic standard of BD (Anderson et al., 2012).

FTD was also considered for the rapid changes in mood states. A recent systematic review showed that along with the progression of AD, mania-like symptoms can occur, and such symptoms have also been observed among patients with cognition decline in FTD (Elefante et al., 2023). Overlaps in the cognitive and behavioral features, default mode network and the salience network, as well as genetic differences were also summarized (Zhou and Seeley, 2014; Goldman and Van Deerlin, 2018; Musa et al., 2020; Leocadi et al., 2023). In our patient, FTD was eventually excluded afterwards since (1) abnormalities indicating the pyramidal and extrapyramidal system damage were not observed through repeated physical examinations; (2) brain MRI and PET-CT did not show asymmetric atrophy of the frontal and temporal lobes or difference in metabolism. However, the lack of pathological examinations including Pick cells and Pick bodies, Tau quantification, and Aβ fragments limited further differential diagnoses. Nevertheless, changes in the emotional states, personality, and cognitive scale scoring in this case did not significantly deviate from the acknowledged values, and the diagnosis needed to be confirmed by additional imaging methods. As such, special emotional fluctuation patterns may be observed in some cases of AD at the early stage, which are easily confused with FTD, thus requiring further laboratory and imaging tests.

According to current knowledge, the pathology of AD mainly focuses on several specific changes in the central nervous system, namely, deposition of Aβ plaques, excessive phosphorylation of Tau protein, and neurofibrillary tangles, while neuroimaging features such as hippocampal atrophy and sclerosis are also listed as strong diagnostic evidence (Deture and Dickson, 2019). However, previous pharmacological tests carried out in mouse models were found to be inefficient in certain populations of AD patients, which might be due to the heterogeneity between different AD subtypes. For instance, a study carried out in 2021 reported several molecular AD subtypes corresponding to different combinations of dysregulated pathways (Neff et al., 2021) In addition, based on the distribution of tau-related pathology and regional brain atrophy, limbic-predominant AD and hippocampal-sparing AD were identified from the typical cases (Ferreira et al., 2020). Of note, such subtypes differ from each other in the onset age, assessment age, gender difference, education duration, extent and process of cognitive impairment, APOE ε4 genotype, and biomarker levels in the peripheral and central environment, which might produce valuable information aiding early diagnosis and personal therapeutics. However, at present,

Unedited

there is a lack of evidence to determine which subtype our reported case should be classified as, raising concerns that 1) atypical AD exists and its clinical features might be different from the previously known "mainly and especially cognitive impairment" manifestation; 2) current psychiatric and neurological treatments of AD should be re-evaluated and expanded to suit the atypical subtypes.

For the differential diagnosis of AD with emotional deficits and affective disorders, shared neuropathology exists that partly explains the common symptoms (Huang, et al., 2024). In fact, a bi-directional interaction pattern between AD and emotional changes has been promoted. On the one hand, a meta-analysis suggested the accompanied depression and anxiety of AD to be rooted in the degeneration of neural circuits within emotional processing regions, with the underlying mechanisms including atrophy of the frontal-limbic system, elevated strychnine-sensitive glycine receptor functioning, selective reduction of N-methyl-D-aspartate receptor NR2A density, as well as the neurotoxicity of Aβ, t-Tau, and p-Tau (Botto et al., 2022). In addition, emotional abnormalities can also act as a subsequent reaction of cognitive deficits and loss of social functions (Botto, et al., 2022). On the other hand, affective disorders might also increase the risk of subsequent dementia (Da Silva et al., 2013). Meanwhile, lifted amyloid levels were found in the CSF among old adults with major depression, who showed elevated possibility of developing subsequent AD (Harrington et al., 2015; Xu et al., 2021), while antidepressants might reduce the incidence of AD by stabilizing neuroinflammation in the central nervous system via lifting the levels of anti-inflammatory cytokine transforming growth factor β1 (Botto, et al., 2022). In addition, higher levels of Tau in the serum, CSF, and brain regions were detected among old adults without cognitive deficits, among which the possibility of developing cognitive deficits is twice higher than those with normal Tau levels (Babulal et al., 2020). Meanwhile, there is much less evidence of the association between mania (hypomania) and AD. The difference in biomarkers of AD between individuals with BD and healthy controls was found to be smaller, but abnormalities of amyloid production/clearance during an acute episode of BD was found to be similar as AD pathology (Knorr et al., 2022). Nevertheless, differential diagnosis should also be addressed, since the accompanied emotional symptoms could also occur during the process of AD. For example, the self-insight remains in the early stage of AD, and the patient might realize the gradual weakening of memory, changeable state of emotions, and cognitive decline, which might also lead to secondary emotional deficits.

According to previous research, the shared mechanisms between AD and affective disorders (e.g., depression, BD) may include chronic inflammation (Vogelgsang et al., 2020), dysfunction of the gut microbiota (Generoso et al., 2021), the subsequent temporal or frontal cortex dysfunction (Robbins et al., 1996), and deficit in adult hippocampus neurogenesis (Berger et al., 2020). It was previously reported that reduced hippocampal volume, decreased numbers of granule neurons in the hippocampus, as well as decreased vascularization of the neurogenic niche were found by neuroimaging methodologies in patients with major depressive disorder, while intervention by antidepressants might help increase the number of neural progenitor cells in the hippocampus (Tae et al., 2011; Boldrini et al., 2012; Huang et al., 2013). At the same time, evidence of hippocampus neurogenesis including reduction in hippocampal neurons and DCX+ neuroblasts was also found in both animal models and AD patients (West et al., 1994; Jin et al., 2004; Choi and Tanzi, 2019; Toda et al., 2019). In addition, shared genetic risks located specially in the hippocampus area were found to be associated with several processes of neurogeneration (Xu et al., 2018), which further strengthens the notion of hippocampus neurogenesis in the pathogenesis of both AD and emotional dysregulation.

Notably, long-lasting neuroinflammation has been attracting more and more interest. T helper 17 (Th17) cells are among the CD4+ Th subpopulation producing inflammatory cytokines that induce local and systematic inflammation, activating microglia, and recruiting other immune cell types. It was found that encephalitogenic inflammatory Th17 plays a role in the dysfunction of gut-brain axis (GBA) and chronic neuroinflammation, directly or indirectly accelerating the process of AD and depression (Shi et al., 2022). Another notable issue is GBA. It was reported that gut microbiota and their metabolics are crucial for leaky gut, over-activated microglia, and subsequent neuroinflammation (Carloni and Rescigno, 2023). Compared to healthy controls, patients with AD and major depression had higher abundances of bacteria with pro-inflammatory properties and lower levels of short-chain fatty acids (Russo et al., 2018; Eicher and Mohajeri, 2022). Meanwhile, according to the results of

Unedited

laboratory test in the presented case, two indexes related to inflammatory state—the lactic dehydrogenase and hydroxybutyrate dehydrogenase—were found to be elevated in the serum compared to the normal range (Table 2), which might partly supports the hypothesis that chronic inflammation plays a part in linking AD to emotional dysregulation. However, indexes that are more directly linked to general inflammatory state such as cytokines and C-reactive protein failed to show significant changes, suggesting that the reliability and applicability of such hypothesis still need further confirmation. Furthermore, since neither we obtained the CSF sample nor we conducted lymphocyte typing, the more accurate parameters of inflammation and neurodegeneration could not be tested, adding to the current limited understanding and persisting challenges.

Despite the current limitations, it can still be speculated that the depression- and mania-like performance in this case might be attributed to chronic AD progressing, since current examination and laboratory tests indicated no other possible neurological or psychiatric pathogenesis that could fully explain the functional changes in the brain. Meanwhile, the two-day strict regularity raises another dilemma. Usually, the accompanied emotional changes in AD would not display obvious regularity, while for affective disorders, such short cycle of the emotional rhythm also does not meet the diagnostic criteria. Obviously, both are not suitable for this case. The "switch" mechanism of emotions has been linked to the photoperiodic and activating-dormancy rhythm (Raitiere, 2022), since the length of photoperiod is correlated with switches in neurotransmitter expression in specific brain regions, such as elevated expression of catecholaminergic expression during activated periods and raised expression of somatostatin and corticotrophin releasing factor during inhibited periods (Young and Dulcis, 2015). Although the existing evidence could not fully explain the strict regularity of emotional states in this case due to the limitation of methodology and the necessity to track the neurotransmitter expression, it is supposed that the changes might be due to both AD pathology and the interactions between auto-biorhythm and photoperiodicity.

Another issue is therapeutics. It is recommended that for short-term intervention by mood stabilizers, electroconvulsive therapy might be effective, while antipsychotics treatment needs to be weighted by its adverse effects (Elefante, et al., 2023). In our case, a total daily dosage of 750 mg valproate and 200 mg quetiapine was initiated for stabilizing the mood, which was proven to be effective in the subsequent observation. Some previous studies have confirmed the neuroprotective effects of low-to-moderate dose of lithium on AD (Hamstra et al., 2023), while there is also evidence to the contrary (Cheng et al., 2017; Devanand et al., 2022). In this case, lithium was not applied due to its influence on thyroid functions (Mcknight et al., 2012; Kong et al., 2024), especially among female individuals (Bauer et al., 2014), since this patient was detected to have thyroid nodules of high risk. Besides, long-term treatment of valproate might be beneficial for AD in the early stage and with mania-like performance, since the pharmacological mechanism of valproate shows both mood stabilizing and neuroprotective effects (Tariot et al., 2002). It has also been established that selective serotonin reuptake inhibitors can reduce Aβ plaque formation and promoting hippocampal neurogenesis (Khoury and Grossberg, 2019), whereas the clinical effect of antidepressants remains controversial (Orgeta et al., 2017). Besides, previous studies have also shown that atypical antipsychotics could partly reduce manic symptoms in AD (Muhlbauer et al., 2021), and low-dose quetiapine (average of 37.5 mg per day) could improve the neuropsychiatric symptoms (Miziak et al., 2021; Li et al., 2024). However, for those with AD with advanced stage and significant deficits of brain functions, quetiepine at 500-100 mg per day might result in a greater cognitive decline (Ballard et al., 2005). Hence, we recommend low-to-moderate dose of combined valproate and quetiapine for patients with early-stage AD and no personal history of other somatic disease as adjuvant treatments for significant emotional dysregulation.

This report describes a case of an elderly woman with AD accompanied by bipolar-like features. Shared mechanisms between AD and mood abnormalities have been gradually elucidated during the examinations, among which the dysregulation of neurotransmitters, neuroinflammation, and deposition of toxic proteins were widely explored. For treatment of this and similar conditions, we recommend combined therapies of anti-neurodegeneration agencies, neuroprotective drugs, mood stabilizers, and antipsychotics.

Data availability statement

The data that support the findings of this study are available from the corresponding author (Shao-hua HU) upon reasonable

Unedited

request.

Acknowledgments

We would like to thank the online tools provided by BioRender.com (https://app.biorender.com/), which supported us to manage the separate figures as a summarized one.

Author contributions

Ling-zhuo KONG and Yan YANG did examination of the patient, took the medical history, searched literature and wrote the manuscript; Wei-hua ZHOU examined the patient and guided the diagnostic and therapeutic process; Shao-hua HU did examination of the patient, searched literature, conceptualized and edited the paper.

All authors read and approved the final manuscript and, therefore, had full access to all the data in the study and take responsibility for the integrity and security of the data.

Compliance with ethics guidelines

Ling-zhuo KONG, Yan YANG, Wei-hua ZHOU, and Shao-hua HU declares that they have no conflict of interest.

All procedures followed were in accordance with the ethical standards of the responsible committee on human experimentation (institutional and national) and with the Helsinki Declaration of 1975, as revised in 2008 (5). Informed consent was obtained from all patients for being included in the study. Additional informed consent was obtained from all patients for whom identifying information is included in this article. Since this study is a clinical case report, the approval of the Institutional Review Boards or Ethics Committee is omitted. The patient of this case study agreed to publish her data in a journal article.

Unedited

References

Anderson IM, Haddad PM, Scott J, 2012. Bipolar disorder. BMJ, 345:e8508.
https://doi.org/10.1136/bmj.e8508

Babulal GM, Roe CM, Stout SH, et al., 2020. Depression is associated with tau and not amyloid positron emission tomography in cognitively normal adults. J Alzheimers Dis, 74(4):1045-1055.
https://doi.org/10.3233/JAD-191078

Ballard C, Margallo-Lana M, Juszczak E, et al., 2005. Quetiapine and rivastigmine and cognitive decline in alzheimer's disease: Randomised double blind placebo controlled trial. BMJ, 330(7496):874.
https://doi.org/10.1136/bmj.38369.459988.8F

Bauer M, Glenn T, Pilhatsch M, et al., 2014. Gender differences in thyroid system function: Relevance to bipolar disorder and its treatment. Bipolar Disord, 16(1):58-71.
https://doi.org/10.1111/bdi.12150

Berger T, Lee H, Young AH, et al., 2020. Adult hippocampal neurogenesis in major depressive disorder and alzheimer's disease. Trends Mol Med, 26(9):803-818.
https://doi.org/10.1016/j.molmed.2020.03.010

Boldrini M, Hen R, Underwood MD, et al., 2012. Hippocampal angiogenesis and progenitor cell proliferation are increased with antidepressant use in major depression. Biol Psychiatry, 72(7):562-571.
https://doi.org/10.1016/j.biopsych.2012.04.024

Botto R, Callai N, Cermelli A, et al., 2022. Anxiety and depression in alzheimer's disease: A systematic review of pathogenetic mechanisms and relation to cognitive decline. Neurol Sci, 43(7):4107-4124.
https://doi.org/10.1007/s10072-022-06068-x

Bowden CL, 2005. Atypical antipsychotic augmentation of mood stabilizer therapy in bipolar disorder. J Clin Psychiatry, 66 Suppl 3:12-19.

Carloni S, Rescigno M, 2023. The gut-brain vascular axis in neuroinflammation. Semin Immunol, 69:101802.
https://doi.org/10.1016/j.smim.2023.101802

Cheng C, Zandi P, Stuart E, et al., 2017. Association between lithium use and risk of alzheimer's disease. J Clin Psychiatry, 78(2):e139-e145.
https://doi.org/10.4088/JCP.15m10304

Choi SH, Tanzi RE, 2019. Is alzheimer's disease a neurogenesis disorder? Cell Stem Cell, 25(1):7-8.
https://doi.org/10.1016/j.stem.2019.06.001

Da Silva J, Goncalves-Pereira M, Xavier M, Mukaetova-Ladinska EB, 2013. Affective disorders and risk of developing dementia: Systematic review. Br J Psychiatry, 202(3):177-186.
https://doi.org/10.1192/bjp.bp.111.101931

Deture MA, Dickson DW, 2019. The neuropathological diagnosis of alzheimer's disease. Mol Neurodegener, 14(1):32.

https://doi.org/10.1186/s13024-019-0333-5
Devanand DP, Crocco E, Forester BP, et al., 2022. Low dose lithium treatment of behavioral complications in alzheimer's disease: Lit-ad randomized clinical trial. Am J Geriatr Psychiatry, 30(1):32-42.
https://doi.org/10.1016/j.jagp.2021.04.014
Eicher TP, Mohajeri MH, 2022. Overlapping mechanisms of action of brain-active bacteria and bacterial metabolites in the pathogenesis of common brain diseases. Nutrients, 14(13).
https://doi.org/10.3390/nu14132661
Elefante C, Brancati GE, Torrigiani S, et al., 2023. Bipolar disorder and manic-like symptoms in alzheimer's, vascular and frontotemporal dementia: A systematic review. Curr Neuropharmacol, 21(12):2516-2542.
https://doi.org/10.2174/1570159X20666220706110157
Ferreira D, Nordberg A, Westman E, 2020. Biological subtypes of alzheimer disease: A systematic review and meta-analysis. Neurology, 94(10):436-448.
https://doi.org/10.1212/WNL.0000000000009058
Forstl H, Kurz A, 1999. Clinical features of alzheimer's disease. Eur Arch Psychiatry Clin Neurosci, 249(6):288-290.
https://doi.org/10.1007/s004060050101
Generoso JS, Giridharan VV, Lee J, et al., 2021. The role of the microbiota-gut-brain axis in neuropsychiatric disorders. Braz J Psychiatry, 43(3):293-305.
https://doi.org/10.1590/1516-4446-2020-0987
Goldman JS, Van Deerlin VM, 2018. Alzheimer's disease and frontotemporal dementia: The current state of genetics and genetic testing since the advent of next-generation sequencing. Mol Diagn Ther, 22(5):505-513.
https://doi.org/10.1007/s40291-018-0347-7
Hamstra SI, Roy BD, Tiidus P, et al., 2023. Beyond its psychiatric use: The benefits of low-dose lithium supplementation. Curr Neuropharmacol, 21(4):891-910.
https://doi.org/10.2174/1570159X20666220302151224
Harrington KD, Lim YY, Gould E, Maruff P, 2015. Amyloid-beta and depression in healthy older adults: A systematic review. Aust N Z J Psychiatry, 49(1):36-46.
https://doi.org/10.1177/0004867414557161
Huang Y, Coupland NJ, Lebel RM, et al., 2013. Structural changes in hippocampal subfields in major depressive disorder: A high-field magnetic resonance imaging study. Biol Psychiatry, 74(1):62-68.
https://doi.org/10.1016/j.biopsych.2013.01.005
Huang YY, Gan YH, Yang L, et al., 2024. Depression in alzheimer's disease: Epidemiology, mechanisms, and treatment. Biol Psychiatry, 95(11):992-1005.
https://doi.org/10.1016/j.biopsych.2023.10.008
Jin K, Peel AL, Mao XO, et al., 2004. Increased hippocampal neurogenesis in alzheimer's disease. Proc Natl Acad Sci U S A, 101(1):343-347.
https://doi.org/10.1073/pnas.2634794100
Khoury R, Grossberg GT, 2019. Impact of antidepressant use on the trajectory of alzheimer's disease: Evidence, mechanisms, and therapeutic implications. CNS Drugs, 33(1):17-29.
https://doi.org/10.1007/s40263-018-0590-9
Knorr U, Simonsen AH, Jensen CS, et al., 2022. Alzheimer's disease related biomarkers in bipolar disorder - a longitudinal one-year case-control study. J Affect Disord, 297:623-633.
https://doi.org/10.1016/j.jad.2021.10.074
Kong L, Shen Y, Hu S, Lai J, 2024. The impact of quetiapine monotherapy or in combination with lithium on the thyroid function in patients with bipolar depression: A retrospective study. CNS Neurosci Ther, 30(2):e14342.
https://doi.org/10.1111/cns.14342
Leocadi M, Canu E, Paldino A, et al., 2023. Awareness impairment in alzheimer's disease and frontotemporal dementia: A systematic mri review. J Neurol, 270(4):1880-1907.
https://doi.org/10.1007/s00415-022-11518-9
Li KY, Lin BT, Hsu ST, et al., 2024. Quetiapine oral solution in alzheimer's disease: Efficacy and dosage insights from a real-world retrospective study. J Alzheimers Dis, 97(2):805-811.
https://doi.org/10.3233/JAD-231007
Mcknight RF, Adida M, Budge K, et al., 2012. Lithium toxicity profile: A systematic review and meta-analysis. Lancet, 379(9817):721-728.
https://doi.org/10.1016/S0140-6736(11)61516-X
Miziak B, Blaszczyk B, Czuczwar SJ, 2021. Some candidate drugs for pharmacotherapy of alzheimer's disease. Pharmaceuticals (Basel), 14(5).

Unedited

https://doi.org/10.3390/ph14050458
Muhlbauer V, Mohler R, Dichter MN, et al., 2021. Antipsychotics for agitation and psychosis in people with alzheimer's disease and vascular dementia. Cochrane Database Syst Rev, 12(12):CD013304.
https://doi.org/10.1002/14651858.CD013304.pub2
Musa G, Slachevsky A, Munoz-Neira C, et al., 2020. Alzheimer's disease or behavioral variant frontotemporal dementia? Review of key points toward an accurate clinical and neuropsychological diagnosis. J Alzheimers Dis, 73(3):833-848. https://doi.org/10.3233/JAD-190924
Neff RA, Wang M, Vatansever S, et al., 2021. Molecular subtyping of alzheimer's disease using rna sequencing data reveals novel mechanisms and targets. Sci Adv, 7(2).
https://doi.org/10.1126/sciadv.abb5398
O'brien J, 2005. Dementia associated with psychiatric disorders. Int Psychogeriatr, 17 Suppl 1:S207-221.
https://doi.org/10.1017/s1041610205002036
Orgeta V, Tabet N, Nilforooshan R, Howard R, 2017. Efficacy of antidepressants for depression in alzheimer's disease: Systematic review and meta-analysis. J Alzheimers Dis, 58(3):725-733. https://doi.org/10.3233/JAD-161247
Raitiere MN, 2022. The elusive "switch process" in bipolar disorder and photoperiodism: A hypothesis centering on nadph oxidase-generated reactive oxygen species within the bed nucleus of the stria terminalis. Front Psychiatry, 13:847584.
https://doi.org/10.3389/fpsyt.2022.847584
Robbins TW, Elliott R, Sahakian BJ, 1996. Neuropsychology--dementia and affective disorders. Br Med Bull, 52(3):627-643.
https://doi.org/10.1093/oxfordjournals.bmb.a011572
Rostagno AA, 2022. Pathogenesis of alzheimer's disease. Int J Mol Sci, 24(1).
https://doi.org/10.3390/ijms24010107
Russo R, Cristiano C, Avagliano C, et al., 2018. Gut-brain axis: Role of lipids in the regulation of inflammation, pain and cns diseases. Curr Med Chem, 25(32):3930-3952.
https://doi.org/10.2174/0929867324666170216113756
Sachdev PS, Blacker D, Blazer DG, et al., 2014. Classifying neurocognitive disorders: The dsm-5 approach. Nat Rev Neurol, 10(11):634-642.
https://doi.org/10.1038/nrneurol.2014.181
Scheltens P, Blennow K, Breteler MM, et al., 2016. Alzheimer's disease. Lancet, 388(10043):505-517.
https://doi.org/10.1016/S0140-6736(15)01124-1
Scheltens P, De Strooper B, Kivipelto M, et al., 2021. Alzheimer's disease. Lancet, 397(10284):1577-1590.
https://doi.org/10.1016/S0140-6736(20)32205-4
Shi Y, Wei B, Li L, et al., 2022. Th17 cells and inflammation in neurological disorders: Possible mechanisms of action. Front Immunol, 13:932152.
https://doi.org/10.3389/fimmu.2022.932152
Sole B, Jimenez E, Torrent C, et al., 2017. Cognitive impairment in bipolar disorder: Treatment and prevention strategies. Int J Neuropsychopharmacol, 20(8):670-680.
https://doi.org/10.1093/ijnp/pyx032
Tae WS, Kim SS, Lee KU, et al., 2011. Hippocampal shape deformation in female patients with unremitting major depressive disorder. AJNR Am J Neuroradiol, 32(4):671-676.
https://doi.org/10.3174/ajnr.A2367
Tariot PN, Loy R, Ryan JM, et al., 2002. Mood stabilizers in alzheimer's disease: Symptomatic and neuroprotective rationales. Adv Drug Deliv Rev, 54(12):1567-1577.
https://doi.org/10.1016/s0169-409x(02)00153-9
Toda T, Parylak SL, Linker SB, Gage FH, 2019. The role of adult hippocampal neurogenesis in brain health and disease. Mol Psychiatry, 24(1):67-87.
https://doi.org/10.1038/s41380-018-0036-2
Vogelgsang J, Hessmann P, Wolff-Menzler C, et al., 2020. Prevalence of affective disorders and dementia in inflammatory polyarthropathies. Eur Arch Psychiatry Clin Neurosci, 270(2):247-252.
https://doi.org/10.1007/s00406-019-01015-y
West MJ, Coleman PD, Flood DG, Troncoso JC, 1994. Differences in the pattern of hippocampal neuronal loss in normal ageing and alzheimer's disease. Lancet, 344(8925):769-772.
https://doi.org/10.1016/s0140-6736(94)92338-8
Xu J, Li Q, Qin W, et al., 2018. Neurobiological substrates underlying the effect of genomic risk for depression on the conversion of amnestic mild cognitive impairment. Brain, 141(12):3457-3471.
https://doi.org/10.1093/brain/awy277
Xu W, Feng W, Shen XN, et al., 2021. Amyloid pathologies modulate the associations of minimal depressive symptoms with

Unedited

cognitive impairments in older adults without dementia. Biol Psychiatry, 89(8):766-775.
https://doi.org/10.1016/j.biopsych.2020.07.004

Young JW, Dulcis D, 2015. Investigating the mechanism(s) underlying switching between states in bipolar disorder. Eur J Pharmacol, 759:151-162.
https://doi.org/10.1016/j.ejphar.2015.03.019

Zhou J, Seeley WW, 2014. Network dysfunction in alzheimer's disease and frontotemporal dementia: Implications for psychiatry. Biol Psychiatry, 75(7):565-573.
https://doi.org/10.1016/j.biopsych.2014.01.020

Unedited