

## Corneal relaxing incision combined with phacoemulsification and IOL implantation

SHEN Ye (沈 晔)<sup>†</sup>, TONG Jian-ping (童剑萍), LI Yu-min (李毓敏)

(Eye Center, First Affiliated Hospital, College of Medicine, Zhejiang University, Hangzhou 310003, China)

<sup>†</sup>E-mail: syzyec@hzcnc.com

Received Jan. 19, 2004; revision accepted May 1, 2004

**Abstract:** Objective: To analyze the effectiveness and safety of corneal relaxing incisions (CRI) in correcting keratometric astigmatism during cataract surgery. Methods: A prospective study of two groups: control group and treatment group. A treatment group included 25 eyes of 25 patients who had combined clear corneal phacoemulsification, IOL implantation and CRI. A control group included 25 eyes of 25 patients who had clear corneal phacoemulsification and IOL implantation. Postoperative keratometric astigmatism was measured at 1 week, 1 month, 3 months and 6 months. Results: CRI significantly decreased keratometric astigmatism in patients with preexisting astigmatism compared with astigmatic changes in the control group. In eyes with CRI, the mean keratometric astigmatism was  $0.29 \pm 0.17$  D (range 0 to 0.5 D) at 1 week,  $0.41 \pm 0.21$  D (range 0 to 0.82 D) at 1 month, respectively reduced by 2.42 D and 2.30 D at 1 week and 1 month postoperatively ( $P=0.000$ ,  $P=0.000$ ), and postoperative astigmatism was stable until 6 months follow-up. The keratometric astigmatism of all patients decreased to less than 1.00 D postoperatively. Conclusions: CRI is a practical, simple, safe and effective method to reduce preexisting astigmatism during cataract surgery. A modified nomogram is proposed. The long-term effect of CRI should be investigated.

**Key words:** Astigmatism, Corneal relaxing incision, Cataract

**Document code:** A

**CLC number:** TU31

### INTRODUCTION

The advent of phacoemulsification, foldable intraocular lenses (IOLs), and improved incision designs has decreased the incidence and extent of surgically induced astigmatism in cataract patients. Approximately 15% to 20% of cataract patients, however, have more than 1.5 diopters (D) of keratometric astigmatism, refractive astigmatism, or both (Hoffer, 1980). Interest in reducing preexisting astigmatism simultaneously with cataract surgery has grown in recent years. Available options include a clear corneal cataract incision along the steep meridian (Lyhne *et al.*, 1998), astigmatic keratotomy (AK) (Akura *et al.*, 2000), toric IOL implantation (Leyland *et al.*, 2001; Sun *et al.*, 2000),

opposite clear corneal incision (Lever and Dahan, 2000), and limbal relaxing incisions (LRIs) or corneal relaxing incisions (CRIs) (Gills, 1994; Muller-Jensen *et al.*, 1999). According to Budak and Friedman, CRI is effective in eyes with astigmatism. In this study, we analyzed the effectiveness of CRI in 25 eyes of 25 patients.

### PATIENTS AND METHODS

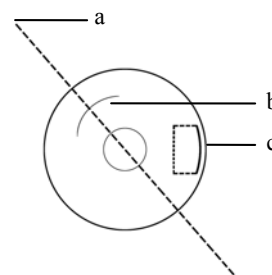
During October 2000 to May 2003 cataract patients with more than 1.0 D astigmatism were included in this study. Based on the patients' willingness, all patients were divided into two groups: control group and treatment group. The tre-

atment group included patients who had combined clear corneal phacoemulsification, IOL implantation and CRI. The control group included patients who had traditional clear corneal phacoemulsification and IOL implantation. Patients with irregular corneal astigmatism or astigmatism due to pterygium were excluded.

A complete general ophthalmic examination was done in all patients with uncorrected visual acuity (UCVA), best spectacle-corrected visual acuity (BSCVA), keratometry and autorefractometer readings, slitlamp and retinal evaluation, tonometry, pachymetry, and corneal topography.

Before surgery, a drawing noting was identified with a marker dyed on the meridian of astigmatism to minimize the effect of eye rotation on surgical accuracy. Pachymetric readings were taken at the position of 3.5 mm away from the cornea center. Then CRI was made with an RK diamond knife, to a depth of 95% corneal thickness and centered along the meridian of the astigmatism. The CRI length was decided according to the nomogram based on preoperative keratometric astigmatism measured by keratometry, and age of patients (Table 1). Superior CRI was made for With-the-rule (WTR) astigmatism and nasal CRI for Against-the-rule (ATR) astigmatism (Fig.1).

Phacoemulsification and foldable IOL implantation were performed through the 3.0 to 3.2 mm temporal clear corneal incision. The clear corneal incision was placed along 180-degree meridian in right eyes and 30-degree meridian in left eyes. Cataract surgery was done at the conclusion of CRI procedure. All procedures were performed by 1 surgeon. The power of the intraocular lens was cal-



**Fig.1 Diagrammatic sketch of the surgery**  
a: meridian of astigmatism; b: CRI; c: incision of Phaco

culated with SK-II formula using lower keratometric reading preoperative to avoid hyperopic refractive situation postoperation.

All the patients were prescribed 0.3% ofloxacin 4 times a day in the first week postoperatively. FML (0.1%) was also given 4 times a day for 1 week, 3 times a day for 1 week, 2 times a day for 1 week, 1 time a day for 1 week. Postoperative keratometric astigmatism was measured at 1 week, 1 month, 3 months, 6 months. Independent *T* test and paired *T* test were used to analysis the difference between the two groups and the astigmatism changes of the treatment group postoperatively.

**RESULTS**

The treatment group included 25 eyes of 25 patients. The mean age of the 11 men and 14 women was 60.88±2.47 years (range 55 to 65 years). The mean preoperative keratometric astigmatism was 2.77±0.74 D (range 1.5 to 4.5 D). The control group included 25 eyes of 25 patients. The mean age of the 12 men and 13 women was 59.96±2.40 years (range 56 to 65 years). The mean preoperative keratometric astigmatism was 2.81±0.59 D (range 2.0 to 4.0 D).

**Treatment group**

In eyes with CRI, the mean keratometric astigmatism was 0.29±0.17 D (range 0 to 0.5 D) 1 week, 0.41±0.21 D (range 0 to 0.82 D) 1 month, 0.42±0.14 D (range 0.12 to 0.75) 3 months and 0.49±0.13 D (0.25 to 0.75 D) 6 months respectively reduced by 2.42 D, 2.30 D, 2.29 D and 2.20 D postoperatively with statistical significance of

**Table 1 The nomogram of CRI**

Age	Effect (Dioptor of astigmatism corrected/mm)
20~29	0.40
30~40	0.45
40~49	0.55
50~59	0.60
60~70	0.65
70~79	0.75

Note: 1. Depth ≥90% corneal thickness; 2. Length not shorter than 1.5 mm; 3. Length not longer than 6 mm; 4. Additional incision can be done at the opposite side on the same meridian

$P=0.000$ ,  $P=0.000$ ,  $P=0.000$  and  $P=0.000$ . The keratometric astigmatism of all patients decreased to less than 1.00 D postoperatively. According to the power of the preexisting corneal astigmatism and age of patients, the mean length of the incision was  $3.26\pm 0.81$  mm (range 2 to 5 mm).

### Control group

The 25 eyes of control group keratometric astigmatism postoperatively had no significant changes compared to preexisting keratometric astigmatism  $2.81\pm 0.59$  D. The average keratometric astigmatism postoperatively was  $2.72\pm 0.57$  D at 1 week,  $2.76\pm 0.45$  D at 1 month,  $2.67\pm 0.58$  D at 3 months and  $2.65\pm 0.58$  D at 6 months.

### Difference between control group and treatment group

There were significant difference between the postoperative keratometric astigmatism of the control group and treatment group (Table 2).

### Changes of keratometric astigmatism axis and complications

The change of keratometric astigmatism axis is given in Table 3.

The axial changes above showed that the treatment group had higher rate of more than  $10^\circ$  changes of astigmatism. Vector analysis of this change showed that there was no eye overcorrected more than 1.00 D. All the cases had no ocular per-

forations during surgery, and no wound grapes. Postoperation complications such as itching or mild pain for 1 or 2 weeks occurred in some patients.

### DISCUSSION

The refractive power difference between the crossing meridians of the corneal anterior surface contributes very importantly to the total ocular astigmatism, although the lens is another source of astigmatism. In aphakia, the cornea is the only source of astigmatism. The treatment of the preexisting astigmatism and surgically reduced astigmatism affect the quality of cataract surgery as one of refractive surgery. Many researchers have tried adjusting-suture, small incision, etc. in their efforts to achieve good optical correction for aphakia.

There are several approaches for reducing preexisting astigmatism during cataract surgery. Astigmatic keratotomy (AK) has been used to correct preexisting keratometric astigmatism during cataract surgery (Akura *et al.*, 2000). The AK incisions are placed less than 3.0 mm away from the center of the cornea, which increases the risk of inducing irregular astigmatism and postoperation glare. Torsional diplopia may be induced by meridional aniseikonia, which alters the spatial sense (Guyton, 1985). The results of AK may vary, and fluctuation in refraction may occur (Lindstrom and Lindquist, 1988).

Another incisional approach is the use of opposite clear corneal incisions (Lever and Dahan, 2000). In this technique, 2 standard cataract incisions are made 180 degrees apart along the steep meridian. Lever and Dahan (2000) reported that the mean astigmatism correction was 2.06 D for incisions ranging from 2.8 to 3.5 mm. However, the standard deviation for the mean astigmatism correction was not reported. Because the second incision enters the anterior chamber, this approach is more invasive than CRI.

Toric IOL implantation has recently become available as a mean of correcting preexisting astigmatism (Leyland *et al.*, 2001). This approach has the advantage of excellent optical quality, but

**Table 2** Difference in mean over time between control group and treatment group

		Control	Treatment	<i>P</i>
Keratometric astigmatism	Preoperative	$2.81\pm 0.59$	$2.77\pm 0.74$	0.311
	1 week	$2.72\pm 0.57$	$0.29\pm 0.17$	0.000
	1 month	$2.76\pm 0.45$	$0.41\pm 0.21$	0.000
	3 months	$2.67\pm 0.58$	$0.42\pm 0.14$	0.000
	6 months	$2.65\pm 0.58$	$0.49\pm 0.13$	0.000

**Table 3** Axis changes of two groups

	Control group (n/%)	Treatment Group (n/%)
Less than $5^\circ$	21/84	16/64
$5^\circ$ to $10^\circ$	4/16	3/12
$10^\circ$ to $45^\circ$		2/8
$45^\circ$ to $90^\circ$		4/16

postoperative rotation of the toric IOL is a main concern. Leyland *et al.* (2001) reported that 18% of IOLs rotated more than 30 degrees. Sun *et al.* (2000) reported that 7% of IOLs rotated more than 40 degrees. Modifications of toric IOL designs are needed to address this problem. An additional drawback to the use of toric IOLs is that only 2.00 D and 3.50 D of cylindrical power are currently available, which correct 1.40 D and 2.30 D of astigmatism at the corneal plane respectively.

The most basic requirement is the placement of incision along the steep corneal meridian, to take advantage of the wound induced flattening (Lyhne *et al.*, 1998). In light of the disadvantages described, CRI seems to be an excellent alternative for reducing preexisting keratometric astigmatism during cataract surgery.

Our results demonstrated that CRI significantly decreased keratometric astigmatism in patients with preexisting astigmatism compared with astigmatic changes in the control group. The keratometric astigmatism of all patients decreased to less than 1.00 D postoperatively.

The main length and depth of incision have been the main factors manipulated in controlling the degree of astigmatic correction. There was no ocular perforation in our series, suggesting a good safety profile for using an RK diamond knife set at 95% depth of corneal thickness. And the incision length was decided according to a nomogram based on age and preoperative corneal astigmatism measured by keratometry.

Although no significant complications occurred in our patients, one must be aware of the potential complications such as placement of the incisions on the wrong or opposite meridian, infection, and loss of BSCVA. There is a risk of denervation of the cornea with long incisions. Cataract corneal incision and CRI that are too close to each other at the ends must be avoided. Further studies are needed to ascertain how long incisions cause this complication.

In our series, CRI was placed before the cataract surgery. An obvious advantage of performing incision before cataract surgery is that there might be greater variability in corneal thick-

ness from intraoperative corneal swelling. In addition, there might be more variability in the intraocular pressure, which could affect the depth of the incisions.

Advantages of CRI include technical ease, minimal instrument requirements, preservation of the optical qualities of the cornea, no complaint of postoperative glare and no apparent loss of vision, little or no postoperative discomfort, and infrequent overcorrections. Disadvantages include possible weakening of the integrity of the globe.

In conclusion, CRI is a practical, simple, safe and effective method to reduce preexisting astigmatism during cataract surgery. We believe that more effective results can be expected under the guidance of our improved nomogram. The long-term effect of CRI should be investigated.

## References

- Akura, J., Matsuura, K., Hatta, S., 2000. A new concept for the cataract correction of astigmatism: full-arc, depth-dependent astigmatic keratotomy. *Ophthalmology*, **107**:95-104.
- Gills, J.P., 1994. Cataract surgery with a single relaxing incision at the steep meridian. *J Cataract Refract Surg*, **20**:368-369.
- Guyton, D.L., 1985. Prescribing Cylinders Postoperatively. Year Book Ophthalmol. Year Book Medical Publishers, Chicago, p.63-66.
- Hoffer, K.J., 1980. Biometry of 7500 cataractous eyes. *Am J Ophthalmol*, **90**:360-368.
- Lever, J., Dahan, E., 2000. Opposite clear corneal incision to correct pre-existing astigmatism in cataract surgery. *J Cataract Refract Surg*, **26**:803-805.
- Leyland, M., Zinicola, E., Bloom, P., 2001. Prospective evaluation of a plate haptic toric intraocular lens. *Eye*, **15**:202-205.
- Lindstrom, R.L., Lindquist, T.D., 1988. Surgical correction of postoperative astigmatism. *Cornea*, **7**:138-148.
- Lyhne, N., Hansen, T.E., Corydon, L., 1998. Relationship between preoperative axis of astigmatism and postoperative astigmatic changes after superior scleral incision phacoemulsification. *J Cataract Refract Surg*, **24**:935-939.
- Muller-Jensen, K., Fischer, P., Slepe, U., 1999. Limbal relaxing incisions to correct stigmatism in clear corneal cataract surgery. *J Refract Surg*, **15**:586-589.
- Sun, X.Y., Vicary, D., Montgomery, P., 2000. Toric intraocular lenses for correcting astigmatism in 130 eyes. *Ophthalmology*, **107**:1776-1781.