Correspondence
https://doi.org/10.1631/jzus.B2300835

Waldenström macroglobulinemia: a challenging case treated with anti-CD19 CAR-T cell therapy

Yang YANG[1*], Xiaolin GU[1,2*], Jingsong HE[1], Yongxian HU[1], Zhen CAI[1]✉

[1]*Bone Marrow Transplantation Center, Department of Hematology, The First Affiliated Hospital, School of Medicine, Zhejiang University, Hangzhou 310006, Zhejiang, China*
[2]*Department of Hematology, Putuo People's Hospital, Zhoushan 316100, Zhejiang, China*

Key words: Waldenström macroglobulinemia; Chimeric antigen receptor T cell therapy, relapsed and refractory

Waldenström macroglobulinemia (WM) is characterized by lymphoplasmacytic lymphoma associated with large amounts of monoclonal immunoglobulin M (IgM) protein (Owen et al., 2003). Common signs and symptoms include fatigue due to anemia, lymph node enlargement, hepatosplenomegaly, thrombocytopenia, symptoms related to high viscosity, and peripheral neuropathy, among others. Despite significant advances in WM treatment, this type of indolent lymphoma remains incurable, with a wide array of patient outcomes (Ruan et al., 2020). In recent years, chimeric antigen receptor T cell (CAR-T) therapy targeting CD19 has shown unprecedented response rates and durability in the treatment of B-cell malignancies. In this report, we describe a challenging case of WM that involved multiple extramedullary sites, relapsed and was refractory to chemotherapy, immunotherapy, and targeted therapy. After anti-CD19 CAR-T cell therapy, the tumor burden significantly decreased and the patient's condition remained stable at the writing of this report.

In August 2018, a 66-year-old female presented with headache and fever and was diagnosed with cryptococcal meningitis. Anemia was noted, but no further workup was performed. In December 2019, the patient developed generalized pruritus, followed by dizziness, fatigue and low-grade fever. Laboratory tests revealed severe normocytic anemia (Hb 5.9 g/dL), elevated globulin (52.5 g/L) and IgM (4784 mg/dL) levels, and increased serum levels of β-2 microglobulin and lactic dehydrogenase, as well as lymphadenopathy. Immunohistochemical studies of lymph node biopsy showed monoclonal B-cells with the expression of CD20, CD19, kappa light chain restriction, and negative staining for CD5, CD10 and CD23. Bone marrow biopsy revealed 80% diffuse infiltration of small lymphocytic cells with $MYD88^{L265P}$ mutation, consistent with lymph node biopsy. Fluorodeoxyglucose (FDG)-positron emission tomography (PET) / computed tomography scan (CT) detected enlarged lymph nodes and increased FDG uptake in the paravertebral soft tissue (standardized uptake value, SUV 3.5). The patient was diagnosed with WM, and the revised International Prognostic Staging System (rIPSS) score was 4 (very high risk) (Kastritis et al., 2019). The patient received four cycles of chemoradiotherapy with rituximab, cyclophosphamide, and dexamethasone (RCD). Subsequently, blood tests showed

unedited

✉ Zhen CAI, caiz@zju.edu.cn
*The two authors contributed equally to this work
Zhen CAI, https://orcid.org/0000-0001-6026-3804
Yang YANG, https://orcid.org/0000-0001-5171-6226
Xiaolin GU, https://orcid.org/0009-0009-3600-3784

Received Nov. 16, 2023; Revision accepted Jan. 5, 2024;
Crosschecked xxx. xx, 20xx; Published online xxx. xx, 20xx

© Zhejiang University Press 2024

that Hb increased to 7.8 g/dL and IgM decreased to 2864 mg/dL. However, the patient developed multiple body rashes and back pain. MRI suggested infiltration of lymphoma in the vertebrae and surrounding tissues. L5 vertebral body biopsy revealed an increase in small B lymphocytes. Since the patient's condition continued to deteriorate, she was enrolled in a single-arm, multicenter, phase IV clinical trial and began taking ibrutinib. Three months later, she developed dyspnea and bloody pleural effusion. Flow cytometry of the pleural fluid showed abnormal B lymphocytes. The patient then received two cycles of rituximab and ibrutinib (IR) treatment; however, the pleural effusion did not improve, therefore, the patient received six cycles of bendamustine and rituximab (BR) treatment. The pleural effusion gradually subsided, resulting in a partial response. Five months after therapy, a follow-up examination showed Hb levels of 11.6 g/dL and IgM levels of 987 mg/dL, but a new lump was found on the right chest, accompanied by multiple pleural-based masses detected by CT, indicating disease progression. Biopsy of the lump confirmed lymphoplasmacytic lymphoma with MYD88 L265P and frameshift mutation in CXCR4MUT by next-generation sequencing (NGS). The patient then underwent one cycle of R-CHOP regimen (rituximab, cyclophosphamide, liposomal doxorubicin, vincristine and dexamethasone) chemotherapy; however, the soft tissue lump on the right chest wall was enlarged. PET visualized multiple irregular soft masses in the right chest wall with multiple generalized lymphadenopathies, hepatosplenomegaly, involvement of the right gluteus maximus muscle and left iliac muscle (SUV max = 6.3) (Fig. 1a). The patient was subsequently enrolled in a clinical study (NCT 04532281) evaluating the safety and efficacy of anti-CD19 CAR-T therapy in relapsed/refractory B-cell hematological malignancies. Chemotherapy was administered with fludarabine and cyclophosphamide (FC) regimen followed by infusion of second-generation CD19-directed CAR-T cells (2×106/kg) in July, 2022. These CAR-T cells containing 4-1BB co-stimulatory and CD3z signaling domains were manufactured by Shanghai YaKe Biotechnology Company. Following CAR19 T-cell infusion, the patient experienced a low-grade fever from day 3 to day 8. Additionally, she developed grade 4 leukocytopenia (CTCAE version 5). To manage the grade 1 cytokine release syndrome (CRS), the patient received tocilizumab treatment. Importantly, no neurological toxicity or secondary infections could be observed. A PET/CT scan 3 months after treatment revealed very good partial response (VGPR) according to IWWM-11 response criteria (Treon et al., 2023), especially due to the disappearance of the chest wall extramedullary mass, with IgM decreased to 219 mg/dL and Hb increased to 12.8g/dL. She remained in VGPR at the 12-month follow-up.

unedited

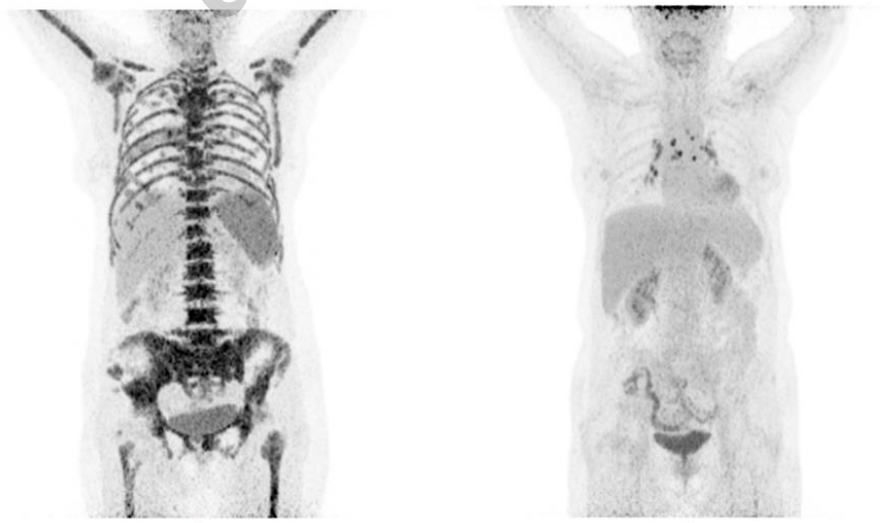

Figure 1. Comparison of FDG PET/CT before and after CAR-T treatment.
A. PET image prior to CAR-T cell therapy. Multiple foci of hypermetabolism could be observed throughout the body. B. FDG-PET image 3 months after CAR-T cell therapy. The foci of hypermetabolism were significantly reduced in number and intensity.

WM is considered an incurable disease, in which treatment decisions should take into account various factors, such as patient comorbidities, treatment goals, and risks of immunosuppression. First-line treatment options for symptomatic WM patients include CD20 monoclonal antibody combined with alkylating agents or proteasome inhibitors, and BTK inhibitors. These regimens can also be used for the management of relapsed or refractory (R/R) patients. Drugs targeting MYD88, CXCR4 and CAR-T cell therapy have shown potential for R/R patients (Castillo et al., 2020, 2022; Gertz, 2023; Thompson and Tam, 2023).

The initial treatment chosen for this patient was the RCD regimen, which is a commonly used chemotherapeutic immunotherapy for WM patients. Comparative research on the efficacy of initial treatments in WM has been limited. Retrospective studies suggest that the BR regimen may have better efficacy than RCD regimens, while RCD has relatively lower toxicity and can control cell reduction and gastrointestinal symptoms, making it a reasonable treatment option for this patient (Abeykoon et al., 2021). Nevertheless, the patient's condition progressed with the appearance of multiple extramedullary lesions.

While ibrutinib-containing regimens are ideal for R/R WM, they may not be as effective for patients with bulky extramedullary disease, malignant pleural effusions, or severe bone marrow involvement (Treon, 2015). The examination of the chest wall mass in this patient indicated CXCR4WHIM in addition to MYD88 L265P, which may have affected the efficacy of ibrutinib. Thus, treatment was adjusted to BR, which resulted in a significant improvement, with the pleural effusion subsiding.

When the chest wall mass continued to enlarge after RCHOP therapy, an unconventional treatment approach was urgently needed to address the refractory extramedullary lesion. At this point, the possibility of ASCT was considered. However, HSCT has limited data on its effectiveness in WM patients, especially for those with chemotherapy-refractory disease (Kyriakou, 2018).

The implementation of new therapies and participation in clinical trials are crucial to improving the prognosis of WM patients. In recent years, for example, CAR-T cell therapy has shown significant effectiveness against resistant B-cell malignant tumors, particularly in large B-cell lymphoma and transformed follicular lymphoma (Locke et al., 2019). Notwithstanding, the application of CAR-T therapy in WM has not been systematically evaluated. In one study, CD19-targeted CAR-T cell therapy could effectively target WM cells and led to responses in three patients with repeatedly relapsed and refractory disease, including complete remission, partial remission and stable disease. In Palomba et al.'s (2022) study, although disease recurrence occurred between 3 and 26 months after initial treatment, it was still demonstrated that CD19-targeted CAR-T cell therapy was effective in R/R WM patients. Successful CAR-T cell therapy was also reported in a patient with a transformed WM. The patient had poor responses to various chemotherapy regimens, and the disease progressed even after autologous stem cell transplantation. However, CAR-T cell therapy targeting CD19 resulted in complete remission, which was maintained during the one-year follow-up period (Bansal et al., 2020). Furthermore, in a phase 1/2 clinical trial, CD20-targeted CAR-T cell therapy achieved a 100% overall response rate and complete remission in two WM patients (Shadman, 2022). The reported cases are presented in Table 1.

The patient in our case tolerated the CAR-T cell therapy well with no significant cytokine release syndrome or neurotoxicity events. She has been followed up for over a year and her disease remains in very good partial remission, indicating the potential of CAR-T cell therapy as an alternative for R/R WM. Larger-scale clinical studies are eagerly apticipated to evaluate the efficacy and safety of this therapy.

Table 1 Cases of WM treated with CAR-T treatment

Target	Age	Genotype	Prior lines of therapy	Best response	PFS	OS	Reference
CD19	73	MYD88 p.L265P CXCR4 p.S342fs TP53 p.R175H/R196Q	7	SD	6.8	12.4	Palomba et al. 2022

Unedited

CD19	75	MYD88 p.L265P Loss of MYB and ATM	6	PR	4	4	Palomba et al. 2022
CD19	64	MYD88 p.L265P DNMT3A p.R823K	5	VGPR	26.5	Not reached	Palomba et al. 2022
CD19	71	MYD88 p.L265P	5	CR	12	Not reached	Bansal et al. 2020
CD20	NA	NA	NA	CR	NA	NA	Shadman et al. 2022
CD20	NA	NA	NA	CR	NA	NA	Shadman et al. 2022
CD19	66	MYD88 p.L265P CXCR4 p.S345fs	5	VGPR	Not reached	Not reached	Current report

Acknowledgements

This work is supported by Zhejiang Key Research and Development Project (2020C03014). We thank Dr. Xiaoping Sun from the University of Texas MD Anderson Cancer Center, Houston, TX, USA for editing.

Authors' contributions

YY and GXL structured and wrote the manuscript. HJS collected the clinical sample. HYX and CZ reviewed the manuscript. Yang Yang and Xiaolin Gu have contributed equally to this work. All authors read and approved the final manuscript and, therefore, had full access to all the data in the study and take responsibility for the integrity and security of the data.

Compliance with ethics guidelines

Yang Yang, Xiaolin Gu , Jingsong He , Yongxian Hu ,and Zhen Cai declare that they have no conflict of interest.

Our study was approved by the Clinical Research Ethics Committee of the First Affiliated Hospital, College of Medicine, Zhejiang University.All procedures followed were in accordance with the ethical standards of the responsible committee on humanexperimentation (institutional and national) and with the Helsinki Declaration of 1975, as revised in 2008 (5). Informed consent was obtained from the patient for being included in the study.

unedited

References

Abeykoon JP, Zanwar S, Ansell SM, et al., 2021. Assessment of fixed-duration therapies for treatment-naïve Waldenström macroglobulinemia. *Am J Hematol*, 96(8):945-953.
https://doi.org/10.1002/ajh.26210

Bansal R, Jurcic JG, Sawas A, et al., 2020. Chimeric antigen receptor T cells for treatment of transformed Waldenström macroglobulinemia. *Leuk Lymphoma*, 61(2):465-468.
https://doi.org/10.1080/10428194.2019.1665668

Castillo JJ, Allan JN, Siddiqi T, et al., 2022. Venetoclax in Previously Treated Waldenström Macroglobulinemia. *J Clin Oncol*, 40(1):63-71.
https://doi.org/10.1200/JCO.21.01194

Castillo JJ, Meid K, Flynn CA, et al., 2020. Ixazomib, dexamethasone, and rituximab in treatment-naive patients with Waldenström macroglobulinemia: long-term follow-up. *Blood Adv*, 4(16):3952-3959.
https://doi.org/10.1182/bloodadvances.2020001963

Gertz MA, 2023. Waldenström macroglobulinemia: 2023 update on diagnosis, risk stratification, and management. *Am J Hematol*, 98(2):348-358.
https://doi.org/10.1002/ajh.26796

Kastritis E, Morel P, Duhamel A, et al., 2019. A revised international prognostic score system for Waldenström's macroglobulinemia. *Leukemia*, 33(11):2654-2661.
https://doi.org/10.1038/s41375-019-0431-y

Kyriakou C, 2018. High-Dose Therapy and Hematopoietic Stem Cell Transplantation in Waldenström Macroglobulinemia. *He-*

matol Oncol Clin North Am, 32(5):865-874.
https://doi.org/10.1016/j.hoc.2018.05.013

Locke FL, Ghobadi A, Jacobson CA, et al., 2019. Long-term safety and activity of axicabtagene ciloleucel in refractory large B-cell lymphoma (ZUMA-1): a single-arm, multicentre, phase 1-2 trial. *Lancet Oncol*, 20(1):31-42.
https://doi.org/10.1016/S1470-2045(18)30864-7

Owen RG, Treon SP, Al-Katib A, et al., 2003. Clinicopathological definition of Waldenstrom's macroglobulinemia: consensus panel recommendations from the Second International Workshop on Waldenstrom's Macroglobulinemia. *Semin Oncol*, 30(2):110-115.
https://doi.org/10.1053/sonc.2003.50082

Palomba ML, Qualls D, Monette S, et al., 2022. CD19-directed chimeric antigen receptor T cell therapy in Waldenström macroglobulinemia: a preclinical model and initial clinical experience. *J Immunother Cancer*, 10(2).
https://doi.org/10.1136/jitc-2021-004128

Ruan G, Zanwar S, Abeykoon JP, et al., 2020. Predictors of short-term survival in Waldenström Macroglobulinemia. *Leuk Lymphoma*, 61(12):2975-2979.
https://doi.org/10.1080/10428194.2020.1789625

Shadman M, 2022. Shadman M. CD20 CAR-T therapy for WM and other B-NHLs. Presented at: IWWM-11, October 29, 2022, Madrid, Spain .

Thompson PA, Tam CS, 2023. Pirtobrutinib: a new hope for patients with BTK inhibitor-refractory lymphoproliferative disorders. *Blood*, 141(26):3137-3142.
https://doi.org/10.1182/blood.2023020240

Treon SP, 2015. How I treat Waldenström macroglobulinemia. *Blood*, 126(6):721-732.
https://doi.org/10.1182/blood-2015-01-553974

Treon SP, Tedeschi A, San-Miguel J, et al., 2023. Report of consensus Panel 4 from the 11th International Workshop on Waldenstrom's macroglobulinemia on diagnostic and response criteria. *Semin Hematol*, 60(2):97-106.
https://doi.org/10.1053/j.seminhematol.2023.03.009

unedited